

Case Report

*Corresponding author

Vivek Mehta, MDS

Assistant Professor
Department of Pediatric and
Preventive Dentistry
Faculty of Dentistry
Jamia Millia Islamia
New Delhi 110025, India

E-mail: drvivekmehta1@gmail.com

Article History

Accepted: June 28th, 2025

Published: July 1st, 2025

Citation

Mehta V. A Rare Case Report and a Synopsis of the Literature on Bilateral Fusion in Mandibular Primary Anterior Teeth. *Dent Open J.* 2025; 12(1): 10-12.

Copyright

©2025 Mehta V. This is an open access article distributed under the Creative Commons Attribution 4.0 International License (CC BY 4.0), which permits unrestricted use, distribution, and reproduction in any medium, provided the original work is properly cited.

A Rare Case Report and a Synopsis of the Literature on Bilateral Fusion in Mandibular Primary Anterior Teeth

Vivek Mehta, MDS*

Department of Pediatric and Preventive Dentistry, Faculty of Dentistry, Jamia Millia Islamia, New Delhi 110025, India

ABSTRACT

Fusion is a developmental anomaly of teeth. It is defined as the dentinal union of two embryologically developing teeth. It is more commonly seen in primary dentition and more frequently in incisor region. This paper reports a rare case which had the presence of bilaterally fused primary central incisor and lateral incisor in the mandibular region.

KEY WORDS: Fusion; Developmental anomaly; Primary incisors.

INTRODUCTION

Fusion is defined as the dentinal union of two embryologically developing teeth leading to one less tooth than normal in the affected arch. It is a dental twinning anomaly and has been described by many terms like double teeth, conjoined teeth, twinned teeth. Clinically, it may appear as normal sized or large, depending upon the stage at which embryological union occurs during development. It is commonly confused with gemination which is an incomplete attempt of one tooth bud to divide into two. Fused teeth are more commonly found in primary dentition as compared to permanent dentition. The occurrence is 0.5% in primary dentition, 0.1% in the permanent dentition and 0.02% for bilateral involvement in primary dentition.¹ It is more frequently seen in mandibular primary incisors.^{2,3} Males and females are equally affected. Genetics may be an important factor when there is an increased incidence.⁴ The presence of fused teeth can cause a lot of clinical problems like unacceptable appearance and periodontal conditions.⁵ A frequent finding in fusion of primary teeth is the congenital absence of corresponding permanent teeth. A multidisciplinary approach may be indicated in the clinical management of problems associated with fused teeth.⁶

CASE REPORT

A 4-year-old boy reported to the Department of Pediatric and Preventive Dentistry, Jamia Millia Islamia, New Delhi, India with the chief complaint of decayed tooth in the lower arch. The family and medical history of the child patient were insignificant. Thorough intraoral examination revealed a primary dentition with carious involvement of mandibular right primary second molar.

The mandibular arch also revealed an asymmetry in the tooth number. There were four teeth each present on the left and right side. There was bilateral presence of enlarged bifid crowns i.e., 71 and 72, and 81 and 82 and deep labio-lingual groove in relation to 81 and 82 (Figures 1 and 3). Intraoral periapical radiograph revealed that the enlarged bifid crowns were due to fused 71 and 72 (mandibular left primary central incisor and primary lateral incisor), and fused 81 and 82 (mandibular right primary central incisor and primary lateral incisor). The affected teeth i.e., 71 and 72 showed complete fusion of crown and roots resulting in joined pulp canal through pulp chambers, whereas 81 and 82 exhibited complete union of pulp chambers but incomplete union of pulp canals (Figure 2). OPG confirmed the presence of bilaterally fused

Figure 1: Clinical Image Showing Bilateral Fusion of Primary Mandibular Central Incisor and Lateral Incisor.

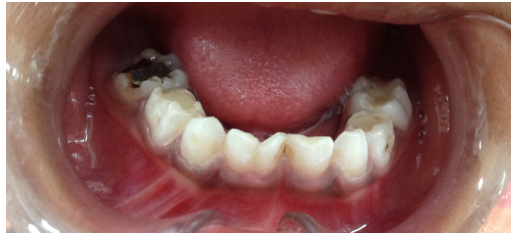

Figure 2: Intraoral Periapical Radiograph Showing Complete Fusion of 71-72 and Incomplete Fusion of 81-82.

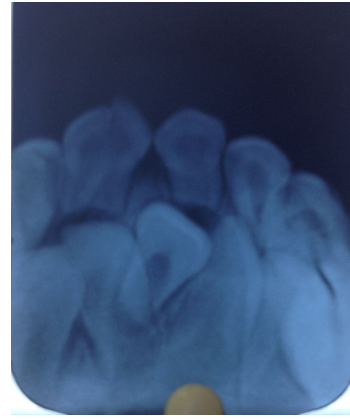


Figure 3: Clinical Image Showing Occlusal View of Bilateral Fusion of Primary Mandibular Incisors after Restoration of 85.

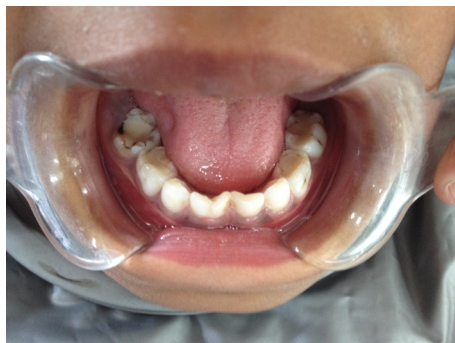
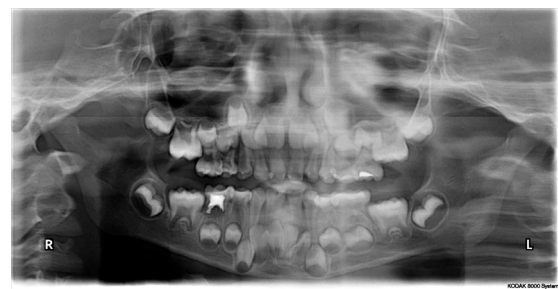
Figure 4: OPG Showing Bilaterally Fused Mandibular Incisors.



primary mandibular incisors and the presence of permanent successor teeth (Figure 4).

The primary mandibular lateral incisors were missing, thereby confirming that it was a case of fusion. The parents of the child patient gave no history of trauma, dental anomalies and consanguineous marriage. A thorough general examination was carried out to rule out the presence of any associated syndrome.

DISCUSSION

Fused teeth arise through union of two normally separated tooth germs and they can be found in almost any region of the dental arch, both in primary and permanent dentitions. According to the most accepted theory, some physical force or pressure is responsible for contact between developing teeth and their subsequent fusion.⁷ Genetic predisposition and racial differences are other predisposing factors. Fusion can be classified into complete and incomplete types. In case of complete fusion the union begins before calcification and crown of the fused tooth incorporates features of both teeth, but in incomplete fusion union of teeth occur at a much later stage and tooth might exhibit separate crown and fusion may be limited to roots with pulp canals fused or sep-

arate.⁸ Fusion may affect two normal teeth or it may also occur between a normal tooth and a supernumerary tooth which may be a mesiodens or a distomolar.^{7,9} Although, case of bilaterally fused mandibular lateral incisors and canines in the primary dentition have been reported in the literature, but interesting finding of bilaterally fused central and lateral incisors in the mandibular region makes the present case more extraordinary and worthy to report. Most of the fused teeth are associated with occlusal disturbances, space problems and delayed eruption of the permanent successors. The fissure present at the union between fused teeth predisposes it to dental caries and in some cases periodontal disease.⁹ Fused primary teeth may result in delayed resorption of roots due to its big root mass thereby leading to ectopic resorption of the permanent teeth.¹⁰ The presence of fused teeth in primary dentition has been associated with absence of permanent dentition and the prevalence depends on the combination of fused primary teeth.¹¹ Cases of fusion of primary mandibular anterior teeth associated with partial anodontia of both primary and permanent dentition¹² or with anodontia of permanent dentition alone have also been reported.¹³ The presence of fused teeth can also cause aesthetic problems, especially in the anterior region.

The treatment of fused teeth depends on the clinical sit-

uation, patient's expectations and degree of compliance.¹⁴ Proper instructions regarding maintenance of oral hygiene should be given to the patient to avoid caries. Fissure sealants can be used as they reduce the risk of caries. A multidisciplinary approach can also be used to ensure functional occlusion and aesthetics.

In the present case restoration of 85 was done with glass ionomer cement and fused primary teeth were retained as such as they were free from caries (Figure 3). Preventive approach was planned that included application of topical fluoride, oral hygiene instructions and periodic follow-ups.

Why this Paper is Important to Pediatric Dentists

- A thorough clinical and radiographic evaluation is compulsory as early diagnosis results in enhanced prognosis.
- Early detection and intervention of fused teeth is essential part of preventive dentistry as it is one of the rare anomalies of shape of tooth.
- Hypodontia of permanent dentition is a complication associated with fused primary teeth and the prevalence depends on the combination of fused teeth.
- Fusion of primary teeth may be associated with pulp exposure due to presence of deep grooves.
- Careful monitoring is required in most of the cases as regular and long-term follow-up is required to manage fusion.

SOURCES OF SUPPORT: None.

PATIENT'S CONSENT

Written informed consent was obtained from the patient for publication of this case report.

REFERENCES

1. Neville BW, Damm DD, Allen CM, Bouquot JE. Abnormalities of teeth. In: *Oral and Maxillofacial Pathology*. 2nd ed. Amsterdam, Netherlands: Elsevier; 2005: 49-106.
2. Grahanen H, Granath L. Numerical variations and their correlations with the permanent dentition. *Odont Rev*. 1961; 4: 348-357.
3. Ravn JJ. Aplasia, supernumerary teeth and fused teeth in the primary dentition. An epidemiological study. *Scand J Dent Res*. 1971; 79: 1-6. doi: [10.1111/j.1600-0722.1971.tb01986.x](https://doi.org/10.1111/j.1600-0722.1971.tb01986.x)
4. Hagman FT. Anomalies of form and number, fused primary teeth, a correlation of the dentitions. *J Dent Child*. 1988; 55(5): 359-361.
5. Mader CL. Fusion of teeth. *J Am Dent Assoc*. 1979; 98(1): 62-64. doi: [10.14219/jada.archive.1979.0037](https://doi.org/10.14219/jada.archive.1979.0037)
6. Delany GM, Goldblatt LI. Fused teeth: A multidisciplinary approach to treatment. *J Am Dent Assoc*. 1981; 103(5): 732-734. doi: [10.14219/jada.archive.1981.0396](https://doi.org/10.14219/jada.archive.1981.0396)
7. Rajendran R. Developmental disturbances of oral and para-oral structures. In: Rajendran R, Sivapathasundharam B, eds. *Shafers Textbook of Oral Pathology*. 6th ed. New Delhi, India: Elsevier; 2011: 39-40.
8. Chachra S, Sharma AK. Bilateral fusion of the mandibular primary incisor: A case report. *J Indian Dent Assoc*. 2011; 5: 248-249.
9. Nunes E, de Moraes IG, de Oliveira Novaes PM, de Sousa SMG. Bilateral fusion of mandibular second molars with supernumerary teeth: Case report. *Braz Dent J*. 2002; 13: 137-141. doi: [10.1590/S0103-64402002000200012](https://doi.org/10.1590/S0103-64402002000200012)
10. Rajashekhara BS, Dave B, Manjunatha BS, Panache KS. Bilateral fusion of primary mandibular lateral incisors and canines. A report of a rare case. *Rev Odonto Science*. 2010; 25(4): 427-429. doi: [10.1590/S1980-65232010000400020](https://doi.org/10.1590/S1980-65232010000400020)
11. Tsujino K, Yoneju T, Shintani S. Effects of different combinations of fused primary teeth on eruption of permanent successors. *Pediatr Dent*. 2013; 35(2): E64-E67.
12. Mehta V. Fusion of primary mandibular anterior teeth associated with partial anodontia of primary and permanent dentition: A Case Report. *J Dent Health Oral Disord Ther*. 2015;3(3), 00090. doi: [10.15406/jdhodt.2015.03.00090](https://doi.org/10.15406/jdhodt.2015.03.00090)
13. Mehta V. Fusion of primary mandibular teeth associated with partial anodontia of permanent dentition: A case report. *Int J Oral Max Pathology*. 2015; 6(1): 23-25.
14. Sekerci A, Sisman Y, Ekizer A, Sahman H, Gumus H, Aydinbelge M. Prevalence of double (Fused-Geminated) primary teeth in Turkey: A study. *Pak Oral Dent J*. 2011; 31: 7-13. Web site. <http://search.proquest.com/openview/80833cd02c5430e2093c53a0b1a1d1f5/1?pq-origsite=gscholar&cbl=616533>. Accessed April 21, 2017.