

## Case Report

# The Effects of Ultra-Early Cord Decompression on Results in an Emergency Situation

Ali Ahmadvand, MD<sup>1</sup>; Mohammad J. Behzadnia, MD<sup>1,2</sup>; Amin Jahanbakhshi, MD<sup>3</sup>; Mohammad R. Zarei, MD, MPH<sup>4\*</sup>

<sup>1</sup>Trauma Research Center, Baqiyatallah University of Medical Sciences, Tehran, Iran

<sup>2</sup>Faculty of Medicine, Azad University of Medical Sciences, Tehran, Iran

<sup>3</sup>Department of Neurosurgery, Skull Base Research Center, Iran University of Medical Sciences, Tehran, Iran

<sup>4</sup>Department of Emergency Medicine, Sina Trauma and Surgery Research Center, Tehran University of Medical Sciences, Tehran, Iran

\*Corresponding author

Mohammad R. Zarei, MD, MPH

Sina Trauma and Surgery Research Center, Tehran University of Medical Sciences, Tehran, Iran. Tel.: +98-2166757001; E-mail: [dr.mrzarei@gmail.com](mailto:dr.mrzarei@gmail.com)

### Article information

Accepted: April 26<sup>th</sup>, 2025; Published: May 2<sup>nd</sup>, 2025

### Cite this article

Ahmadvand A, Behzadnia MJ, Zarei MR. The Effects of Ultra-Early Cord Decompression on Results in an Emergency Situation. *Emerg Med Open J.* 2025; 11(1): 9-13.

## ABSTRACT

### Background

Traumatic cervical spine injuries are very common due to high motility of cervical spine and its vulnerability to traumatic injuries. Optimal time for stabilizing the patients with traumatic spinal fractures remains controversial. It is almost due to different outcomes in various studies and the lack of consensus about it. Here we explain an ultra-early cord decompression that led to complete recovery of a patient with severe cervical cord injury.

### Case Presentation

The patient was a 27-year-old gymnast woman with a recent history of spinal cord injury caused by high jumping with head back and neck hyperextension presented within 2-hours of trauma. As a critical case and lack of advanced radiologic equipment, only cervical spinal radiographs were used for decision-making within the first 3 hours of injury to save the patient's cord function by surgical decompression.

### Conclusion

Many studies have proposed different intervention times for achieving the optimal result; however, we present an ultra-early surgery (within 3-hours of injury), conducted in a context of limited medical facilities. This case revealed an excellent result after 12-months follow-up.

### Keywords

Cervical spine; Early decompression; Surgery; Trauma.

## INTRODUCTION

Traumatic cervical injuries occur in 2-3% of all traumatic patients and account for 8% of trauma-related deaths.<sup>1</sup> The incidence of spinal cord injury is about 30 person per million in the world.<sup>2</sup> Optimal time for stabilizing the patients with traumatic spinal fractures remains controversial. It is almost due to the lack of a consensus on different outcomes in various studies. Depending on the clinical situation, it is very important to make a timely and appropriate decision.<sup>3</sup> Many studies have discussed and explained different time durations as a deadline for achieving the optimal results. Some studies have assessed the frequency, timing and prediction of symptom development in patients with radiological evidence of cord compression or spinal canal narrowing. Some

of these studies have reached to a recommendation in favor of "early" or "very-early" surgery in acute setting.<sup>3,6</sup>

Very-early surgery is considered as surgery performed within 8-hours of trauma.<sup>4</sup> Here, we present a rare case of traumatic cervical spine injury that was operated within 3-hours of the injury in a setting with no magnetic resonance imaging (MRI) utility. The outcome of this so-called ultra-early surgery will be discussed.

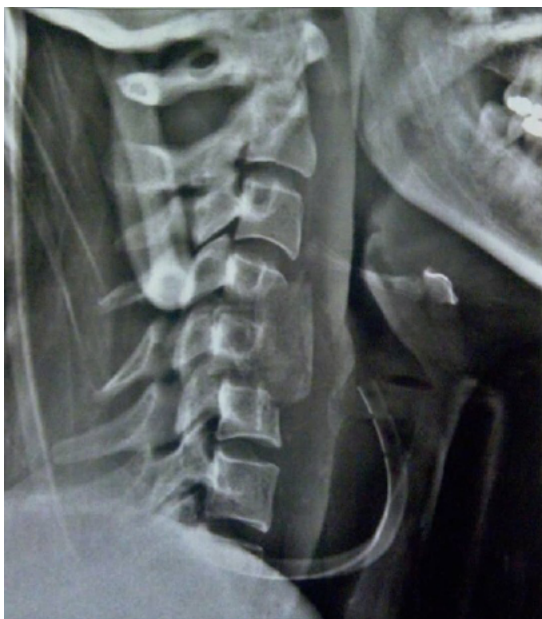## CASE PRESENTATION

A 27-year-old gymnast female arrived at the emergency department, suffering from neck pain and bilateral upper extremity numbness

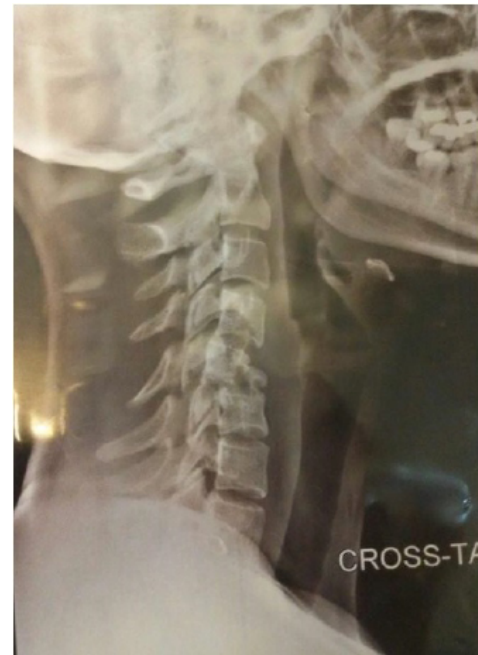and weakness after falling and neck hyperextension 2-hours before presentation. The neurological examination revealed the weakness of the upper extremities and reduced sensation bilaterally in the C3 to C7 dermatomes, and the patient felt hyperalgesia and numbness in peri-umbilical area. The motor strength of both upper extremities were 1/5 to 2/5. Her hands' strength in flexor muscles were 1/5 bilaterally. Besides the normal sensation, the motor strength of the lower extremities was 3/5. The deep tendon reflexes (DTR) of the both extremities were within the normal range. Rectal tone and bulbocavernosus reflex were also normal. According to the American Spinal Association (ASIA) score, the patient was categorized in grade C. Her initial examination suggested a central cord syndrome. She had no history of any systemic diseases such as diabetes, hypertension and no long-term use of any medication.

This patient had been admitted to a hospital with no computerized tomography (CT) scan or MRI facilities. Waiting for performing CT scan or MRI would make a significant delay in patient's treatment. Therefore, only cervical spinal radiographs were used for decision-making (Figure 1). She underwent a decompression surgery within the first 3-hours after trauma (Figure 2). Intravenous methylprednisolone was also administered with a dose of 500 mg in 10-minutes and 500 mg every 6-hours thereafter for 24-hours. Intravenous cefazolin was administered just before surgery for 24-hours every 6-hours. According to the American Spinal Injury Association modified Frankel classification, neurological functions were assessed before and after the surgery and during the follow-up.<sup>7</sup> The goal was to restore the maximal spinal stability, cord decompression and eventually to let the patient be mobilized as soon as possible in an ultra-early time within 3-hours of the trauma. A written informed consent has been obtained from the patient to let us present his medical information.

**Figure 1.** Lateral Cervical X-ray, 3-Hours after the Trauma Reveals a Fracture-Dislocation of the 5<sup>th</sup> Cervical Spine



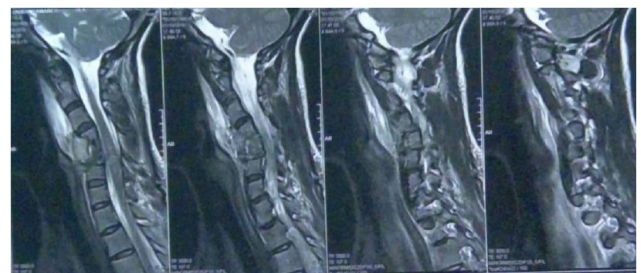**Figure 2.** Lateral Cervical X-ray, after First Operation, Corpectomy and Iliac Replacement Grafting, One-Day after Trauma



## SURGICAL METHOD

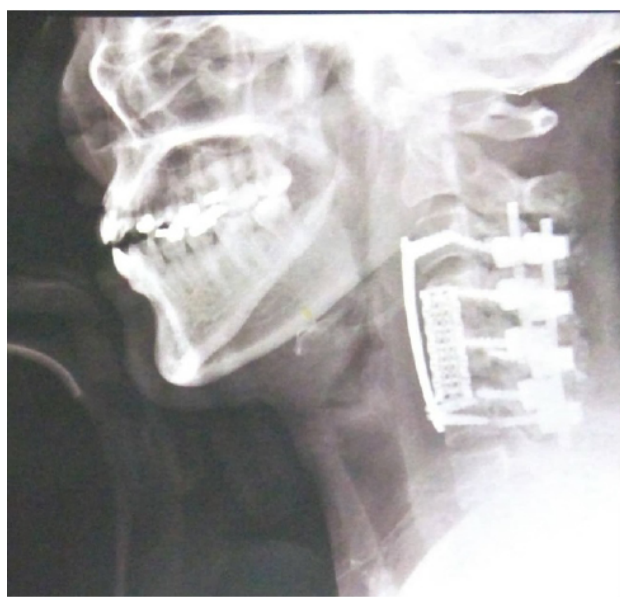
Under general anesthesia and supine position, a right-sided Smith – Robinsons approach through a 5 cm standard transverse incision was used. C4 and C5 partial corpectomy and stabilization of C3 to C6, were performed. An iliac crest graft was set on the corpectomy defect in the first stage. Later, the iliac crest graft was removed and titanium mesh filled with autologous bone graft and cervical plate (Medtronic spine, Minnesota, USA) was used for anterior fusion of C3 to C6. In the third stage, the patient was positioned prone in a Mayfield head holder. A midline 9 cm skin incision was made starting at the external occipital protuberance. The lateral masses of the C3-6 were subsequently exposed by subperiosteal dissection. Then, the lateral mass screws (Medtronic spine) was placed in C3-6 lateral masses, using Magerl technique (Figure 3).<sup>8</sup> Eventually, proper drainage was placed and a Philadelphia cervical collar was used to post-operative neck immobilization (8 to 12-weeks). The patient was discharged from the acute care when she was medical-

**Figure 3.** Lateral Cervical X-ray, Performed Post-operatively



y stable. Post-operative cervical radiography showed sufficient reduction and good positioning of the implants. Subsequently, post-surgical MRI of the cervical spine, performed in another medical center, confirmed the diagnosis. (Figure 4). Rehabilitation was started within 2-days postoperatively. Four-days later, the patient was reassessed neurologically; there were no significant differences in neurological status before and after the operation and she discharged home.

**Figure 4.** Cervical MRI, 2-Days after Trauma, Myelogram View Shows the Central Cord Injury



She was evaluated within every 3-months in outpatient clinic for one year. In her last follow-up, the motor strength had recovered completely. In her neurological examination, there was only a numbness around the peri-umbilical area. She returned to her ordinary life without any restrictions.

## DISCUSSION AND CONCLUSION

Theoretically, in case of ongoing pressure on spinal cord, early decompression would help in reestablishment of cord blood supply and prevent further ischemic injury. Moreover, by restoration of CSF circulation around the injured cord, noxious inflammatory substances may be washed out, and therefore it might have a role in preventing secondary injuries to the cord.<sup>3-6,9,10</sup>

Definition of early and late intervention is still unclear in various studies. Some authors like Frangen et al<sup>11</sup> believed that the importance of coexisting lung injuries in acute spinal trauma is an important factor influencing the clinical outcome, even in the early intervention and severely injured casualties. In another study, Kerwin et al<sup>12</sup> showed a marked correlation between postoperative complications (such as pneumonia) and time of admission in patients who underwent early ( $\leq 72$ -hours) surgical fixation. Interestingly, according to Injury Severity Score (ISS) early surgical

stabilization is more effective in patients with more severe injuries.<sup>13</sup> Dvorak et al<sup>14</sup> determined that early surgery within 24-hours of spinal injury will improve the motor neurological recovery and also reduces the duration of hospital stay. Similarly, in Dorban's et al<sup>15</sup> study, ultra-early surgery ( $\leq 12$ -hours) in patients with neurological defects had a better neurological outcome.

Interestingly some authors mentioned a significant longer waiting time in older patients ( $\geq 75$  y/o) from admission to surgery, despite less severe injuries. McKinly's study noted that the ASIA motor index was important in the nonsurgical group, especially in the patients with incomplete injuries and the elderly. However in that study, there was no difference in neurological or functional improvement between the early ( $\leq 24$ -hours) and the late ( $\geq 72$ -hours) groups.<sup>16</sup> In another investigation by Furlan et al, early decompression of spinal cord was more cost-effective than delayed intervention in both complete and incomplete injuries; however, it seems that further investigation is still required in the future to reach the best outcome.<sup>17</sup>

Although the best time for the early surgical intervention remains to be determined, most studies report the first 24-hours as a deadline for the best outcome. However, in some other studies, acute or early trauma stabilization time is defined as  $\leq 72$ -hours.<sup>3-5,13,17-20</sup>

Yue et al<sup>2</sup> in a review of 56 published studies in the field of acute cervical spine injuries showed an improved outcome in the early ( $\leq 24$ -hours) interventions. Bourassa-Moreau et al<sup>21</sup> reported that earlier surgical intervention will reduce complication rate such as pneumonias ( $\leq 72$ -hours) and pressure ulcer ( $\leq 24$ -hours).

Contrary to the vast agreement with early operation, many studies have demonstrated different results. Liu et al<sup>19</sup> showed no significant difference between two groups in the early and late surgical complications such as pneumonia, infection and sepsis. They also concluded that timing of surgery has no effect on neurological recovery and even early intervention may lead to a higher mortality and morbidity. They recommended the first 72-hours of the spinal injury as the best time of intervention. Biglari et al<sup>18</sup> study was one of the few studies that proposed the first 4-hours as an early intervention time, however the authors recommended against it as the early (4-hours) *vs* late (4-24-hours) decompression showed no significant difference in neurological outcome. However, there were important limitations to discuss, such as being a single center prospective study with a limited sample size (51 patients). Koniczny et al<sup>20</sup> also found that early ( $\leq 72$ -hours) surgery had a significantly higher mortality rate and recommended to select the patients more carefully for early decompression surgery.

Few authors believed that the patients with central cord syndrome (CCS) may have long-term neurological recovery, regardless of the treatment. As opposed to our case report, a prospective 12-months follow-up showed an impairment in ASIA motor score and neurological outcome in patients who were treated in the early stage of the injury (first 8-hours) in comparison

with the interventions during 8-24-hours after the injury.<sup>22</sup>

To the best of our knowledge, this is a very rare operation that was conducted in an ultra-early stage (3-hours) of the injury. Although it was conducted in a context of limited medical facilities, an excellent result at the 12-month follow-up ensued, raising awareness for the possible benefits of this approach.

## CONSENT

The authors have received written informed consent from the patient.

## CONFLICT OF INTEREST

The authors declare that they have no conflicts of interest.

## REFERENCES

- Shakya B, Bista P, Shrestha D. Instrumentation in cervical spine injury: neurological outcome measurement using ASIA impairment scale. *Nepal Med Coll J*. 2014; 16: 156-160.
- Yue JK, Upadhyayula PS, Chan AK, Winkler EA, Burke JF, Reddy WJ, et al. A review and update on the current and emerging clinical trials for the acute management of cervical spine and spinal cord injuries - Part III. *J Neurosurg Sci*. 2016; 60: 529-542.
- Badhiwala JH, Wilson JR, Witiw CD, Harrop JS, Vaccaro AR, Aarabi B, et al. The influence of timing of surgical decompression for acute spinal cord injury: A pooled analysis of individual patient data. *The Lancet Neurology*. 2020; 20(2): 117-126. doi: [10.1016/S1474-4422\(20\)30406-3](https://doi.org/10.1016/S1474-4422(20)30406-3)
- Sánchez JAS, Sharif S, Costa F, Rangel J, Anania CD, Zileli M. Early management of spinal cord injury: WFNS spine committee recommendations. *Neurospine*. 2020; 17: 759-784. doi: [10.14245/ns.2040366.183](https://doi.org/10.14245/ns.2040366.183)
- Maas AIR, Peul W, Thomé C. Surgical decompression in acute spinal cord injury: Earlier is better. *The Lancet Neurology*. 2020; 20(2): 84-86. doi: [10.1016/S1474-4422\(20\)30478-6](https://doi.org/10.1016/S1474-4422(20)30478-6)
- Jug M, Kejžar N, Cimerman M, Bajrović FF. Window of opportunity for surgical decompression in patients with acute traumatic cervical spinal cord injury. *J Neurosurg Spine*. 2019; 1-9. doi: [10.3171/2019.10.SPINE19888](https://doi.org/10.3171/2019.10.SPINE19888)
- Burns S, Biering-Sørensen F, Donovan W, et al. International standards for neurological classification of spinal cord injury, revised 2011. *Topics in Spinal Cord Injury Rehabilitation*. 2012; 18: 85-99.
- Xu R, Ebraheim NA, Klausner T, Yeasting RA. Modified Magerl technique of lateral mass screw placement in the lower cervical spine: an anatomic study. *J Spinal Disord*. 1998; 11: 237-240.
- Liu Z, Yang Y, He L, Pang M, Luo C, Liu B, et al. High-dose methylprednisolone for acute traumatic spinal cord injury: A meta-analysis. *Neurology*. 2019; 93: e841-e850. doi: [10.1212/WNL.0000000000007998](https://doi.org/10.1212/WNL.0000000000007998)
- Alizadeh A, Dyck SM, Karimi-Abdolrezaee S. Traumatic spinal cord injury: An overview of pathophysiology, models and acute injury mechanisms. *Front Neurol*. 2019; 10: 282. doi: [10.3389/fneur.2019.00282](https://doi.org/10.3389/fneur.2019.00282)
- Frangen TM, Ruppert S, Muhr G, Schinkel C. The beneficial effects of early stabilization of thoracic spine fractures depend on trauma severity. *J Trauma*. 2010; 68: 1208-1212. doi: [10.1097/TA.0b013e3181a0e558](https://doi.org/10.1097/TA.0b013e3181a0e558)
- Kerwin AJ, Frykberg ER, Schinco MA, Griffen MM, Murphy T, Tepas JJ. The effect of early spine fixation on non-neurologic outcome. *J Trauma*. 2005; 58: 15-21. doi: [10.1097/01.ta.0000154182.35386.7e](https://doi.org/10.1097/01.ta.0000154182.35386.7e)
- Carreon LY, Dimar JR. Early versus late stabilization of spine injuries: A systematic review. *Spine*. 2011; 36: E727-E733. doi: [10.1097/BRS.0b013e3181fab02f](https://doi.org/10.1097/BRS.0b013e3181fab02f)
- Dvorak MF, Noonan VK, Fallah N, Fisher CG, Finkelstein J, Kwon BK, et al. The influence of time from injury to surgery on motor recovery and length of hospital stay in acute traumatic spinal cord injury: An observational Canadian cohort study. *J Neurotrauma*. 2015; 32: 645-654. doi: [10.1089/neu.2014.3632](https://doi.org/10.1089/neu.2014.3632)
- Dobran M, Iacoangeli M, Nocchi N, Di Rienzo A, di Somma LGM, Nasi D, et al. Surgical treatment of cervical spine trauma: Our experience and results. *Asian J Neurosurg*. 2015; 10: 207-211. doi: [10.4103/1793-5482.161192](https://doi.org/10.4103/1793-5482.161192)
- McKinley W, Meade MA, Kirshblum S, Barnard B. Outcomes of early surgical management versus late or no surgical intervention after acute spinal cord injury. *Arch Phys Med Rehabil*. 2004; 85: 1818-1825. doi: [10.1016/j.apmr.2004.04.032](https://doi.org/10.1016/j.apmr.2004.04.032)
- Furlan JC, Craven BC, Massicotte EM, Fehlings MG. Early versus delayed surgical decompression of spinal cord after traumatic cervical spinal cord injury: A cost-utility analysis. *World Neurosurg*. 2016; 88: 166-174. doi: [10.1016/j.wneu.2015.12.072](https://doi.org/10.1016/j.wneu.2015.12.072)
- Biglari B, Child C, Yildirim TM, Swing T, Reitzel T, Moghadam A. Does surgical treatment within 4 hours after trauma have an influence on neurological remission in patients with acute spinal cord injury? *Theor Clin Risk Manag*. 2016; 12: 1339-1346. doi: [10.2147/TCRM.S108856](https://doi.org/10.2147/TCRM.S108856)
- Liu Y, Shi CG, Wang XW, Chen HJ, Wang C, Cao P, et al. Timing of surgical decompression for traumatic cervical spinal cord injury. *Int Orthop*. 2015; 39: 2457-2463. doi: [10.1007/s00264-014-2652-z](https://doi.org/10.1007/s00264-014-2652-z)
- Konieczny MR, Strüwer J, Jettkant B, Schinkel C, Källicke T, Muhr G, et al. Early versus late surgery of thoracic spine frac-

tures in multiple injured patients: Is early stabilization always recommendable? *Spine J.* 2015; 15: 1713-1718. doi: [10.1016/j.spinee.2013.07.469](https://doi.org/10.1016/j.spinee.2013.07.469)

21. Bourassa-Moreau É, Mac-Thiong JM, Li A, Feldman DE, Gagnon DH, Thompson C, et al. Do patients with complete spinal cord injury benefit from early surgical decompression? Analysis of neurological improvement in a prospective cohort study. *J Neurotrauma.* 2016; 33: 301-306. doi: [10.1089/neu.2015.3957](https://doi.org/10.1089/neu.2015.3957)

*rotrauma.* 2016; 33: 301-306. doi: [10.1089/neu.2015.3957](https://doi.org/10.1089/neu.2015.3957)

22. Jug M, Kejžar N, Vesel M, Al Mawed S, Dobravec M, Herman S, et al. Neurological recovery after traumatic cervical spinal cord injury is superior if surgical decompression and instrumented fusion are performed within 8 hours versus 8 to 24 hours after injury: A single center experience. *J Neurotrauma.* 2015; 32: 1385-1392. doi: [10.1089/neu.2014.3767](https://doi.org/10.1089/neu.2014.3767)