

## Review

### \*Corresponding author

**Brian C. Cooley, PhD**

Associate Professor  
Department of Pathology and  
Laboratory Medicine  
McAllister Heart Institute  
University of North Carolina  
MBRB 3341C  
111 Mason Farm Road  
Chapel Hill, NC 27599, USA  
Tel. 919-962-4912  
E-mail: [brian\\_cooley@med.unc.edu](mailto:brian_cooley@med.unc.edu)

Volume 2 : Issue 2

Article Ref. #: 1000HROJ2110

### Article History

Received: April 20<sup>th</sup>, 2015

Accepted: April 21<sup>st</sup>, 2015

Published: April 21<sup>st</sup>, 2015

### Citation

Cooley BC. Experimental vein graft research: a critical appraisal of models. *Heart Res Open J.* 2015; 2(2): 53-59. doi: [10.17140/HROJ-2-110](https://doi.org/10.17140/HROJ-2-110)

### Copyright

©2015 Cooley BC. This is an open access article distributed under the Creative Commons Attribution 4.0 International License (CC BY 4.0), which permits unrestricted use, distribution, and reproduction in any medium, provided the original work is properly cited.

# Experimental Vein Graft Research: A Critical Appraisal of Models

**Brian C. Cooley\***

Associate Professor, Department of Pathology and Laboratory Medicine, McAllister Heart Institute, University of North Carolina, Chapel Hill, MBRB 3341C, 111 Mason Farm Road, NC 27599, USA

## ABSTRACT

Experimental models of vein grafting need to have specific relevance to the clinical complications encountered in coronary artery bypass grafting: acute thrombosis, neointima-associated stenosis, and progression of late-forming atherosclerotic lesions. Despite extensive use, many of these experimental models lack endpoint measures with clear analogies to their clinical counterparts and may in fact target the wrong (patho) physiologic process. Model selection is critical to further progress toward preventing these all too prevalent complications used for heart revascularization.

**KEYWORDS:** Coronary artery bypass graft; Percutaneous coronary intervention; Anastomosis; Oligodesoxynucleotide; Neointima; Arterialization.

## INTRODUCTION

Interposition vein grafting is used to bypass arterial stenotic/occlusive sites caused primarily by atherosclerotic lesions and plaque rupture in the coronary arteries. The choice of whether to use a Coronary Artery Bypass Graft (CABG) or a Percutaneous Coronary Intervention (PCI) and stent placement is an ongoing debate, with advocacy for CABG under many conditions not appropriate for stent placement or internal mammary artery-based revascularization.<sup>1-4</sup> Despite the high acceptance and application of these bypass procedures, complications are a substantial problem, resulting in early and intermediate-term failures rates upwards of 25%.<sup>1,5,6</sup>

The types of complications encountered with vein grafts can be broken down into 3 categories, on the basis of causation and the approximate time of development.<sup>6</sup> Acute thrombosis can arise from vessel wall trauma after the vascular repairs and generally occurs intraoperatively or in the early postoperative interval in 5-10% of cases, though it may be encountered up to 1 month after graft placement. Graft stenosis can develop in the ensuing months, either caused by neointimal overgrowth or inward remodeling of the graft wall (~1-24 months) or by late-stage atherogenic lesion formation (2-10 years), with the former accounting for the largest proportion of complications.<sup>5,6</sup>

Most experimental studies into these complications have focused on neointimal development. There are a number of good reviews of animal models of vein grafting,<sup>7-9</sup> mostly focusing on studies of intermediate to late development of complications. There is a paucity of studies into thrombotic studies of acute vein graft failure. There is also confusion in terminology for intermediate-term and late-term vein graft disease, with all too frequent interchanging of terms for neointimal *versus* atherosclerotic lesions to describe the pathologic changes in these grafts. This paper will address some of these difficulties in the interpretation of published literature.

## ACUTE THROMBOSIS

The majority of studies into vein graft thrombosis come from the microvascular surgery literature, wherein the problems of repairing and reconstructing vessels smaller in diameter than the coronary artery have been considered. The clinical need for these grafts is the lack of vessel length during extremity replantation<sup>10</sup> or composite free tissue transfer (free flaps),<sup>11,12</sup> due to vascular damage/trauma and inability to juxtapose vessel ends without tension during efforts of direct anastomotic repair. These applications can be viewed in simplistic terms, the simple addition of a second anastomosis to the vessel repair site, essentially doubling the thrombotic risk for occlusion. Because of the relative success in applying vein grafts under these conditions, and the lack of later-term failures, experienced reconstructive microsurgeons have felt that vein grafts can be applied safely and with little further risk of thrombotic failure in these cases.<sup>13</sup>

Experimental studies into vein graft thrombosis have focused primarily on three modulating influences: the diameter of the graft, the use of antithrombotic therapies, and preservation of vein graft integrity and endothelium. The majority of these experimental studies have used rabbit or rat models, harvesting grafts from the external Jugular Vein (JV), Femoral Vein (FV), or superficial inferior Epigastric Vein (EV), and grafting into the carotid or femoral artery. Thrombotic rates are relatively low in these models (under 15%), and are reduced with experience and higher levels of competence, making it difficult to discern differences in thrombotic failure rates without very large animal numbers. The studies of vein graft diameter may also be unique to the reconstructive surgical field, where arterial diameters can vary greatly (from pediatric digital replants to large-adult forearm replants)<sup>12,13</sup> and the choice of vein graft donor is wider (e.g., use of dorsalis pedis veins).<sup>13</sup> The standard CABG graft uses the saphenous vein, grafted in end-to-side fashion, which can be surgically modulated to any size which to a large extent obviates the issue of vessel diameter at the anastomosis.

Unfractionated heparin remains the primary antithrombotic agent in the peri-operative period, primarily because of its anticoagulant use during cardiopulmonary bypass and because of its reversibility with protamine. This dominant use of heparin has to some extent impeded the efforts to develop other antithrombotic agents for CABG, though several direct thrombin inhibitors are currently under investigation and in use for patients who develop Heparin-induced thrombocytopenia (HIT).<sup>14,15</sup> Platelet inhibitors have also received some study,<sup>16,17</sup> but their current use is principally directed to that of preventing further cardiovascular sequelae.<sup>18</sup>

## GRAFT EC INTEGRITY

Many vascular surgeons advocate a “no touch” technique<sup>19,21</sup> for vein graft harvest, in an effort to minimize vein graft iatrogenic injury. The goal is to preserve endothelial and smooth muscle cell presence and function in the graft, with a pre-

sumed outcome of reduced maladaptive neointimal overgrowth, though early prevention of thrombosis is also a rationale. Endothelial preservation will maintain nitric oxide and prostacyclin generation,<sup>21</sup> critical factors for sustaining function, patency, and vascular integrity. The effect of no-touch graft harvesting on subsequent bypass surgery outcome is difficult to evaluate, given that it represents differences in personal surgical technique and that endothelial cells cannot be directly seen or tracked following clinical graft placement. This issue is further complicated by recent advocacy of endoscopic graft harvesting approaches<sup>22-24</sup> that are primarily designed to minimize donor-site morbidity and infection and for which damage from harvesting is more difficult to control. Very few experimental studies have directly assessed endothelial preservation after vein grafting. Ehsan and colleagues<sup>25</sup> showed that under endothelial-preserving conditions, rabbit JV grafts maintain endothelial cells that undergo a burst of proliferation in the first 3 days post-grafting. The author used a murine vein graft model with marker-gene-expressing endothelial cells in the grafts which were transplanted into wild-types, demonstrating preservation of the endothelium out to 30 days.<sup>26</sup> Thus, a gentler surgical approach appears to have good relevance to preserving vein graft integrity.

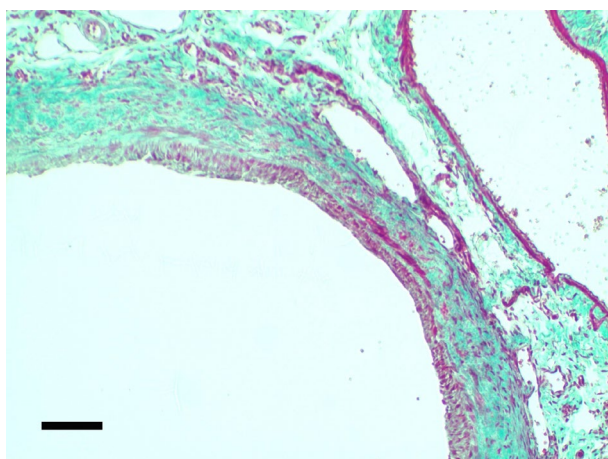
## NEOINTIMAL FORMATION

As mentioned, most experimental studies into vein graft complications have focused on the development of neointimal formation and its presumed progression to stenotic complications and graft occlusion, using rat and rabbit *in vivo* models. These models are straightforward to conduct, are usually done in end-to-end interpositional graft fashion (a difference from clinical CABG), and are evaluated at relatively early time points (2-12 weeks) in comparison to CABG assessments (6-24 months). These models use histomorphometry of the neointimal thickness or area, or a neointima: media thickness ratio, as surrogate markers for stenotic lesion development. Numerous studies have shown that a variety of factors can reduce the extent of neointimal thickening in these grafts, with many focusing on inhibiting smooth muscle proliferation; the possible list of these publications is quite extensive and is not provided here, for brevity.

Of clinical relevance, studies in rabbit JV grafts were used to show that edifoligide, an oligodesoxynucleotide designed to block E2F-mediated smooth muscle cell proliferation, reduced neointimal thickening without influencing endothelial cells;<sup>27-29</sup> these studies served as pre-clinical findings to support the PREVENT IV trial of edifoligide prevention of neointima-associated stenosis.<sup>30,31</sup> This trial, though exemplary of an excellently conducted clinical trial, failed to show efficacy from the treatment.<sup>30</sup> Much speculation ensued following the outcome in an effort to identify the cause(s) of treatment failure.<sup>31-33</sup>

To get at the root of this problem, and the translational potential of experimental vein grafting, a more critical appraisal is warranted. Using experimental neointimal wall thickness as

a surrogate for vein graft stenosis may be inherently flawed. Veins transferred into an arterial environment undergo “arterialization”, what is arguably a beneficial remodeling to arterial shear and pressure, developing a healthy smooth-muscle-dominated neointimal wall as an adaptive response. What is needed in experimental vein graft models is a further progression of this response toward inward growth, “negative remodeling” of the wall, with even greater neointimal thickening that reduces the luminal cross-sectional area and that can progress to stenotic occlusion. Very few vein graft models have demonstrated this negative remodeling; most rat and rabbit models, whether using EV, FV, or JV grafts, show a nicely maintained luminal area without any apparent flow reduction (Figure 1A). Thus, developing approaches to reduce neointimal thickness in these models may, in truth, be a demonstration not of preventing neointima-associated stenosis (the desired finding), but of inducing incomplete, stunted arterialization of these grafts, essentially a pathologic thinning of an otherwise favorable adaptation of the vein to the arterial environment.

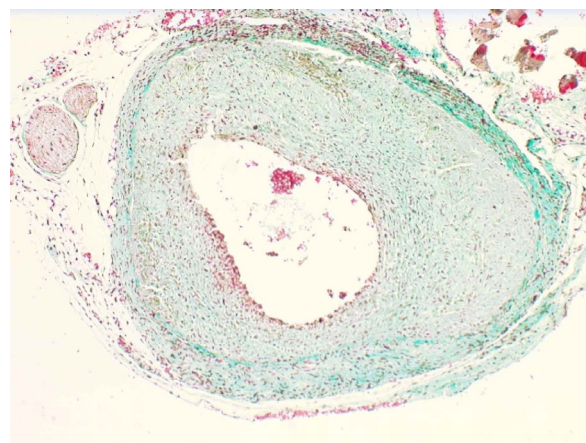


**Figure 1A:** Rat femoral vein graft to femoral artery harvested at 4 weeks, showing proximal region of graft with modest “arterialized” neointima (mostly stained red adjacent to lumen; a portion of the ipsilateral femoral vein is seen in the upper right) (Masson’s trichrome stain).

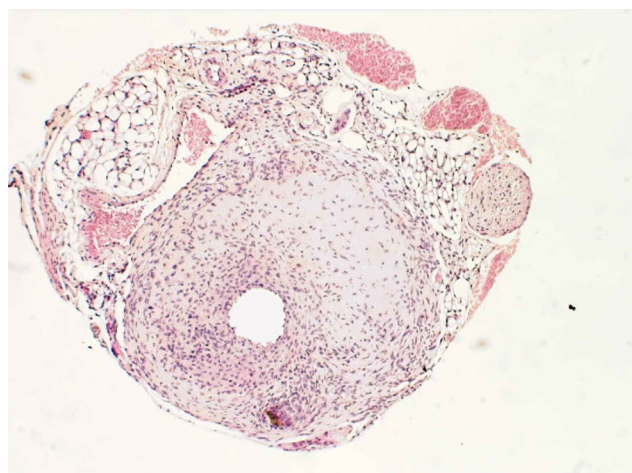
Vein graft models that progress toward some degree of pathophysiologic stenosis are needed but in short supply. Histologic images and histomorphometric evaluations of the standard rat and rabbit vein graft models do not show evidence of substantial stenosis (Figure 1A). In fact, one histomorphometric measure, the luminal radius to wall thickness ratio, is typically ~10 in rabbit JV grafts,<sup>27,29</sup> indicating a high degree of luminal area preservation without stenotic encroachment. Even in larger animal models, like swine,<sup>34,35</sup> canine<sup>36,37</sup> and even non-human primates,<sup>38</sup> there is little evidence of stenotic, negative remodeling. There have been reports with ovine and canine models showing substantial stenosis in grafts, particularly near the anastomoses where non-laminar disturbed flow patterns are predicted. These large animal models also have arguably the most clinical relevance. Indeed, a report by Abbasi et al.<sup>39</sup> used an ovine direct analogue to CABG, grafting the saphenous vein as a bypass graft to the left anterior descending coronary artery, with the identification of a greatly thickened vein graft wall. Shiroma and Kusaba<sup>40</sup> used a canine FV graft to the femoral artery, again

providing histologic evidence of substantial luminal stenosis in the grafted vein. Saito and colleagues<sup>41</sup> used a similar model and demonstrated greatly thickened neointima relative to other vein graft models. The drawback to these and similar large-animal vein graft models is the high budgetary considerations in their application.

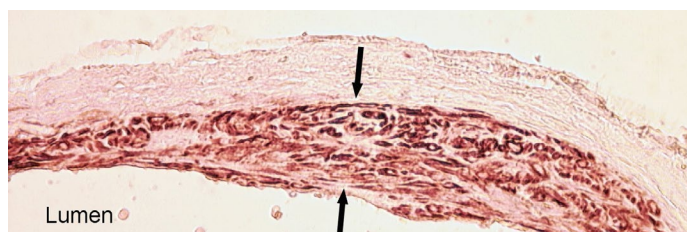
Over the past 17 years, several mouse vein graft models have emerged,<sup>26,42-47</sup> primarily developed for their potential application in this extensively genome-manipulated species. A recent review<sup>9</sup> of these murine models placed them into perspective for their clinical relevance and utility, identifying a model developed by this author as most clinically relevant, though technically the most demanding. This model simulates many of the complications associated with clinical CABG: 1) the acute thrombosis rate is comparable, at ~20%; 2) the neointima is thickest near the anastomotic repair sites where flow disturbance (oscillatory flow) can be presumed to support neointimal overgrowth (Figures 1B and 1C); 3) the recipient artery (femoral) is a muscular artery more like the coronary artery than elastic arteries such as the carotid or abdominal aorta (more typical recipient sites in mouse models); 4) the vein donor graft is obtained from the posterior facial vein, a peripheral neck vein in the loose connective tissue, akin to the donor site of the saphenous vein and unlike other mouse model vein grafts that most often use the inferior vena cava; 5) the donor graft, despite its fragility and small size, can be engrafted with preservation of its venous endothelium which, in itself, has been shown to contribute to the neointima through an endothelial-to-mesenchymal transdifferentiation process (Figures 2A and 2B);<sup>48</sup> and perhaps of greatest relevance, 6) the neointima develops to a very high extent (Figure 1C), absolutely comparable in dimensional thickness to rat, rabbit, and even dog and pig models (100 or more microns);<sup>26,49</sup> under the vessel diameter conditions of the mouse, this translates to a substantial stenotic lesion that often results in a luminal radius:neointima wall thickness ratio of less than 1 and leads to stenotic occlusion in 3-6% of these grafts within 30 days.<sup>26,49</sup> The drawback of this model is its extreme difficulty due to the sutured engraftment into such a small artery (0.2 mm diameter of the femoral vein in an adult mouse).



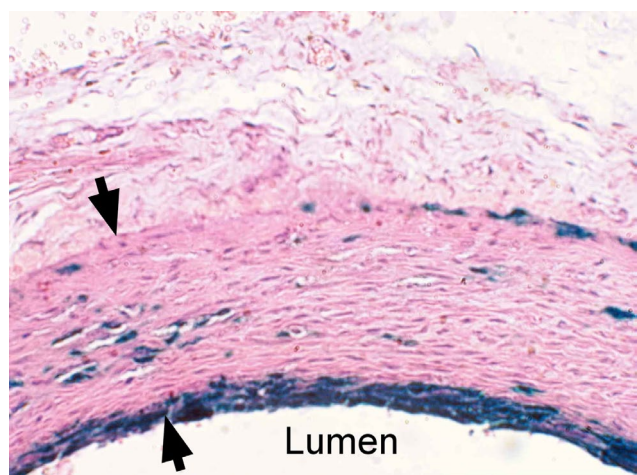
**Figure 1B:** murine posterior facial vein graft into femoral artery at the same harvest time, proximal location, magnification, and staining conditions, showing substantially greater absolute neointimal thickening.



**Figure 1C:** highly stenotic murine graft at 4 weeks, with nearly occluded lumen (H&E stain); bar in A = 100 microns, applicable to all images.



**Figure 2A:** Immunohistochemical stain of murine vein graft at 4 weeks, using smooth muscle actin antibody to demonstrate extensive smooth muscle cell presence within the neointima (shown between the arrows).



**Figure 2B:** Murine vein graft from a LacZ-cell-lineage-tracing donor mouse (expressing β-galactosidase (blue X-Gal stain) in endothelial cells and their descendants), grafted into a wild-type mouse and harvested at 4 weeks, with H&E counterstaining, showing multi-layer and localized clonal presence of endothelial-lineage cells within the neointima (shown between the arrows).

## ATHEROSCLEROSIS

Long-term vein graft failures are often attributed to atherosclerotic lesion development within the graft. Composite, negative remodeling from neointima and atherosclerosis are called vein graft disease.<sup>6,50</sup> However, as a disease entity it has been difficult to study the atherogenic side separately from neointimal stenosis, both clinically and experimentally. To complicate this issue, the experimental literature has been diluted

with an interchanging of terms, often substituting atherosclerotic terminology for what is more identifiable as neointimal formation, either without an atherogenic stimulus<sup>42</sup> or with superimposed atherogenesis.<sup>51,52</sup> This confusion in the literature is a major obstacle to understanding the fundamental mechanisms underlying vein graft pathologies. A better appreciation of the distinction between these pathologies would use the stable development of neointima that then progresses to atherosclerotic lesion presence, ideally with a substantial stenotic component. Larger animal models may be more conducive to these discriminations, using the longer time frame for atherogenesis for distinguishing arterIALIZING neointima from athero-like lesions. Because of the high involvement of murine models in current research, it would also be very helpful to get a better understanding of which of the various murine vein graft models are optimal for dissecting out these thorny problems, rather than assuming that “any” vein graft model is adequate.

In summary, there are a wide variety of *in vivo* models for studying vein graft complications. Critical assessment is needed for what each model demonstrates and what clinical relevance each model holds. Future studies should make model selection an important criterion for exploring the causes of vein graft failure and approaches to its prevention.

## REFERENCES

- Hillis LD, Smith PK, Anderson JL, et al. 2011 ACCF/AHA Guideline for Coronary Artery Bypass Surgery: Executive Summary. *Circulation*. 2011; 124: 2610-2642. doi: [10.1161/CIR.0b013e31823b5fee](https://doi.org/10.1161/CIR.0b013e31823b5fee)
- Bangalore S, Guo Y, Samadashvili Z, Blecker S, Xu J, Hannan EL. Everolimus-eluting stents or bypass surgery for multivesel coronary disease. *N Engl J Med*. 2015; 372:1213-1222. doi: [10.1056/NEJMoa1412168](https://doi.org/10.1056/NEJMoa1412168)
- Cohen DJ, Osnabrugge RL, Magnuson EA, et al. Cost-effectiveness of percutaneous coronary intervention with drug-eluting stents *versus* bypass surgery for patients with 3-vessel or left main coronary artery disease: final results from the synergy between percutaneous coronary intervention with taxus and cardiac surgery (SYNTAX) trial. *Circulation*. 2014; 130: 1146-1157. doi: [10.1161/CIRCULATIONAHA.114.009985](https://doi.org/10.1161/CIRCULATIONAHA.114.009985)
- Deb S, Wijeyesundera HC, Ko DT, Tsubota H, Hill S, Fries SE. Coronary artery bypass graft surgery *vs* percutaneous interventions in coronary revascularization: a systematic review. *JAMA*. 2013; 310: 2086-2095. doi: [10.1001/jama.2013.281718](https://doi.org/10.1001/jama.2013.281718)
- Halabi AR, Alexander JH, Shaw LK, et al. Relation of early saphenous vein graft failure to outcomes following coronary artery bypass surgery. *Am J Cardiol*. 2005; 96: 1254-1259. doi: [10.1016/j.amjcard.2005.06.067](https://doi.org/10.1016/j.amjcard.2005.06.067)
- Motwani JG, Topol EJ. Aortocoronary saphenous vein graft

- disease: pathogenesis, predisposition, and prevention. *Circulation*. 1998; 97:916-931. doi: [10.1161/01.CIR.97.9.916](https://doi.org/10.1161/01.CIR.97.9.916)
7. Schachner T, Laufer G, Bonatti J. *In vivo* (animal) models of vein graft disease. *European Journal of Cardio-thoracic Surgery*. 2006; 30: 451-463. doi: [10.1016/j.ejcts.2006.06.015](https://doi.org/10.1016/j.ejcts.2006.06.015)
8. Thomas AC. Animal models for studying vein graft failure and therapeutic interventions. *Current Opinion in Pharmacology*. 2012; 12: 121-126. doi: [10.1016/j.coph.2012.01.002](https://doi.org/10.1016/j.coph.2012.01.002)
9. Yu P, Nguyen BT, Tao M, Campagna C, Ozaki CK. Rationale and practical techniques for mouse models of early vein graft adaptations. *J VascSurg*. 2010; 52: 444-452. doi: [10.1016/j.jvs.2010.03.048](https://doi.org/10.1016/j.jvs.2010.03.048)
10. Cooney WP 3<sup>rd</sup>. Revascularization and replantation after upper extremity trauma: experience with interposition artery and vein grafts. *Clin Ortho Rel Res*. 1978; 137: 227-234.
11. Khouri RK, Cooley BC, Kunselman AR, et al. A prospective study of microvascular free-flap surgery and outcome. *Plast Reconstr Surg*. 1998; 102: 711-721.
12. Yan H, Jackson WD, Songcharoen S, et al. Vein grafting in fingertip replantations. *Microsurgery*. 2009; 29: 275-281. doi: [10.1002/micr.20614](https://doi.org/10.1002/micr.20614)
13. Pomerance J, Truppa K, John Bilos ZJ, Vender MI, Ruder JR, Sagerman SD. Replantation and revascularization of the digits in a community microsurgical practice. *J Reconstr Microsurg*. 1997; 13: 163-170. doi: [10.1055/s-2007-1006400](https://doi.org/10.1055/s-2007-1006400)
14. Anand SX, Viles-Gonzalez JF, Mahboobi SK, Heerdt PM. Bivalirudin utilization in cardiac surgery: shifting anticoagulation from indirect to direct thrombin inhibition. *Can J Anesth*. 2011; 58: 296-311. doi: [10.1007/s12630-010-9423-0](https://doi.org/10.1007/s12630-010-9423-0)
15. Koster A, Chew D, Grundel M, et al. Bivalirudin monitored with the ecarin clotting time for anticoagulation during cardiopulmonary bypass. *Anesth Analg*. 2003; 96: 383-386.
16. Chesebro JH, Clements IP, Fuster V, et al. A platelet-inhibitor-drug trial in coronary-artery bypass operations. Benefit of perioperative dipyridamole and aspirin therapy on early postoperative vein-graft patency. *N Engl J Med*. 1982; 307: 73-78. doi: [10.1056/NEJM198207083070201](https://doi.org/10.1056/NEJM198207083070201)
17. Rosa M, Lie JT, Bianco RL, Kaye MP. Reduction of thrombosis in canine coronary bypass vein grafts with dipyridamole and aspirin. *Am J Cardiol*. 1981; 47: 1248-1254. doi: [10.1016/0002-9149\(81\)90254-X](https://doi.org/10.1016/0002-9149(81)90254-X)
18. Mannacio VA, Di Tommaso L, Antignan A, DeAmicis V, Vosa C. Aspirin plus clopidogrel for optimal platelet inhibition following off-pump coronary artery bypass surgery: results from the CRYSSA (prevention of Coronary artery bypass occlusion after off-pump procedures) randomised study. *Heart*. 2012; 98: 1710-1715. doi: [10.1136/heartjnl-2012-302449](https://doi.org/10.1136/heartjnl-2012-302449)
19. Gottlob R. The preservation of the venous endothelium by 'dissection without touching' and by an atraumatic technique of vascular anastomosis. The importance for arterial and venous surgery. *Minerva Chir*. 1977; 32: 693-700.
20. Adcock OT, Adcock GL, Wheeler JR, Gregory RT, Snyder SO, Gayle RG. Optimal techniques for harvesting and preparation of reversed autogenous vein grafts for use as arterial substitutes: a review. *Surgery*. 1984; 96: 886-894.
21. Tsui JCS, Souza DSR, Filbey D, Bomfim V, Dashwood MR. Preserved endothelial integrity and nitric oxide synthase in saphenous vein grafts harvested by a 'no-touch' technique. *Brit J Surg*. 2001; 88: 1209-1215. doi: [10.1046/j.0007-1323-2001.01855.x](https://doi.org/10.1046/j.0007-1323-2001.01855.x)
22. Lumsden AB, Eaves FF III, Ofenloch JC, Jordan WD. Subcutaneous, video-assisted saphenous vein harvest: report of the first 30 cases. *Cardiovasc Surg*. 1996; 4: 771-776. doi: [10.1016/s0967-2109\(96\)00055-5](https://doi.org/10.1016/s0967-2109(96)00055-5)
23. Allen KB, Griffith GL, Heimansohn DA, et al. Endoscopic versus traditional saphenous vein harvesting: a prospective, randomized trial. *Ann Thorac Surg*. 1998; 66: 26-31. doi: [10.1016/S0003-4975\(98\)00392-0](https://doi.org/10.1016/S0003-4975(98)00392-0)
24. Williams JB, Peterson ED, Brennan JM, et al. Association between endoscopic vs. open vein-graft harvesting and mortality, wound complications, and cardiovascular events in patients undergoing CABG surgery. *JAMA*. 2012; 308: 473-484. doi: [10.1001/jama.2012.8363](https://doi.org/10.1001/jama.2012.8363)
25. Ehsan A, Mann MJ, Dell'Acqua G, Tamura K, Braun-Dul-laues R, Dzau VJ. Endothelial healing in vein grafts: proliferative burst unimpaired by genetic therapy of neointimal disease. *Circulation*. 2002; 105: 1686-1692.
26. Cooley BC. Murine model of neointimal formation and stenosis in vein grafts. *Arterioscler Thromb Vasc Biol*. 2004; 24: 1180-1185. doi: [10.1161/01.ATV.0000129330.19057.9f](https://doi.org/10.1161/01.ATV.0000129330.19057.9f)
27. Mann MJ, Gibbons GH, Kernoff RS, et al. Genetic engineering of vein grafts resistant to atherosclerosis. *Proc Natl Acad Sci USA*. 1995; 92: 4502-4506.
28. Mann MJ, Gibbons GH, Tsao PS, et al. Cell cycle inhibition preserves endothelial function in genetically engineered rabbit vein grafts. *J Clin Invest*. 1997; 99: 1295-1301. doi: [10.1172/JCI119288](https://doi.org/10.1172/JCI119288)
29. Ehsan A, Mann MJ, Dell'Acqua G, Dzau VJ. Long-term

- stabilization of vein graft wall architecture and prolonged resistance to experimental atherosclerosis after E2F decoy oligonucleotide gene therapy. *J ThoracCardiovascSurg.* 2001; 121: 714-722. doi: [10.1067/mtc.2001.111204](https://doi.org/10.1067/mtc.2001.111204)
30. Alexander JH, Hafley G, Harrington RA, et al. Efficacy and safety of edifoligide, an E2F transcription factor decoy, for prevention of vein graft failure following coronary artery bypass graft surgery. *JAMA.* 2005; 294: 2446-2454. doi: [10.1001/hama.294.19.2446](https://doi.org/10.1001/hama.294.19.2446)
31. Lopes RD, Williams JB, Mehta RH, et al. Edifoligide and long-term outcomes after coronary artery bypass grafting: Project of Ex-vivo Vein graft ENgineering via Transfection IV (PRE-VENT IV) 5-year results. *Am Heart J.* 2012; 164: 379.e1-386.e1. doi: [10.1016/j.ahj.2012.05.019](https://doi.org/10.1016/j.ahj.2012.05.019)
32. Cai X, Freedman NJ. New therapeutic possibilities for vein graft disease in the post-edifoligide era. *Future Cardiol.* 2006; 2: 493-501. doi: [10.2217/14796678.2.4.493](https://doi.org/10.2217/14796678.2.4.493)
33. Lopes RD, Mehta RH, Hafley GE, et al. Relationship between vein graft failure and subsequent clinical outcomes after coronary artery bypass surgery. *Circulation.* 2012; 125: 749-756. doi: [10.1161/CIRCULATIONAHA.111.040311](https://doi.org/10.1161/CIRCULATIONAHA.111.040311)
34. Mannion JD, Ormont ML, Magno MG, O'Brien JE, Shi Y, Zalewski A. Sustained reduction of neointima with c-myc antisense oligonucleotides in saphenous vein grafts. *Ann Thorac Surg.* 1998; 66: 1948-1952. doi: [10.1016/S0003-4975\(98\)01168-0](https://doi.org/10.1016/S0003-4975(98)01168-0)
35. Mehta D, George SJ, Jeremy JY, et al. External stenting reduces long-term medial and neointimal thickening and platelet derived growth factor expression in a pig model of arteriovenous bypass grafting. *Nat Med.* 1998; 4: 235-239. doi: [10.1038/nm0298-235](https://doi.org/10.1038/nm0298-235)
36. Rittgers SE, Karayannacos PE, Guy JF, et al. Velocity distribution and intimal proliferation in autologous vein grafts in dogs. *Circ Res.* 1978; 42: 792-801.
37. Keynton RS, Evancho MM, Sims RL, Rodway NV, Gobin A, Rittgers SE. Intimal hyperplasia and wall shear in arterial bypass graft distal anastomoses: an *in vivo* model study. *J BiomechEng.* 2001; 123: 464-473. doi: [10.1115/1.1389461](https://doi.org/10.1115/1.1389461)
38. Zilla P, Moodley L, Scherman J, et al. Remodeling leads to distinctly more intimal hyperplasia in coronary than in infrainguinal vein grafts. *J VascSurg.* 2012; 55: 1734-1741. doi: [10.1016/j.jvs.2011.11.057](https://doi.org/10.1016/j.jvs.2011.11.057)
39. Abbasi K, Shalileh K, Anvari MS, et al. Perivascular nitric oxide delivery to saphenous vein grafts prevents graft stenosis after coronary artery bypass grafting: a novel sheep model. *Cardiol.* 2011; 118: 8-15. doi: [10.1159/000324316](https://doi.org/10.1159/000324316)
40. Shiroma H, Kusaba A. Ultrastructural features of progressive intimal hyperplasia at the distal end-to-side anastomosis of vein grafts. *Cardiovasc Surg.* 1996; 4: 393-398. doi: [10.1016/0967-2109\(95\)00081-X](https://doi.org/10.1016/0967-2109(95)00081-X)
41. Saito T, Iguchi A, Tabayashi K. Irradiation inhibits vascular anastomotic stenosis in a canine model. *Gen Thorac Cardiovasc Surg.* 2009; 57: 406-412. doi: [10.1007/s11748-009-0413-5](https://doi.org/10.1007/s11748-009-0413-5)
42. Zou Y, Dietrich H, Hu Y, Metzler B, Wick G, Xu Q. Mouse model of venous bypass graft arteriosclerosis. *Am J Pathol.* 1998; 153: 1301-1310. doi: [10.1016/S0002-9440\(10\)65675-1](https://doi.org/10.1016/S0002-9440(10)65675-1)
43. Zhang L, Hagen PO, Kisslo J, Peppel K, Freedman NJ. Neointimal hyperplasia rapidly reaches steady state in a novel murine vein graft model. *J VascSurg.* 2002; 36: 824-832. doi: [10.1067/mva.2002.126308](https://doi.org/10.1067/mva.2002.126308)
44. Diao Y, Xue J, Segal MS. A novel mouse model of autologous venous graft intimal hyperplasia. *J Surg Res.* 2005; 126: 106-113. doi: [10.1016/j.jss.2005.01.025](https://doi.org/10.1016/j.jss.2005.01.025)
45. Salzberg SP, Filsoufi F, Anyanwu A, et al. Increased neointimal formation after surgical vein grafting in a murine model of type 2 diabetes. *Circulation.* 2006; 114: 1302-1307. doi: [10.1161/CIRCULATIONAHA.105.001339](https://doi.org/10.1161/CIRCULATIONAHA.105.001339)
46. Shi C, Patel A, Zhang D, et al. Plasminogen is not required for neointima formation in a mouse model of vein graft stenosis. *Circ Res.* 1999; 84: 883-890. doi: [10.1161/01.RES.84.8.883](https://doi.org/10.1161/01.RES.84.8.883)
47. Sakaguchi T, Asai T, Belov D, et al. Influence of ischemic injury on vein graft remodeling: role of cyclic adenosine monophosphate second messenger pathway in enhanced vein graft preservation. *J ThoracCardiovascSurg.* 2005; 129: 129-137. doi: [10.1016/j.jtcvs.2004.04.014](https://doi.org/10.1016/j.jtcvs.2004.04.014)
48. Cooley BC, Nevado J, Mellad J, et al. TGF- $\beta$  signaling mediates endothelial to mesenchymal transition (EndMT) during vein graft remodeling. *Science Translat Med.* 2014; 6: 227ra234. doi: [10.1126/scitranslmed.3006927](https://doi.org/10.1126/scitranslmed.3006927)
49. Cooley BC. Differential neointimal response in vein grafts and wire-injured arteries. *Circ J.* 2007; 71: 1649-1652. doi: [10.1253/circj.71.1649](https://doi.org/10.1253/circj.71.1649)
50. Lytle BW, Loop FD, Taylor PC, et al. Vein graft disease: the clinical impact of stenoses in saphenous vein bypass grafts to coronary arteries. *J ThoracCardiovascSurg.* 1992; 103: 831-840.
51. Leitges M, Mayr M, Braun U, et al. Exacerbated vein graft arteriosclerosis in protein kinase Cdelta-null mice. *J Clin Invest.* 2001; 108: 1505-1512. doi: [10.1172/JCI12902](https://doi.org/10.1172/JCI12902)

52. Hu Y, Mayr M, Metzler B, Erdel M, Davison F, Xu Q. Both donor and recipient origins of smooth muscle cells in vein-graft atherosclerotic lesions. *Circ Res.* 2002; 91: e13-e20. doi: [10.1161/01.RES.0000037090.34760.EE](https://doi.org/10.1161/01.RES.0000037090.34760.EE)