

Research

*Corresponding author

Syed Najam Hyder, MBBS, MCPS, FCPS, PhD
Associate Professor
Department of Pediatric Cardiology
Children Hospital and Institute of Child
Health, Lahore, Pakistan
Tel. 92333-4262250
E-mail: drnajamhyder@gmail.com

Volume 3 : Issue 1

Article Ref. #: 1000HROJ3127

Article History

Received: May 4th, 2016

Accepted: May 19th, 2016

Published: May 20th, 2016

Citation

Bajwa A, Hyder SN, Aziz S. The factors causing left atrial appendage clot formation in patients with severe rheumatic mitral stenosis. *Heart Res Open J.* 2016; 3(1): 1-5. doi: [10.17140/HROJ-3-127](https://doi.org/10.17140/HROJ-3-127)

Copyright

©2016 Hyder SN. This is an open access article distributed under the Creative Commons Attribution 4.0 International License (CC BY 4.0), which permits unrestricted use, distribution, and reproduction in any medium, provided the original work is properly cited.

The Factors Causing Left Atrial Appendage Clot Formation in Patients With Severe Rheumatic Mitral Stenosis

Ayesha Bajwa, MD; Syed Najam Hyder, MCPS, FCPS, FCPS*; Saba Aziz, MD

Department of Pediatric Cardiology, The Children's Hospital and Institute of Child Health, Lahore, Pakistan

ABSTRACT

Background: Rheumatic mitral stenosis still present in the developing world. Left atrial appendage clot is a common complication of mitral stenosis. The management differs significantly if there is presence of clot.

Objective: We assessed the factors responsible for left atrial appendage clot formation in patients with severe mitral stenosis through transesophageal echocardiography

Methods: An observational study was conducted among 82 (73 females, mean age 35.8±11.8 years) patients with severe mitral stenosis who underwent transesophageal echocardiography before percutaneous transmitral commissurotomy. Patients were classified into two groups based on the presence or absence of left atrial thrombus. Group 1 consisted of 24 patients (women to men ratio 91:9) with left atrial thrombus, while group 2 consisted of 58 patients (women to men ratio 88:12) without left atrial thrombus. Transesophageal echocardiographic findings were reviewed in all patients.

Results: There was no significant difference between the two groups in terms of age, sex, systolic pulmonary artery pressure and mitral valve mean pressure gradient (MVMPG), there was significant difference regarding frequency of atrial fibrillation ($p \leq 0.05$), left atrial size ($p \leq 0.05$), mitral valve area and flow velocities ($p \leq 0.05$) in group-1 patients. Similarly, atrial fibrillation was observed in 35(42.7%) patients out of which 20(83.3%) patients had thrombus in left atrial appendage.

Conclusion: The frequency of left atrial thrombus formation increased in patients with rheumatic mitral stenosis because of low left atrial appendage flow velocities, atrial fibrillation and smaller mitral valve area.

KEYWORDS: Mitral stenosis; Left atrial appendage; Thrombus; Echocardiography.

INTRODUCTION

Mitral stenosis is a huge burden in the third world countries.¹⁻⁴ It has been reported that the incidence of rheumatic fever is 206/100,000 and prevalence of rheumatic heart disease is 18.6/1000.⁵ The prevalence of rheumatic heart disease (RHD) in Pakistan is also high like other third world countries and was found to be 22/1000 in inner Lahore and 5.7/1000.⁵ The most effected valve in rheumatic heart disease is mitral valve.⁶ It is solely affected in 25% and is affected in combination with other valves in 40% of patients.⁴ The symptoms develop 10 to 20 years after the disease which include chest discomfort, cough, and shortness of breath during exercise, hemoptysis and atrial fibrillation.⁷

Mitral stenosis can lead to enlargement of the left atrium (LA) leading to increased risk of thrombus formation.⁸ The frequency of left atrial thrombi is between 20 and 33% according to the literature.⁷ Left atrial thrombus is more frequently associated with embolic events.⁹

Left Atrial Appendage (LAA) is the common site for thrombus formation.¹⁰ Increasing age and severity of mitral stenosis (MS) also increase the risk of thrombus formation.^{4,10} De-

pressed LAA function has also shown to be one of the predictor of LAA clot formation.¹¹ Left atrial thrombus can be defined as echo dense mass of any size with independent motion relative to chamber wall found in left atrial cavity or LAA.¹²

The accessibility of the left atrial appendage by transesophageal echocardiography (TEE) is better than transthoracic echocardiography (TTE) for detection of clot. We designed this study to evaluate various echocardiographic predictors for LA clot in patients with severe mitral stenosis.

ETHICS COMMITTEE APPROVAL

Taking approval through ethical committee of The Children Hospital and Institute of Child Health, Lahore, Pakistan.

METHODS

In this observational study, a total of 82 patients (range from 21 to 65 years, mean age was 35.8±11.8 years) of severe mitral stenosis who were referred to perform Transesophageal echocardiography (TEE) were included before percutaneous transmitral commissurotomy (PTMC). A written informed consent was obtained from all patients. Mitral stenosis was diagnosed on the basis of TEE and atrial fibrillation was demonstrated on baseline electrocardiogram. Findings of ECG and echocardiogram were document. Patients with mitral regurgitation, significant aortic valve disease, previous closed mitral valvotomy and currently taking anticoagulation or antiplatelet therapy were excluded from study.

All patients were divided into two groups based on presence or absence of thrombus. Group I consisted of 24 patients (2 men and 22 women) with left atrial thrombus. Group 2 consisted of 52 patients (7 men and 51 women) without left atrial thrombus.

TEE examination

A complete transthoracic echocardiographic (TTE) examination was done in all patients with a 2-5 MHz transducer. Mitral valve area was measured by continuous wave Doppler using pressure half time method.^{3,13} Systolic pulmonary artery pressure was measured using maximal tricuspid regurgitation velocity and applying Bernoulli equation to convert this value into pressure values. Estimated right atrial pressure was added in this value.³ To maximize the transthoracic visualization of left atrial thrombus all standard view were done along with angulations of

transducer.

TEE was performed in all cases after TTE using a 9 T MHz transducer multiplane probe. All patients were given local pharyngeal anesthesia (1% lidocaine spray) and intravenous diazepam 3 mg. During the study heart rate, blood pressure, single lead ECG and pulse oximetry were monitored. TEE probe was introduced with the patient lying supine in left lateral position. The left atrium was scanned in short axis and bicaval view.³ With a counter clockwise rotation of the probe at the level of aortic valve, left atrial appendage was visualized and thrombus was diagnosed by the presence of well-defined echogenic intracavity mass having an echo texture different from that of underlying endocardium.³ All TEE were performed by trained cardiologist who had experience of more than 5 years.

DATA ANALYSIS

Variables like LA size, mitral valve area (MVA), mitral valve mean pressure gradient (MVMPG), LAA flow velocity, pulmonary artery systolic pressure and thrombus in LA appendage were noted on the proforma for each patient along with ECG.

STATISTICAL ANALYSIS

Appropriate statistical data analysis technique by using SPSS version 20 was applied. Categorical variables were described by numbers and percentages while continuous variables were described as mean and SD (standard deviations). Chi square test was applied for categorical variables and independent sample t test was applied for comparison between these two groups. A level of 5% was considered significance.

RESULTS

Atrial fibrillation was observed in 35 (42.7%) patients (Table 1). Atrial fibrillation was more significantly associated with thrombus formation i.e. 20 (83.3%) patients having as compared to 4 (16.7%) having sinus rhythm (Figure 1). Patients with left atrial thrombus did not differ significantly from the patients without left atrial thrombus regarding age, sex, systolic pulmonary artery pressure (SPAP) and mitral valve mean peak gradient (MVMPG) ($p \geq 0.05$) but left atrial thrombus was found to be significantly higher in patients those had frequent atrial fibrillation ($p \leq 0.05$), larger left atrial size ($p \leq 0.05$), smaller mitral valve area and flow velocities ($p \leq 0.05$) which also indicate left atrial appendage dysfunction (Figure 2). Table 2 shows measurements of these variables between the two groups.

Variable	Total	Group I	Group II	P value	
Atrial fibrillation	Present	35(42.7 %)	20(83.3 %)	15(25.9 %)	0.000
	Absent	47(57.3 %)	4(16.7 %)	43(74.1 %)	0.000

Group I: Patients with thrombus; Group II: Patients without thrombus.

Table 1: Patients with atrial fibrillation in both groups (n=82).

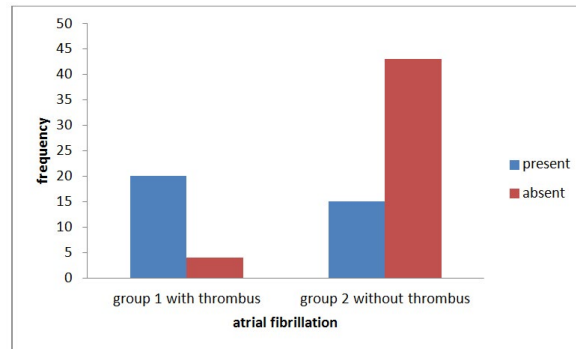
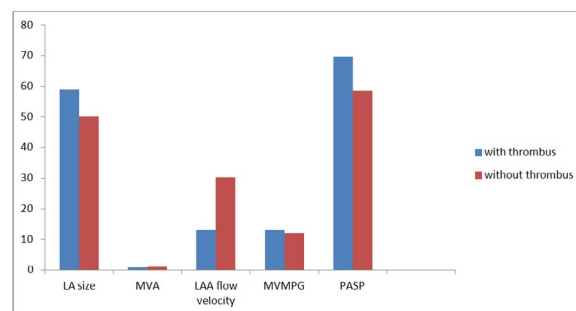


Figure 1: Frequency of atrial fibrillation in both groups.



LA: Left Atrium; LAA: Left Atrial appendage; MVA: Mitral valve area; MVPG: Mitral valve pressure gradient. PASP: Pulmonary artery systolic pressure.

Figure 2: Echocardiographic comparison of two groups (n=82).

Variables	Group I (with LA thrombus) n=24 (mean±S.D)	Group II (without LA thrombus) n=58 (mean±S.D)	p value
LA size (mm)	58.9±15.9	50.2±9.6	.003
MVA (cm ²)	0.93±0.18	1.14±0.35	.007
LAA flow velocity (cm/s)	13.0±2.40	30.2±11.0	.000
MVMPG (mmHg)	13.0±4.04	12.0±4.47	.085
PASP (mmHg)	69.71±9.7	58.61±5.6	.008

LA: Left Atrium; LAA: Left Atrial appendage; MVA: Mitral valve area; MVPG: Mitral valve pressure gradient. PASP: Pulmonary artery systolic pressure.

Table 2: Echocardiographic findings of two groups.

DISCUSSION

In this study we evaluated various echocardiographic predictors of thrombus formation. It was observed that significant echocardiographic predictors found in our study. Left atrial thrombus formation is a complication frequently encountered in patients with severe mitral stenosis with a higher chance of systemic embolization leading to higher morbidity and mortality.¹⁴ The increasing severity of mitral stenosis is significantly correlated with increased incidence of thrombus in the Left atrium and Left atrial appendage.¹⁵ Fifty percent of left atrial thrombi in patients with rheumatic valvular disease, and nearly 90% of left atrial thrombi in patients with non-valvular atrial fibrillation are limited to the LAA.¹⁶ Transesophageal echocardiography is superior to transthoracic echocardiography in the evaluation of LA thrombi.¹⁶ This is confirmed in this study as TEE clearly shows these abnormal changes related to the thrombus formation in the left atrium.

Our study supported that the severity of mitral stenosis was significantly related with thrombus formation as smaller the mitral valve area was. Ozkan et al found similar results.¹⁵ Similarly the frequency of Left atrial thrombus increases with atrial fibrillation and low flow velocities. Fazlinez had et al found that patients with left atrial thrombus had more LA appendage dysfunction, more frequent atrial fibrillation and smaller mitral valve area.¹⁷ Our study also supported that atrial fibrillation was significantly associated with thrombus formation ($p \leq 0.05$). Ali et al., found similar results in patients of rheumatic mitral stenosis³ and found that 60% of patients had LA thrombus.

Additionally in our results of low Left atrial appendage flow velocities were found to be associated with smaller mitral valve area and larger Left atrial size. Guler et al.¹⁸ found that Left atrial size was significantly higher in patients with low emptying velocities. In this context, these results are supporting our study as patients with mitral stenosis and low LAA flow velocities

had smaller mitral valve area as compared with those with high LAA blood velocity.¹⁹ We observed more frequent occurrence of left atrial thrombus in patients with atrial fibrillation (83.3%) as compared to sinus rhythm. Goswami et al found similar results in patients of severe mitral stenosis as they had higher incidence of thrombus formation.⁷ In our study atrial fibrillation and left atrial enlargement were significantly associated with thrombus formation. Boonyasirinant et al found similar results.²⁰ Golbasi et al found that left atrial appendage dysfunction leading to thrombus formation can occur in patients of rheumatic mitral stenosis with sinus rhythm. So chances of left atrial thrombus may also be present with sinus rhythm.¹² Conradie et al found similar results that atrial fibrillation and left atrial enlargement are significant risk factors for thrombus formation in mitral stenosis.²¹

STUDY LIMITATIONS

A smaller number of patients was included in this study and it can lead to variations in results. Also this is single center experience. Multicenter studies with inclusion of more cases are required. We encountered patients with sinus rhythm and atrial fibrillation together but in future studies both groups should be separately studied.

CONCLUSION

The frequency of left atrial thrombus formation increased in patients with rheumatic mitral stenosis because of low left atrial appendage flow velocities, atrial fibrillation and smaller mitral valve area.

ACKNOWLEDGMENTS

We are extremely thankful to the department of echocardiography Gulab Devi cardiac complex, Lahore and Children hospital and Institute of child health, Lahore. Consent form filled after taking consent from patients. There is no financial support for this study. It was conducted for the partial fulfillment of the degree of B.Sc Hons in Medical Imaging Technology from University of health sciences, Lahore, Pakistan.

CONFLICTS OF INTEREST: No conflict of interest.

REFERENCES

- Ullah K, Ahmed SA, Badsha S, Khan A, Kiani MR. Rheumatic Heart disease - A study of surgically excised cardiac valves and biopsies. *J Coll Physicians Surg Pak*. 2002; 12(9): 542-545. Web site. https://inis.iaea.org/search/search.aspx?orig_q=RN:34023662. Accessed May 3, 2016
- Simkhada R, Man Bahadur KC, Yadav Deo Bhatt et al. Transoesophageal Echocardiographic Appraisal of Left Atrial Appendage Clot in Severe Mitral Stenosis. *NHJ*. 2013; 10(1): 27-29. doi: [10.3126/njh.v10i1.9744](https://doi.org/10.3126/njh.v10i1.9744)
- Ali M, Abid AR, Mallick NH. Clinical and Echocardiographic Predictors of Left Atrial Thrombus in Rheumatic Mitral Stenosis. *Annals*. 2009; 15(2): 1-9. Web site. <http://www.annalskemu.org/journal/index.php/annals/article/viewArticle/20>. Accessed May 3, 2016
- Zeb S, Ali J, Shah I. et al. Interrelationship between rhythm, left atrial size and thrombus formation in patients with mitral stenosis. *Pak Heart J*. 2012; 45(3): 160-165. Web site. <http://www.pkheartjournal.com/index.php/pkheart/article/view/549>. Accessed May 3, 2016
- Aurakzai HA, Hameed S, Shahbaz A, Gohar S, Qureshi M, Khan H, et al. Echocardiographic profile of rheumatic heart disease at a tertiary cardiac centre. *J Ayub MColl Abbottabad*. 2009; 21(2): 122-126. Web site. <http://faculty.mu.edu.sa/public/uploads/1338112272.3687Aurakzai.pdf>. Accessed May 3, 2016
- Alkhalifa MS, Elhassan HHM, Suliman FA, et al. Percutaneous transmitral balloon commissurotomy [PTMC]: Procedural success and immediate results at Ahmed Gasim Cardiac Center. *Sudan J Med Sci*. 2006; 1(2): 115-120.
- Goswami KC, Yadav R, Rao B, et al. Clinical and echocardiographic predictors of left atrial clot and spontaneous echo contrast in patients with severe rheumatic mitral stenosis: a prospective study in 200 patients by transesophageal echocardiography. *Intrn J Card*. 2000; 73(3): 273-279. doi: [10.1016/S0167-5273\(00\)00235-7](https://doi.org/10.1016/S0167-5273(00)00235-7)
- Olson LJ, Subramanian R, Ackermann DM. Surgical pathology of the mitral valve: a study of 712 cases spanning 21 years. *Mayo Clin Proc*. 1987; 62(1): 22-27. doi: [10.1016/S0025-6196\(12\)61522-5](https://doi.org/10.1016/S0025-6196(12)61522-5)
- Kronzon I, Tunick PA, Charney LH. Echocardiography as a tool in the evaluation of conditions with a high likelihood of cardioembolic embolism. *Isr Med Assoc J*. 2006; 8(11): 768-772.
- Acarturk E, Usal A, Demir M, Akgul F, Ozeren A. Thromboembolic risk in patients with mitral stenosis. *Japness Heart J*. 1997; 38(5): 669-675. doi: [10.1536/ihj.38.669](https://doi.org/10.1536/ihj.38.669)
- Goswami KC, Yadav R, Bahl VK. Predictors of left atrial appendage clot: A transesophageal echocardiographic study of left atrial appendage function in patients with severe mitral stenosis. *Indian Heart J*. 2004; 56(6): 628-635. Web site. <http://www.arabmedmag.com/issue-15-11-2005/cardiology/main03.htm>. Accessed May 3, 2016
- Golbasi Z, Cicek D, Canbay A, et al. Left atrial appendage function in patients with mitral stenosis in sinus rhythm. *Eur J Echocardiography*. 2002; 3(1): 39-43. doi: [10.1053/euje.2001.0110](https://doi.org/10.1053/euje.2001.0110)
- Douglas PS, Foster E, Gorscan J, et al. ACC/AHA Clinical

cal competence statement on echocardiography: A report of the American College of Cardiology / American Heart Association/ American College of Physicians American Society of Internal Medicine Task Force on Clinical Competence (Committee on Echocardiography). *J Am Coll Cardiol.* 2003; 41(4): 687-699. doi: [10.1016/S0735-1097\(02\)02885-1](https://doi.org/10.1016/S0735-1097(02)02885-1)

14. Chiag CW, Lo SK, Ko YS, Cheng NJ, Lin PJ, Chang CH. Predictor of systemic embolization in patients with mitral stenosis. A prospective study. *Ann Intern Med.* 1998; 128(11): 885-889. doi: [10.7326/0003-4819-128-11-199806010-00001](https://doi.org/10.7326/0003-4819-128-11-199806010-00001)

15. Ozkan M, Kaymaz C, Kirma C. Predictors of left atrial clot and spontaneous echo contrast in rheumatic valve disease before and after mitral valve replacement. *Am J Cardiol.* 1998; 82(9): 1066-1070. doi: [10.1016/S0002-9149\(98\)00556-6](https://doi.org/10.1016/S0002-9149(98)00556-6)

16. Kronzon I, Tunick PA, Charney LH. Echocardiography as a Tool in the Evaluation of Conditions with a High Likelihood of Cardiogenic Embolism. *IMAJ.* 2006; 8(11): 768-772. Web site. <http://www.ima.org.il/FilesUpload/IMAJ/0/49/24699.pdf>. Accessed May 3, 2016

17. Fazlinezhad A, Golmohammadzadeh H, Azari A, Bigdelu L. Echocardiographic predictor of left atrial thrombus formation in patients of rheumatic mitral stenosis. *Razaviintrn J Med.* 2002; 2(1): e15602. doi: [10.5812/rijm.15602](https://doi.org/10.5812/rijm.15602)

18. Guler N, Demirbag R, Ozkara C, et al. Clinical and echocardiographic predictors of left atrial appendage dysfunction in patients with rheumatic mitral stenosis in sinus rhythm. *American J Med.* 2004; 17(8): 819-823.

19. Marijon E, Mirabel M, Celermajer D, Jouven X. Rheumatic heart disease. 2012; 379(9819): 953-964. doi: [10.1016/S0140-6736\(11\)61171-9](https://doi.org/10.1016/S0140-6736(11)61171-9)

20. Boonyasirinant T, Phankinthongkum R, Komoltri C. Clinical and echocardiographic parameters and score for the left atrial thrombus formation in patients of mitral stenosis. *J Med Assoc Thai.* 2007; 9 0(2): 9-18. Web site. <http://citeseerx.ist.psu.edu/viewdoc/download?doi=10.1.1.619.7727&rep=rep1&type=pdf>. Accessed May 3, 2016

21. Conradil C, Schall R, Marx JD. Echocardiographic study of left atrial thrombus in mitral stenosis. *Clin Cardiol.* 1993; 16(10): 729-731. doi: [10.1002/clc.4960161008](https://doi.org/10.1002/clc.4960161008)