

Case Report

***Corresponding author**
Jessica Joseph, DO, MBA

Internal Medicine
Pennsylvania Hospital of the University
of Pennsylvania
3400 Spruce St, Philadelphia
PA 19104, USA

E-mail: Jessica.Joseph@uphs.upenn.edu

Volume 4 : Issue 2

Article Ref. #: 1000HROJ4138

Article History

Received: March 7th, 2017

Accepted: March 10th, 2017

Published: March 10th, 2017

Citation

Joseph J, Mahmoud Z, Naqvi S, Victor B. Left atrial appendage thrombus in a patient with atrial fibrillation on apixiban successfully treated with warfarin and pulmonary vein isolation ablation. *Heart Res Open J.* 2017; 4(2): 29-32. doi: [10.17140/HROJ-4-138](https://doi.org/10.17140/HROJ-4-138)

Copyright

©2017 Joseph J. This is an open access article distributed under the Creative Commons Attribution 4.0 International License (CC BY 4.0), which permits unrestricted use, distribution, and reproduction in any medium, provided the original work is properly cited.

Left Atrial Appendage Thrombus in a Patient with Atrial Fibrillation on Apixiban Successfully Treated with Warfarin and Pulmonary Vein Isolation Ablation

Jessica Joseph, DO, MBA^{1*}; Zainab Mahmoud, MD¹; Syed Naqvi, MD¹; Brett Victor, MD, FACC²

¹Internal Medicine, Pennsylvania Hospital of the University of Pennsylvania, Philadelphia, PA 19104, USA

²Clinical Cardiology, Pennsylvania Hospital of the University of Pennsylvania, Philadelphia, PA 19104, USA

ABSTRACT

Atrial fibrillation (AF) is a common cardiac arrhythmia that can be seen in hospitalized patients. It has been shown to be a major risk factor for cardioembolic stroke, and therefore patients are frequently started on lifelong anticoagulation. The majority of patients benefit from either cardioversion or pulmonary vein isolation ablation. We herein describe the case of a 58-year-old male with a past medical history of atrial fibrillation surgery who presented to hospital for elective atrial fibrillation ablation after failed medical therapy and persistent symptoms. A transesophageal echocardiogram (TEE) prior to the procedure demonstrated a left atrial appendage clot despite patient's compliance with apixiban. Subsequently, the patient is started on warfarin therapy with a heparin bridge. A TEE performed 6 weeks after discharge showed resolution of the left atrial appendage clot allowing the ablation procedure to be successfully performed.

KEY WORDS: Atrial fibrillation; Left atrial appendage thrombus; Novel anticoagulation; Apixiban; Warfarin.

ABBREVIATIONS: TEE: Transesophageal Echocardiogram; AF: Atrial Fibrillation; FXa: Factor Xa; EF: Ejection Fraction; LV: Left Ventricular; ECG: Electrocardiogram; ICE: Intracardiac echocardiogram.

INTRODUCTION

Atrial fibrillation (AF) is the leading cardiac arrhythmia in the United States (US). More than 2.7 million people in the US are known to have AF and this number is expected to rise to 12 million by 2030.¹⁻³ AF accounts for \$16-26 billion of annual US expenses.^{4,5} Stroke is the third most frequent cause of death in US and the leading cause of serious disability; for which AF is a major independent risk factor. It is responsible for 15% of 700,000 strokes occurring in the US each year.⁶

In AF, the uncoordinated atrial pulse causes pooling of blood in the atrium and more specifically in the left atrial appendage.⁷ The force of the coordinated atrial contraction can dislodge a thrombus from the left atrial appendage, which then can migrate to the brain causing an ischemic stroke secondary to cardio-embolism.⁷ The Copenhagen Stroke Study (a prospective, community-based study of 1197 patients with acute stroke) demonstrated that patients with AF had a higher mortality rate (OR, 1.7; 95% CI, 1.2 to 2.5), longer hospital stays (50 days vs. 40 days, $p < .001$), and a lower discharge rate to their own homes (OR, 0.60; 95% CI, 0.44 to 0.85).⁸ This study also demonstrated that neurological and functional outcomes were markedly poorer

in patients with atrial fibrillation due to more severe strokes.⁸ Vitamin K antagonists such as warfarin are highly effective in preventing stroke in patients with atrial fibrillation. Warfarin reduces the risk of stroke by two-thirds and mortality by one-quarter compared with control.⁹ Warfarin is highly effective in preventing stroke in patients with atrial fibrillation, but has several limitations such as narrow therapeutic window, and drug/food interactions. The limiting factors of warfarin have increased the use of the targeted oral anticoagulants such as Apixiban. Apixiban is direct factor Xa (FXa) inhibitors that prevents FXa from cleaving prothrombin to thrombin.

CASE REPORT

A 58-year-old male with a past medical history of atrial fibrillation (AF), ischemic cardiomyopathy (left ventricular (LV) ejection fraction (EF) of less than 25%), coronary artery disease status post coronary artery bypass graft, aortic stenosis status post bioprosthetic aortic valve replacement, hypertension, hyperlipidemia and obstructive sleep apnea presented pulmonary vein isolation ablation for atrial fibrillation after failed medical therapy and persistent symptoms. The patient initially presented to Pennsylvania Hospital Emergency Department 4 weeks prior with shortness of breath and dyspnea on exertion. He stated that his symptoms had progressively worsened and his electrocardiogram (ECG) revealed that he was in rapid atrial fibrillation. He was subsequently admitted and underwent a transesophageal echocardiogram (TEE) with no visualization of a left atrial appendage thrombus (Figure 1). A direct current cardioversion was performed with restoration of normal sinus rhythm. The patient was started on Apixiban 5 mg twice daily for a CHA₂DS₂-VASc score of 3 (congestive heart failure, coronary artery disease, and hypertension).

He was seen in follow-up as an outpatient on 2 weeks prior to presentation, where he endorsed symptoms of exertional dyspnea. His ECG showed AF. Although, he reported feeling “much better”, he still had exertional dyspnea, palpitations, and

light headedness. He denied chest pain and syncope. After consultation with an electrophysiologist, he was scheduled for an elective AF ablation procedure. At presentation to the hospital, his vital signs were heart rate of 110 beats per minute, blood pressure of 127/78, oxygen saturation of 97% on room air, temperature of 97.9 °F, and respiratory rate of 18 breaths per minute. On physical exam, he was a morbidly obese male in no acute distress, cardiac exam revealed an irregularly irregular rhythm. His lungs were clear to auscultation bilaterally. A TEE was performed prior to atrial fibrillation ablation procedure which demonstrated an EF of 25% with a new left atrial appendage thrombus (Figure 2). Intracardiac echocardiogram (ICE) also confirmed presence of the thrombus, therefore resulting in cancellation of the procedure. The patient was started on a heparin drip and was subsequently bridged to warfarin, with a goal Indian rupee (INR) of 2-3. He was continued on metoprolol 100 mg every 12 hours orally for rate control.

Outcome

Patient was discharged to home on coumadin therapy once his INR was therapeutic. A repeat TEE 4 weeks later showed resolution of the thrombus in left atrium (Figure 3). The patient underwent a successful pulmonary vein isolation ablation on the same day. There were no complications to the procedure and patient was continued on warfarin indefinitely.

DISCUSSION

Our case describes a patient that has failed apixiban therapy for his AF. The Aristotle trial compared apixiban to warfarin and demonstrated that apixiban 5 mg twice daily was superior to warfarin in preventing stroke or systemic embolism. It also caused less bleeding and resulted in lower mortality.¹⁰ On the other hand, some studies have suggested that Apixiban is known to make thrombi mobile and/or fragile, which causes detachment or partial fragmentation of left atrial appendage thrombus that can result in thromboembolism.¹¹⁻¹³ This is thought to be

Figure 1: TEE of Left Atrial Appendage Prior to Electrical Cardioversion with No Thrombus Present. Red Line Outlines the Border of the Left Atrial Appendage.

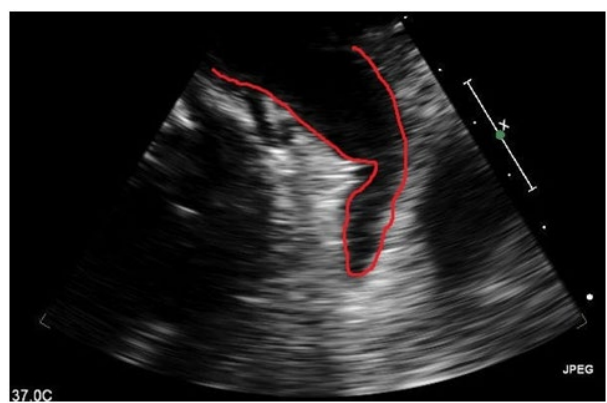
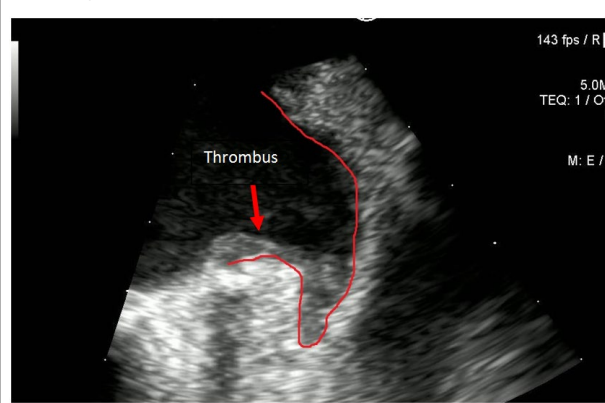
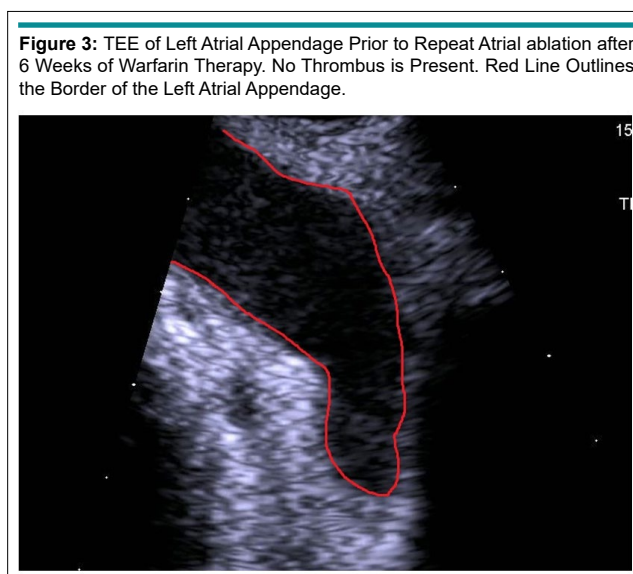


Figure 2: TEE of Left Atrial Appendage Prior to Atrial Fibrillation Ablation. Thrombus is Present. Red Line Outlines the Border of the Left Atrial Appendage.





secondary to apixiban shifting the coagulation/fibrinolysis balance to a relative predominance of fibrinolytic activity.¹³⁻¹⁶

Current practice is to have a TEE performed if a patient has been in AF for more than 48 hours to rule out a left atrial thrombus. If a patient has an atrial clot, they are anticoagulated for a duration of 4 weeks. A TEE is performed and if there is resolution of the thrombus, then a cardioversion is performed.¹⁷ Current evidence concludes that there does not appear to be a role for routine TEE prior to cardioversion in patients who has been adequately anticoagulated with warfarin or targeted anticoagulant for at least four weeks prior to cardioversion.¹⁸ The 2014 AF guidelines classify this recommendation as level C evidence. Seidl et al¹⁹ demonstrated that, in patients with AF and effective anticoagulation, TEE-guided electrical cardioversion does not reduce the embolic risk. However, TEE before direct-current cardioversion revealed left atrial thrombus in 7.7% of patients with AF and effective anticoagulation. As this case demonstrates, even four weeks of compliance with anticoagulation with direct acting agents such as apixiban does not completely protect against left atrial thrombus formation, and a pre-cardioversion TEE should be considered in all patients.

CONFLICTS OF INTEREST

The authors declare that they have no conflicts of interest.

REFERENCES

1. Colilla S, Crow A, Petkun W, Singer DE, Simon T, Liu X. Estimates of current and future incidence and prevalence of atrial fibrillation in the U.S. adult population. *Am J Cardiol.* 2013; 112: 1142-1147. doi: [10.1016/j.amjcard.2013.05.063](https://doi.org/10.1016/j.amjcard.2013.05.063)
2. Go AS, Hylek EM, Phillips KA, et al. Prevalence of diagnosed atrial fibrillation in adults: National implications for rhythm management and stroke prevention: The Anticoagulation and

Risk Factors in Atrial Fibrillation (ATRIA) Study. *JAMA.* 2001; 285: 2370-2375. doi: [10.1001/jama.285.18.2370](https://doi.org/10.1001/jama.285.18.2370)

3. Miyasaka Y, Barnes ME, Gersh BJ, et al. Secular trends in incidence of atrial fibrillation in Olmsted County, Minnesota, 1980 to 2000, and implications on the projections for future prevalence [published correction appears in *Circulation.* 2006; 114: e498]. *Circulation.* 2006; 114: 119-125. doi: [10.1161/CIRCULATIONAHA.105.595140](https://doi.org/10.1161/CIRCULATIONAHA.105.595140)
4. Chugh SS, Havmoeller R, Narayanan K, et al. Worldwide epidemiology of atrial fibrillation: A global burden of disease 2010 study. *Circulation.* 2014; 129(8): 837-847. doi: [10.1161/CIRCULATIONAHA.113.005119](https://doi.org/10.1161/CIRCULATIONAHA.113.005119)
5. Bialy D, Lehmann MH, Schumacher DN, Steinman RT, Meissner MD. Hospitalization for arrhythmias in the United States: Importance of atrial fibrillation [abstract]. *J Am Coll Cardiol.* 1992; 19: 41A.
6. Solomon MD, Ullal AJ, Hoang DD, Freeman JV, Heidenreich P, Turakhia MP. Cost-effectiveness of pharmacologic and invasive therapies for stroke prophylaxis in atrial fibrillation. *J Cardiovasc Med (Hagerstown).* 2012; 13(2): 86-96. doi: [10.2459/JCM.0b013e32834f23cf](https://doi.org/10.2459/JCM.0b013e32834f23cf)
7. Ball J, Carrington MJ, McMurray JJ, et al. Atrial fibrillation: Profile and burden of an evolving epidemic in the 21st century. *Int J Cardiol.* 2013; 167(5): 1807-1824. doi: [10.1016/j.ij-card.2012.12.093](https://doi.org/10.1016/j.ij-card.2012.12.093)
8. Jorgensen HS, Nakayama H, Reith J, Raaschou HO, Olsen TS. Acute stroke with atrial fibrillation the copenhagen stroke study. *Stroke.* 1996; 27: 1765-1769. doi: [10.1161/01.STR.27.10.1765](https://doi.org/10.1161/01.STR.27.10.1765)
9. Hart RG, Pearce LA, Aguilar MI. Meta-analysis: Antithrombotic therapy to prevent stroke in patients who have nonvalvular

- atrial fibrillation. *Ann Intern Med.* 2007; 146(12): 857-867. doi: [10.7326/0003-4819-146-12-200706190-00007](https://doi.org/10.7326/0003-4819-146-12-200706190-00007)
10. Granger CB, Alexander JH, McMurray JJV, et al. Apixaban versus warfarin in patients with atrial fibrillation. *N Engl J Med.* 2011; 365: 981-992. doi: [10.1056/NEJMoa1107039](https://doi.org/10.1056/NEJMoa1107039)
11. Yasaka M, Yamaguchi T, Miyashita T, Tsuchiya T. Regression of intracardiac thrombus after embolic stroke. *Stroke.* 1990; 21: 1540-1544. doi: [10.1161/01.STR.21.11.1540](https://doi.org/10.1161/01.STR.21.11.1540)
12. Fang BR, Kuo LT. Recurrent cerebral embolism and impending detachment of a previous non mobile left atrial thrombus following initiation of anticoagulant therapy in a patient with non valvular atrial fibrillation. *Echocardiography.* 2001; 18(6): 527-529. doi: [10.1046/j.1540-8175.2001.00527.x](https://doi.org/10.1046/j.1540-8175.2001.00527.x)
13. Ohyagi M, Nakamura K, Watanabe M, Fujigasaki H. Embolic stroke during apixaban therapy for left atrial appendage thrombus. *J Stroke Cerebrovasc Dis.* 2015; 24(4): e101-e102. doi: [10.1016/j.jstrokecerebrovasdis.2014.11.031](https://doi.org/10.1016/j.jstrokecerebrovasdis.2014.11.031)
14. Kawakami T, Kobayakawa H, Ohno H, et al. Resolution of left atrial appendage thrombus with apixaban. *Thromb J.* 2013; 11: 26. doi: [10.1186/1477-9560-11-26](https://doi.org/10.1186/1477-9560-11-26)
15. Dobashi S, Fujino T, Ikeda T. Use of apixaban for an elderly patient with left atrial thrombus. *BMJ Case Rep.* 2014; 2014: bcr2014203870. doi: [10.1136/bcr-2014-203870](https://doi.org/10.1136/bcr-2014-203870)
16. Saito S, Tomita H, Kimura Y, et al. Reduced smoke-like echo and resolved thrombus in the left atrium with rivaroxaban therapy in an acute cardio embolic stroke patient. *J Stroke Cerebrovasc Dis.* 2014; 23: 1747-1749. doi: [10.1016/j.jstrokecerebrovasdis.2014.01.014](https://doi.org/10.1016/j.jstrokecerebrovasdis.2014.01.014)
17. Collins LJ, Silverman DI, Douglas PS, Manning WJ. Cardioversion of non rheumatic atrial fibrillation. Reduced thrombo embolic complications with 4 weeks of precardioversion anticoagulation are related to atrial thrombus resolution. *Circulation.* 1995; 92(2): 160-163. doi: [10.1161/01.CIR.92.2.160](https://doi.org/10.1161/01.CIR.92.2.160)
18. January CT, Wann LS, Alpert JS, et al. 2014 AHA/ACC/HRS guideline for the management of patients with atrial fibrillation. *Circulation.* 2014; 130: e199-e267. doi: [10.1016/j.jacc.2014.03.022](https://doi.org/10.1016/j.jacc.2014.03.022)
19. Seidl K, Rameken M, Drögemüller A, et al. Embolic events in patients with atrial fibrillation and effective anticoagulation: Value of transesophageal echocardiography to guide direct-current cardioversion. Final results of the Ludwigshafen Observational Cardioversion Study. *J Am Coll Cardiol.* 2002; 39(9): 1436. doi: [10.1016/S0735-1097\(02\)01785-0](https://doi.org/10.1016/S0735-1097(02)01785-0)