

Case Illustration

Dynamic Shape Change of an Aortic Valve Cusp Perforation on 3D Transesophageal Echocardiogram

Maedeh Ganji, MD^{1*}; Jose Ruiz, MD¹; Robert Percy, MD²; Emil Missov, MD, PhD³; Srinivasan Sattiraju, MD⁴

¹Cardiology Fellow, University of Florida, Jacksonville, FL 32209, USA

²Associate Professor, University Term Professor, Department of Medicine, Division of Cardiology, University of Florida, Jacksonville, FL 32209, USA

³Medical Director of Heart Failure Program, Jacksonville, FL 32209, USA

⁴Medical Director, Cardiovascular Non-invasive Laboratory, Jacksonville, FL 32209, USA

*Corresponding author

Maedeh Ganji, MD

Cardiology Fellow, University of Florida, Jacksonville, FL 32209, USA; E-mail: Maedeh.ganji@jax.ufl.edu

Article information

Received: January 29th, 2020; Revised: February 6th, 2020; Accepted: February 10th, 2020; Published: February 20th, 2020

Cite this article

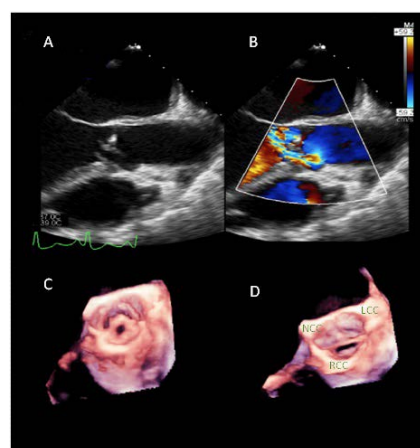
Ganji M, Ruiz J, Percy R, Missov E, Sattiraju S. Dynamic shape change of an aortic valve cusp perforation on 3D transesophageal echocardiogram. *Heart Res Open J.* 2020; 7(1): 1-2. doi: [10.17140/HROJ-7-152](https://doi.org/10.17140/HROJ-7-152)

CLINICAL INFORMATION

A 67-year-old male patient presented to emergency department with worsening altered mental status and fever. Computerized tomography (CT) of head found patient with multiple basal ganglia infarcts with high suspicion for septic emboli as sources for stroke. Blood cultures and lumbar puncture obtained and the patient was found to have *Streptococcus pneumoniae* meningitis. A two-dimensional (2D) transthoracic echocardiogram (TTE) demonstrated severe aortic regurgitation and flail leaflet with an ejection fraction of 70%. Cardiology and cardiothoracic surgery were consulted for the valvulopathy in conjunction with elevated troponins, bacteremia, and bacterial meningitis. A transesophageal echocardiogram (TEE) showed a perforation of the right coronary cusp resulting in severe aortic regurgitation (Figures 1A and 1B), a reversal of flow into the thoracic aorta due to the severe aortic regurgitation and reduction in ejection fraction from the time the TTE was performed. His hospital course was further complicated with new-onset of atrial fibrillation. Three-dimensional (3D) TEE provided an exceptional understanding of the changing size and shape of the perforation of the cusp with the cardiac cycle (Figures 1C and 1D). While there are methods to assess the regurgitant orifice area by the 2D echo to determine the severity of aortic regurgitation, the 3D data clearly shows that the regurgitant orifice is a highly dynamic structure with the change in shape and size influenced by systole and diastole. A perforated cusp is a major structural abnormality and carries with it severe regurgitation. While 3D imaging in our case may not have altered the management of the patient, it did enhance the understanding of the pathology from an imaging perspective and challenges the 2D echo-derived assumption of a fixed regurgitant orifice. The patient was placed on intravenous (IV) antibiotic therapy with good response with repeat negative

blood cultures. Patient was deemed high-risk for a surgical procedure but his risk of mortality remained high without aortic valve procedure. He subsequently underwent aortic valve replacement using a 23 mm mechanical valve, left atrial appendage closure and debridement of abscess found under the right coronary cusp. He had a difficult recovery post-operatively with weaning off the ventilator, but eventually improved.

Figure 1. A: 2D TEE of the Left Ventricular Outflow Tract View Showing Perforation of the Right Coronary Cusp; **B:** Severe, Eccentric, Anteriorly Directed Aortic Regurgitant Jet by Color Flow Interrogation; **C:** 3D TEE Image of the Short Axis View of the Aortic Valve with Perforation of the Right Coronary Cusp of the Aortic Valve During Systole. **D:** 3D TEE Image of the Short Axis View of the Aortic Valve with Perforation of the Right Coronary Cusp of the Aortic Valve During Diastole.



LCC-Left Coronary Cusp; RCC-Right Coronary Cusp; NCC-Non-Coronary Cusp; TEE-Transesophageal Echocardiogram

Echocardiography has been pivotal in the diagnosis of aortic valve pathology in our patients. Although perforation of a leaflet can be diagnosed by 2D echocardiogram, 3D echo enables the recognition of pathology more precisely with respect to location and extent. Indeed, 3D TEE has been reported to diagnose valvular perforations that could not be diagnosed using a 2D echo.¹ As 3D echo can obtain larger data sets, the relationship of pathology to surrounding structures is better visualized.² Cardiac CT or magnetic resonance imaging (MRI) could be used as modalities for identifying the cardiac pathology, but cannot be used as a real-time option in the operating room (OR). Transesophageal modality is the widely used modalities bedside as well as in OR to assess and help manage interventions in real-time.³

LEARNING POINTS

- Transthoracic echocardiogram and transesophageal echocardiogram are two modalities that are used in diagnosis and guidance of therapy in infective endocarditis.
- Transthoracic echocardiogram and transesophageal echocardiogram sensitivity based on meta-analysis depicts 62% and 92% respectively in detecting vegetation on native valves in case of endocarditis.⁴
- 3D TEE provides high spatial resolution due its close proximity to the cardiac structures.⁵

ACKNOWLEDGEMENT

The authors would like to acknowledge the contribution of sonographer Amanda Morley, RDCS.

CONSENT

The authors have received written informed consent from the patient.

CONFLICTS OF INTEREST

The authors declare that they have no conflicts of interest.

REFERENCES

1. Thompson KA, Shiota T, Tolstrup K, Gurudevan SV, Siegel RJ. Utility of three-dimensional transesophageal echocardiography in the diagnosis of valvular perforations. *Am J Cardiol.* 2011; 107(1): 100-102. doi: [10.1016/j.amjcard.2010.08.051](https://doi.org/10.1016/j.amjcard.2010.08.051)
2. Leja MJ, Shah DJ, Reardon MJ. Primary cardiac tumors. *Tex Heart Inst J.* 2011; 38(3): 261-262.
3. Eltzhig HK, Rosenberger P, Loffler M, Fox JA, Aranki SF, Sherman SK. Impact of intraoperative transesophageal echocardiography on surgical decisions in 12,566 patients undergoing cardiac surgery. *Ann Thorac Surg.* 2008; 85(3): 845-852. doi: [10.1016/j.athoracsur.2007.11.015](https://doi.org/10.1016/j.athoracsur.2007.11.015)
4. Shively BK, Gurule FT, Roldan CA, Leggett JH, Schiller NB. Diagnostic value of transesophageal compared with transthoracic echocardiography in infective endocarditis. *J Am Coll Cardiol.* 1991; 18(2): 391-397. doi: [10.1016/0735-1097\(91\)90591-v](https://doi.org/10.1016/0735-1097(91)90591-v)
5. Vegas A. Three-dimensional transesophageal echocardiography: Principles and clinical applications. *Ann Card Anesth.* 2016; 19(Suppl 1): S35-S43. doi: [10.4103/0971-9784.192622](https://doi.org/10.4103/0971-9784.192622)