

Original Research

Issues with the Use of the Extracortical Clamp Device in the Concurrent and Combined Use of External and Internal Femur Fixation

Leonid N. Solomin, MD, PhD^{1,2*}; Fanil K. Sabirov, MD, PhD¹; Matthew Fletcher, MD, PhD³; Arvid B. Abolin, MD, PhD²

¹Vreden Russian Research Institute of Traumatology and Orthopedics, St. Petersburg, Russia

²St. Petersburg State University, Medical Faculty, Department of General Surgery, St. Petersburg, Russia

³Dawson Creek and District Hospital, Dawson Creek, Canada

*Corresponding author

Leonid N. Solomin, MD, PhD

Vreden Russian Research Institute of Traumatology and Orthopedics, St. Petersburg, Russia; E-mail: solomin.leonid@gmail.com

Article information

Accepted: June 23rd, 2024; Published: July 13th, 2024

Cite this article

Solomin LN, Sabirov FK, Fletcher M, Abolin AB. Issues with the Use of the Extracortical Clamp Device in the Concurrent and Combined Use of External and Internal Femur Fixation. *Orthop Res Traumatol Open J.* 2024; 9(1): 20-25.

ABSTRACT

Aim

The Extracortical Clamp Device (ECD) is a novel external fixation component which unlike conventional implants does not perforate long bone cortices. Therefore, it simplifies methods of combined and consecutive internal and external fixation, periprosthetic fracture osteosynthesis and deformity correction. This study compared the incidence of complications with the use of the ECD in combined external fixation of the femur.

Methods

A prospective controlled study was designed with one group including 66 frames assembled using the ECD. These were compared with the second group of 29 frames utilising a combination of external and internal fixation, the latter comprising conventional wires and pins only.

Results

In the ECD group, pin tract infection was identified in 14.8% of cases. In these patients, infection occurred in 45.5% of all fixation elements; of these, 18.2% occurred around the ECD. In the WP (only wired and pins) group pin tract infection occurred in 29.2% cases. ECD fracture occurred in one case (3.7%). In the WP group, transosseous element breakage occurred in 3 cases (13.6%). In the treatment of periprosthetic fractures and deformities using the ECD, pin tract infection was seen in 16.7%. In the treatment of similar fractures and deformities not associated with an endoprosthesis, pin tract infections were seen in 21.5% of cases.

Conclusion

In this study we have demonstrated that the ECD does not increase the number of complications specific to external fixation. All resultant complications applicable to the ECD were addressed by conservative measures, and did not affect the outcome. The use of the ECD eliminates complications and concerns in combined osteosynthesis such as obstruction and jamming of an intramedullary device; fretting wear due to contact with half pins or wires and endoprosthesis; loss of torsional control as seen not uncommonly with half pins; the reduction in frame stability due to the use of smaller pins; and the risk of pin or wire cut-out due to eccentric placement.

Keywords

Extracortical clamp device (ECD); External fixation; Complications; Defects; Deformities; Lengthening over nail (LON); Bone transport over nail (BTON).

Abbreviations

ECD: Extracortical Clamp Device; LON: Lengthening Over Nail; BTON: Bone Transport Over Nail; SEFaN: Sequential External Fixation and Nailing; EFAN: External Fixation Assisted Nailing.


INTRODUCTION

Combining the advantages of external fixation and locking nailing can reduce the risk of complications, increase the comfort of treatment for the patient in the treatment of fractures, correction of varying complexity deformations, and reconstruction of segmental defects in long bones.¹⁻⁴ There are 4 accepted groups of techniques that combine external fixation and nailing:

1. External Fixation Assisted Nailing in the treatment of fractures and correction of deformities of long bones – EFAN
2. Sequential External Fixation and Nailing – SEFaN
3. Lengthening Over Nail – LON
4. Bone Transport Over Nail – BTON

A critical step in the execution of these techniques is to insert the transosseous elements in such a way as to exclude their contact with the intramedullary device. One way to address this is to eccentrically place the wires and pins. This is technically difficult, and risks the transosseous elements cutting out. The use of smaller diameter pins reduces the rigidity of osteosynthesis. The possible deflection of a transosseous element by the intramedullary device increases the risk of inadvertent trauma to regional neurovascular structures. Most frequently these difficulties are observed in femoral osteosynthesis.⁵⁻⁷

The extracortical clamp device (ECD) was developed by the Vreden Russian Research Institute of Traumatology and Orthopedics as a solution to these problems. The ECD allows the capture of bone segments by external fixation frames despite the presence of large intramedullary foreign bodies i.e. an intramedullary nail or endoprosthesis (Figure 1).



Biomechanical studies have shown that the use of the ECD increases the rigidity of fixation of the bone fragment by modules of the first and second orders. The first order module provides the greatest rigidity of osteosynthesis when two ECDs are inserted at a distance of 50 mm at an angle of 60 degrees with respect to each other. Even greater stiffness is generated when the ECD is introduced at a distance of 100 mm and fixed to two circumferential rings (M2).⁸

The ECD is thus a tool to simplify EFAN, SEFaN, LON and BTON techniques and reduce the risk of complications. The use of the ECD thus eliminates the problems and risks associated with the conflict between transosseous elements and the intraosseous device.

As previously mentioned, the stability of osteosynthesis with the use of the ECD has been proved experimentally. However, the ECD has significant design differences compared to standard half-pins. Firstly, the diameter is larger at 8 mm (half-pins for osteosynthesis of the femur are typically 5-6 mm), and therefore the soft tissue approach is somewhat larger. To insert the ECD, an incision of up to 4 cm is required, not the usual 6 mm incision puncture, which is used for half-pins. The construct of the ECD can be envisioned as a cannula – there is a potential space between the central pin and the hub of the ECD. These three considerations potentially increase the risk of infectious complications.⁸

Secondly, for osteosynthesis solid linear half-pins are traditionally used. The ECD construct design does generate a stress riser at the junction of the clamp and the hub. These design aspects potentially increase the risk of fracture of ECD.⁹

Whilst other parameters that are observed in external fixation (fixation index, osteosynthesis index, deformation correction accuracy, elongation or replaceable defect length, the appearance of contractures, etc.) are undoubtedly important, these are frequently specific to different modalities of frame treatment. Therefore, the inclusion criteria for enrollment in the study included the consideration that the clinical group used for comparison (using only traditional transosseous elements) should have a similar duration of the fixation period in the frame, the timing of correction, and identical pathology.

The following study was designed to determine whether use of the ECD was associated with an increased frequency or the severity of soft tissue inflammation/pint track infection or component fracture complications in the femur.

MATERIALS AND METHODS

This study was approved by the Institution Review Board. The study was a prospective controlled. The first study cohort utilizing the ECD consisted of 66 patients ECD. The second comprised 29 patients using traditional K-wires and half-pins (WP) (Table 1).

Method	ECD	WP
EFAN	22 (33.3%)	7 (24.1%)
SEFaN	9 (13.6%)	10 (34.5%)
LON	13 (19.7%)	9 (31.0%)
BTON	5 (7.6%)	3 (10.4%)
Periprosthetic fracture osteosynthesis	6 (9.1%)	-
Correction of periprosthetic deformity	6 (9.1%)	-
Other	5 (7.6%)	-
Total	66 (100%)	29 (100%)

The ‘other’ method included 2 cases of femoral fixation in canal osteomyelitis and 3 cases of knee contracture distraction with an intramedullary device *in situ*.

To permit statistical analysis of the data, the number of

patients in the subgroups of SEFaN, LON and BTON was combined. As seen in Table 2, these two subgroups were comparable in the most critical parameters of external fixation, and, consequently, deemed analogous.

For the compared parameters the statistical lack of significance ($p>0.05$), indicating the data of the group was not comparatively different.

In the patient 27 of the ECD group, defect osteogenesis above the nail was performed in several stages without frame revision over a 22 month period. There was no similar fixation period in the control group. Therefore, this case was not considered in Table 2, but is included in the analysis of complications and is presented as a clinical example.

In treating periprosthetic deformations and fractures, sole use of only traditional transosseous elements was not performed. Therefore, for comparison, we used data from a similar study of femoral fractures and deformation in the absence of a femoral endoprosthesis.^{10,11} The inclusion criteria were identical to the duration of frame fixation.

Statistical analysis was carried out using the STATISTICA 10. The criterion for the statistical reliability of the difference was deemed to be $p<0.05$.

RESULTS AND DISCUSSION

Table 3 presents the summarized complications for both “combined” and “sequential” techniques.

In both groups, the most common complication was infection around ECD, K-wires, half-pins. It should be noted that of the 4 occurrences in the ECD group, infection arose in a total of four extracortical fixators and in six traditional transosseous elements. In the WP group, infection occurred in a total of seven traditional transosseous elements. Thus, in the ECD group, 45.5% of all fixation elements used in the frame had an infection; of these 18.2% were accounted for by the ECD. In the WP group, 29.2% of all fixation elements used in the assembly had an infection. The ratio of the total number of transosseous elements in the ECD and WP groups was 1:1.2, respectively. Thus, infection of the ECD tracts did not exceed the number of occurrences of pin tract infection using traditional transosseous elements and does not differ significantly when using only traditional transosseous elements ($p>0.05$).

In all cases the infection was superficial, it settled with conservative management, and did not affect the outcome. The literature confirms that pin tract infection in traditional transosseous osteosynthesis ranges from 8.2% to 96%,¹²⁻¹⁶ and with combined osteosynthesis ranges from 7% to 38%.^{1,2,6}

Table 2. Parameters of Transosseous Osteosynthesis

Index	Group ECD (26 cases*)	Group WP (22 cases)	p
Lengthening (cm)	4.23±1.56	3.89±1.76	0.64
Lengthening time with LON (days)	51.69±23.8	46.44±22.15	0.61
Index of elongation (days/cm)	11.91±2.39	12.07±1.6	0.86
Duration of fixation in LON (days)	77.38±46.14	78.44±51.46	0.96
External Fixation Index in LON, (days/cm)	17.37±6.3	19.16±5.5	0.5
Defect length (cm)	6.63±0.95	6.0	0.42
Lengthening time with BTON (days)	108.75±26.74	115.0±14.38	0.67
Index of elongation (days/cm)	16.27±1.85	19.17±4.6	0.19
Duration of fixation in BTON (days)	126±29.79	148.33±31.79	.58
External Fixation Index in BTON (days/cm)	18.85±1.91	24.72±5.3	0.21

Table 3. The Frequency of Complications Sharing External and Internal Fixation

Complication	Group ECD	Group WP
ECD/ transosseous element infection	4 (14.8%)	4 (18.2%)
Instability of the ECD or transosseous element	1 (3.7%)	-
Fracture of the ECD or transosseous element	1 (3.7%)	3 (13.7%)
Interference/obstruction of the intramedullary device	1 (3.7%)	2 (9.1%)
Neuropathy	3 (11.1%)	1 (4.5%)
Contracture of the knee joint	2 (7.4%)	1 (4.5%)
Without complications	15 (55.6%)	11 (50%)
Total complications	12 (44.4%)	11 (50%)

Loosening of one ECD by the end of the period of distraction (121 days after the operation) did not coincide with infection and did not affect the outcome. A possible cause for this was the patient's non-compliance with the management protocol. However, the ECD migrated into a somewhat angular position and did not completely lose its stability.

Fracture of the ECD at the junction of the clamp and hub occurred in one case when the frame was removed; this ECD had remained *in situ* for 22 months. There were no fractures of traditional transosseous elements in the ECD group. In the WP group there were 3 occurrences of fracture of half-pins; in one case, a replacement transosseous element was required. We did not find an increased incidence of implant fracture with use of the ECD when compared to traditional transosseous elements.

Other complications that occurred during treatment of both groups of patients, in our opinion, were not directly related to the use of specific fixation elements. Capture and obstruction of an intramedullary nail during distraction arose once in each group. In the ECD group this was due to the requirement, in addition to lengthening, to also eliminate the torsional component of deformation. In the WP group this occurred during attempts to lengthen the femur over an existing nail, without additional reaming of the medullary canal.

The development of sciatic nerve neuropathy (2 cases in the ECD group, 1 case in the WP group) was not associated with the use of fixation elements; all elements were inserted according to the recommended positions for transosseous element placement.⁶ The same can be said for contractures of the knee joint (2 in the ECD group, 2 in the WP group).

In the treatment of periprosthetic fractures (ECD-P), of the 2 clinical observations of pin tract inflammation, these appeared in 2 ECD and 3 half-pins (20.0%). Thus, the ECD group had an infection of 33.3% of all the fixation element tracts (15 elements in total); of these, the ECD accounted for 13.3%. In the treatment of a similar pathology without the presence of an endoprosthesis (WP-P)^{1,5} pin tract complications were diagnosed in 21.5% of cases. In total, 18.7% of fixation elements were affected. The remaining complications, such as sciatic neuropathy (8.3% in ECD-P and 1.9% in WP-P) and knee joint contractures (0% in ECD-P and 11.5% in WP-P) did not depend on the use of external fixation elements.

Clinical Example

Patient B., aged 23, was treated 12 years previously with a tumor prosthesis of the left knee for osteosarcoma. Further revision surgeries occurred at intervals of one, two, and nine years post-operatively. The last prosthetic lengthening was complicated by deep infection.

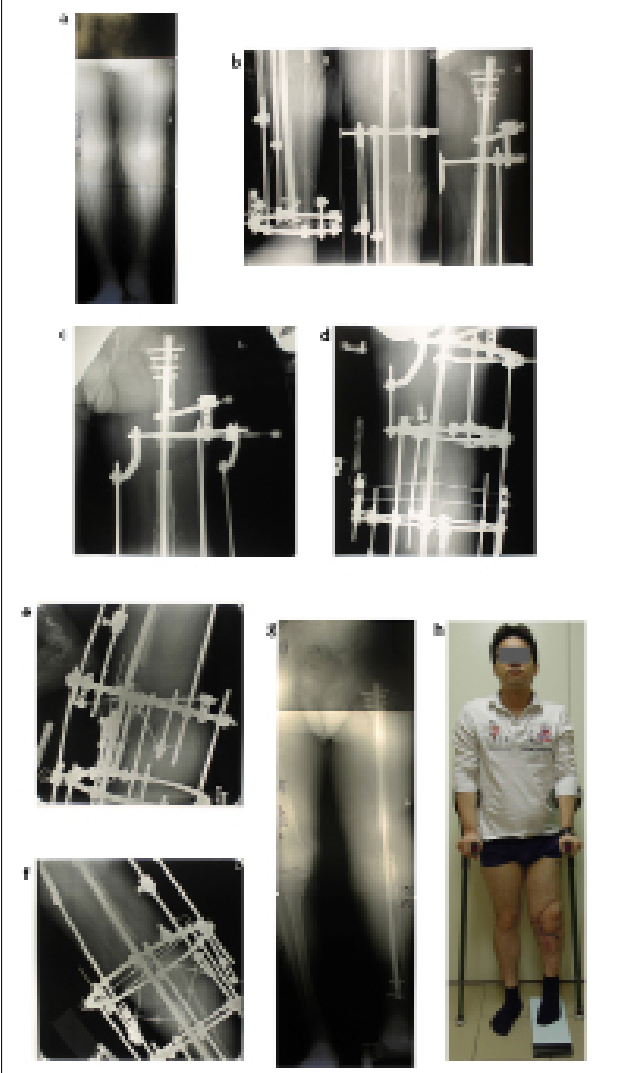
The prosthesis had been removed and a non-articulating spacer inserted. One year following this, the spacer was removed, the cavity debrided and a new spacer reinserted (Figure 2a).

Subsequently, the spacer was explanted, intramedullary osteosynthesis of the left femur and tibia was performed with an extended nail, a circular frame applied and osteotomy of the femur performed. 2 ECD constructs were used in the frame configuration (Figure 2b).

Post-operative bifocal lengthening/transport commenced at day 7 over the upper nail at a rate of 1 mm per day. Distraction was discontinued at 3 months after achieving a 7 cm distraction gap (Figure 2c).

Five months following initial distraction the frame was revised, with a distal tibial and further femoral osteotomy and element replacement. Distraction in the femur at a rate of 1 mm per day and in the tibia at a rate of 1.25 mm per day commenced at day 7 (Figure 2d).

Figure 2. Clinical Use of the ECD Using the BTON Technique: A – Long-leg Radiograph Demonstrating Defect and Shortening; b – First Post-operative Radiograph (ECDs Indicated by Arrows); c - Radiographs During the Distraction ; d - Radiographs Following Stabilization of Transport Segment, the Second Osteotomy; e, f - Radiographs Prior to Frame Removal and Osteosynthesis; g, h – Final Radiographs and Clinical Photograph After Frame Removal



Two months subsequently distraction was halted due to the inadequate regenerate formation. Further frame revision and the osteotomy was performed. Post-operatively bifocal lengthening/transport recommenced at 1 mm per day (Figure 2e and 2f).

Two months subsequently the frame was removed, the nail locked, and the approximated distal femur and proximal tibia compressed (Figure 2g and 2h).

Total frame time was 655 days. Active lengthening represented 217 days. The total amount of length obtained was 25 cm. The residual 6 cm shortening was addressed by a further procedure.

CONCLUSION

This study confirms that the use of the ECD significantly increases the facility of performing complex and routine surgery where traditional transosseous osteosynthesis is problematic or impossible. Other studies have confirmed the utility of the ECD in periprosthetic fracture and deformity management.¹⁷ Furthermore, concerns regarding an increase in pin tract complications do not appear more frequent despite the larger insertion incision, and that the risk of ECD fracture is not increased over that of traditional transosseous elements.

The use of the ECD eliminates complications of, and concerns in combined osteosynthesis such as obstruction and jamming of an intramedullary device; fretting wear due to contact of half pins or wires and endoprotheses; loss of torsional control as seen not uncommonly with half pins; the reduction in frame stability due to the use of smaller pins; and the risk of pin or wire cut-out due to eccentric placement.

In this study, we have demonstrated that the ECD does not increase the number of complications specific to external fixation. All resultant complications applicable to the ECD were addressed by conservative measures, and did not affect the outcome.

CONFLICTS OF INTEREST

Professor Solomin holds intellectual property rights for the ECD, has a financial interest in a company which distributes the device, and acts as a consultant to Pitkar Orthotools. The other authors declare no potential conflicts of interest.

CONSENT

The authors have received written informed consent from the patient.

REFERENCES

1. Chelnokov AN, Vinogradskiy AE, Shlykov IL, Stelmah KK, Kim AP. The method of closed intramedullary nailing of the femur [In Russian]. 2005; *GFUN UNIITO im. 2003125921/14*. Byul. № 28.

2. Solomin LN. Basic principles of external fixation T2./M; 2015: 560.

3. Herzenberg JE, Paley D. Tibial lengthening over nails (LON). *Tech Orthop*. 1997; 12: 250-259.

4. Paley D, Herzenberg JE, Paremain G, Bhave A. Femoral lengthening over an intramedullary nail. A case-matched comparison with Ilizarov femoral lengthening. *J Bone Joint Surg Am*. 1997; 79: 1464-1480.

5. Herzenberg JE, Santpure S, Paley D. Femoral lengthening in patients with achondroplasia. Paper presented at: American Academy of Orthopaedic Surgeons (AAOS), 70 Annual Meeting Proceedings; 2003; New Orleans, LA, USA: 624-625.

6. Kocaoglu M, Eralp L, Kilicoglu O, Cakmak HBM. Complications encountered during lengthening over an intramedullary nail. *J Bone Joint Surg Am*. 2004; 86: 2406-2411.

7. Kocaoglu M, Eralp L, Bilen FE, Balci HI. Fixator-assisted acute femoral deformity correction and consecutive lengthening over an intramedullary nail. *J Bone Joint Surg*. 2009; (91-A, 1): 152-159. doi: [10.2106/JBJS.H.00114](https://doi.org/10.2106/JBJS.H.00114)

8. Sabirov FK, Solomin LN. Investigation of rigidity of first-order and second-order modules, assembled with use of extracortical clamp devices. *Orthopedics and Traumatology of Russia*. 2015; (1): 58-65.

9. Solomin LN, Sabirov F, Fletcher MDA. Investigation of the mechanical rigidity of first and second order modules assembled using the Extracortical Clamp Device. *Nov Tech Arthritis Bone Res*. 2017; 1(5): NTAB.MS.ID.555575. doi: [10.19080/NTAB.2017.01.555575](https://doi.org/10.19080/NTAB.2017.01.555575)

10. Solomin LN, Shchepkina EA, Vilensky VA, Skomoroshko PV, Tulyaev NV. Correction of femur deformities by ilizarov method and by apparatus «Ortho-SUV» based on computer navigation [In Russian]. *Orthopedics and Traumatology of Russia*. 2011; 3: 32-39. doi: [10.21823/2311-2905-2011-0-3-32-39](https://doi.org/10.21823/2311-2905-2011-0-3-32-39)

11. Andrianov M. The combined external fixation in diaphyseal fractures and their consequences/SPb.: Vreden Russian Research Institute of Traumatology and Orthopedics; 2007.

12. Popkov DA, Popkov AV, Danil'chenko GV, Aborin SA. Current state of operational femoral lengthening (literature review) [In Russian]. *Genius of Orthopedics*. 1999; 3: 105-110.

13. Solomin LN. *The Basic Principles of External Skeletal Fixation using the Ilizarov and Other Devices*. Milano MI, Italy; Springer-Verlag Mairland. 2013: pp 328.

14. Shevtzov VI, Popkov AV, Popkov DA. Complications of femoral elongation in the high-divisional automatic mode [In Russian]. *Genius of Orthopedics*. 1997; 4: 24-28.

15. Dahl MT, Gulli B, Berg T. Complications of limb lengthening. A learning curve. *Clin Orthop Relat Res.* 1994; 301: 10-18.
16. Hasler CC, Krieg AH. Current concepts of leg lengthening. *J Child Orthop.* 2012; 6(2): 89-104. doi: [10.1007/s11832-012-0391-5](https://doi.org/10.1007/s11832-012-0391-5)
17. Fletcher MDA, Sabirov F, Vilensky V, Solomin LN. Use of the extracortical clamp device in the treatment of periprosthetic femoral fractures and deformities. Paper presented at: 11th Congress of the European Hip Society; 2014; Stockholm, Sweden.