

## Case Report

# A Special Fracture in Diagnosis and Treatment: Lateral Tibial Plateau with Peroneal Nerve Entrapment

Palak Walia, BS; Amna Diwan, MD\*

Department of Orthopedics and Physical Rehabilitation, University of Massachusetts Medical School, 55 N Lake Avenue, Worcester, MA 01655, USA

\*Corresponding author

Amna Diwan, MD

Assistant Professor, Department of Orthopedics and Physical Rehabilitation, University of Massachusetts Medical School, 55 N Lake Avenue, Worcester, MA 01655, USA; Tel. 508-334-0600; Fax. 508-334-3408; E-mail: [Amna.Diwan@umassmemorial.org](mailto:Amna.Diwan@umassmemorial.org)

Article information

Accepted: July 2<sup>nd</sup>, 2025; Published: July 8<sup>th</sup>, 2025

Cite this article

Walia P, Diwan A. A Special Fracture in Diagnosis and Treatment: Lateral Tibial Plateau with Peroneal Nerve Entrapment. *Orthop Res Traumatol Open J.* 2025; 10(1): 17-20.

### ABSTRACT

A majority of tibial plateau fractures involve the lateral plateau. Posterolateral tibial plateau fractures are caused by a valgus force that impacts the posterolateral plateau against the lateral femoral condyle. We describe a unique case of a patient who sustained a lateral plateau fracture with posterior displacement behind a fractured fibular head, with entrapment of the peroneal nerve. This unusual fracture pattern required dual anterolateral and lateral approach for reduction and fixation.

#### Keywords

Tibial plateau; High energy; Fracture; Peroneal nerve entrapment.

### INTRODUCTION

Tibial plateau fractures account for 1-2% of all fractures and are caused by a valgus or varus force and axial loading at the knee.<sup>1</sup> The varying direction and magnitude of forces applied and pre-existing quality of patient's bones results in a wide spectrum of fracture patterns.<sup>2</sup> Hohl et al<sup>3</sup> reported that 55-70% of tibial plateau fractures involve the lateral plateau and about 7% involve the posterolateral tibial plateau.

Tibial plateau fractures are classified by either the more complex and precise Arbeitsgemeinschaft für Osteosynthesefragen/Orthopaedic Trauma Association (AO/OTA) system or the more reproducible and reliable Schatzker method.<sup>4,6</sup> For the AO/OTA system, the proximal tibia is coded as a 41 with further subgroupings based on intra-articular fractures with B1-3 for partial and C1-3 for complete involvement.<sup>6</sup> The Schatzker method divides tibial plateau fractures into 6 types: 1) split fracture of the lateral plateau; 2) split depression of the lateral plateau; 3) central depression of the lateral plateau; 4) split of the medial tibial plateau; 5) bicondylar tibial plateau fracture OR; 6) tibial plateau fracture with dissociation between the metaphysis and diaphysis.<sup>6</sup>

Surgical management is indicated if articular step-off is greater than 3 mm, condylar widening is greater than 5 mm, there

is greater than 5° of coronal alignment disruption, or there is instability to varus and valgus stress of the knee joint with the leg in extension.<sup>7</sup>

This report describes a unique injury pattern of a right unicondylar lateral plateau fracture with dislocation and subsequent relocation of the fibular head, resulting in a large shear fragment of the plateau behind the spontaneously relocated fibular head, with entrapment of an intact peroneal nerve.

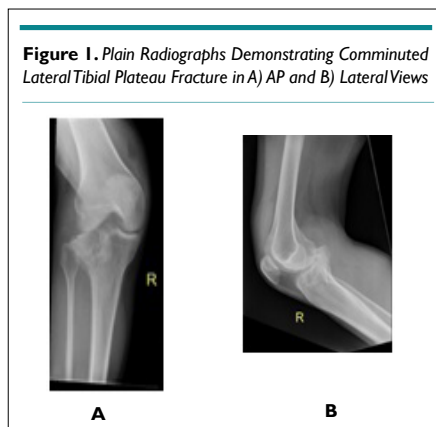
### CASE REPORT

The patient is a 38-year-old female with a past medical history significant for IV drug use, cocaine use, hepatitis C, bipolar disorder, anxiety and depression who presented post high-energy motor vehicle accident (MVA) accident, sustaining many injuries. She was an unrestrained driver driving 100 mph, drove through a ditch, and was launched into the woods 30-40 feet into a tree. It is unknown if she lost consciousness or if she was intoxicated while driving. She was brought by ambulance to an outside hospital, where imaging was done on bilateral lower extremities, her bilateral ankles reduced and splinted and then transferred to an academic level one trauma hospital for further care. A healthcare proxy was unable to be discerned as her immediate family had all passed away, she was estranged from her extended family, and the patient was unable to

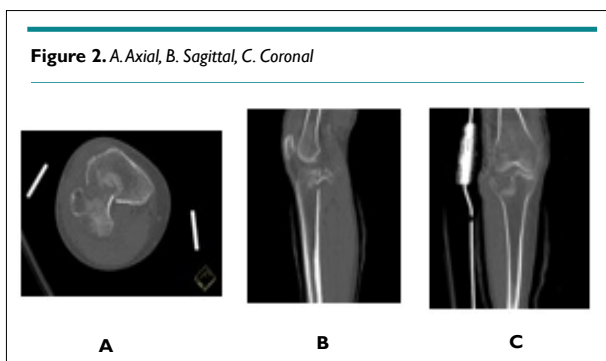
verify if she had a spouse.

On physical examination, she appeared intoxicated with slurred speech and lethargy with waxing and waning arousability. All her injuries were closed. She refused to cooperate with the motor examination but no foot drop observed. Bilateral lower extremities had sensation intact to light touch. There was an obvious valgus deformity of the right knee with gross instability to valgus stress testing, intact to varus stress testing. She had bilateral ankle swelling and deformities but intact distal pulses, motor, and sensation. Her dorsalis pedis pulses were not palpable but were dopperable bilaterally. Her toes were warm and well-perfused.

Right leg X-rays (Figure 1) showed a comminuted lateral tibial plateau fracture, and fractures of the medial and lateral malleoli. Computerized tomography (CT) further, elucidating that the lateral tibial plateau fracture has posterior displacement and angulation of the tibial articular surface fracture fragment which abutted the popliteal neurovascular bundle (Figure 2).



**Figure 1.** Plain Radiographs Demonstrating Comminuted Lateral Tibial Plateau Fracture in A) AP and B) Lateral Views



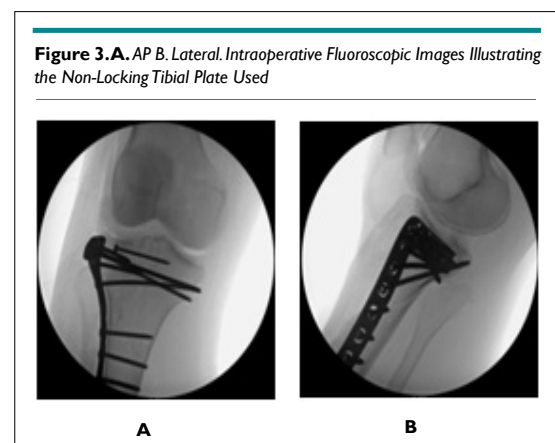
**Figure 2.** A. Axial, B. Sagittal, C. Coronal

Computerized tomography views demonstrating lateral tibial plateau fracture with posterior displacement and angulation of the tibial articular surface fracture fragment, abutting the popliteal neurovascular bundle.

In the emergency department (ED), the orthopedic team placed right tibia in a splint. Due to her young age and unique fracture pattern of her right lateral tibial plateau, her treatment plan was surgery. However, two days after admission, the psychiatry team placed her on a Section 12 and stated that she lacked capacity to consent to surgery. She was closely monitored in the hospital and four days after admission was able to go to the oper-

ating room.

She was taken to the OR and under general anesthesia, her ankle and foot fractures were treated operatively, as well as her tibial plateau. To fix the tibial plateau, an incision was made anterior or laterally. A laminar spreader was used to open the anterior fracture site to bring the fibular head and the intact common peroneal nerve in view. The nerve was behind the fibular head, displaced into the fracture plane. The large posterior lateral shear fragment of the tibial plateau was behind the fibular head. A laminar spreader and femoral distractor were used to dislocate the fibular head and obtain length. Then, a large kidney clamp was placed behind the lateral fragment of the plateau and it was pulled back into the joint. A Schanz pin was placed into this lateral fragment to help rotate the fragment into the joint. A Cobb was used to elevate additional fragments of the articular surface. K wires were placed to hold everything together. Once intra-operative imaging confirmed reduction, a non-locking tibial plateau plate was secured in buttress mode to capture this posterior lateral fragment and secure it distally. The axilla of the fracture was captured with the plate, followed by screws proximally to add additional stable fixation (Figure 3). The wound was irrigated and closed in a layered fashion with a combination of Vicryl and clips.



**Figure 3.** A. AP B. Lateral. Intraoperative Fluoroscopic Images Illustrating the Non-Locking Tibial Plate Used

She was stable post-operatively and was non weight bearing bilaterally, with hinged knee brace on the right locked in extension to allow for soft tissue rest with plan for motion through the knee joint once the wound settled/sutures were removed. Physical therapy and occupational therapy evaluated her and recommended inpatient rehabilitation or home with 24-hour assistance. Day one post-operative, as psychiatry removed her Section 12, she left the hospital against medical advice and she was lost to follow-up thereafter.

## DISCUSSION

Posterolateral tibial plateau fractures are caused by a valgus force with the knee in flexion, that leads to a shearing force between the lateral femoral condyle and the posterolateral plateau.<sup>8</sup> Without surgical fixation, the fracture fragment will tend to move posteriorly and distally with knee motion, creating joint instability, pain, and neurovascular injury.<sup>9</sup> As the conventional Schatzker classification system doesn't account for posterior tibial plateau fractures, dif-

ferent classification systems have been proposed, one including a three-column classification,<sup>10</sup> and one system developed by Hongwei et al<sup>11</sup> that classified posterolateral tibial plateau fractures by combining with CT reconstruction of the three dimensional (3D) images.<sup>11</sup>

While there is diversity in treatment options for posterolateral tibial plateau fractures, there are no definite treatment guidelines or algorithms in place. Rossman et al<sup>12</sup> retrospectively analyzed 538 tibial plateau fractures fixed from 2012-2015 and found that fracture patterns could not reliably predict the choice of surgical approach, but rather relied on the surgeon's experience, education, and preference. Cho et al<sup>13</sup> proposed an algorithm for treating posterolateral tibial plateau fractures, advising certain surgical approaches based on injury type of either isolated posterolateral fragment (PLF), PLF with associated anterolateral plateau fracture, PLF with posterior shearing fracture, and PLF with bicolunar plateau fracture.

Our patient had a unique fracture with posterior displacement of the fractured lateral tibial plateau behind a fractured fibular head. Asprinio et al<sup>14</sup> described a similar case, where they used a direct posterior popliteal approach with buttress-plate fixation of the posterolateral fracture and a lateral approach to reduce the fracture, bone-grafting, and buttress-plate fixation of the lateral tibial plateau. Our case differs slightly in that the "posterior lateral" fragment involves essentially the entire lateral tibial plateau with the fibular head anterior to it. Performing a direct posterior approach would be difficult as the fibular head would not be visualized and as such the block to reduction would not be able to be manipulated. An anterior approach would allow access to the fibular head, and with gentle anterolateral traction on the fibular head and a pull from posterior to anterior on the fractured tibial plateau fragment, we suspected that the fracture would reduce. This was essentially the case. The peroneal nerve was identified around the fibular head and entrapped between the fibular head and the tibial plateau posterior to it. A small sharp-sharp clamp was placed on the fibular head, and the head was pulled laterally, essentially out of the plane of the fracture. We then placed a long kidney clamp behind the dislocated anterolateral tibial plateau and hooked it, once it was securely hooked it was pulled in to place. The fibular head was then released and as the fibular head took its normal anatomic location it prevented further displacement of the fracture. We were then able to place a plate in buttress mode to secure the plateau.

## CONCLUSION

Tibial plateau fractures with a displaced posterior fragment need special attention in diagnosis and management. These fracture patterns may not fit in previous classification systems. This unique fracture pattern was successfully fixed as outlined in this case report.

## CONSENT

Written and verbal consent were unable to be obtained from the patient to reproduce information and photographs appearing in this article despite multiple attempts as the patient left against med-

ical advice from the hospitalization and has been lost to follow-up since, with no healthcare proxy. Authors confirm that the submitted article is neither under consideration nor published previously.

## CONFLICTS OF INTEREST

The authors declare that they have no conflicts of interest.

## REFERENCES

- Jacofsky DJ, Haidukerwych GJ. Tibia plateau fractures. In: Scott WN, ed. *Insall and Scott Surgery of the Knee*. Philadelphia, PA: Churchill Livingstone; 2006; 1133-1146.
- Stevenson I, McMillan TE, Baliga S, Schemitsch EH. Primary and secondary total knee arthroplasty for tibial plateau fractures. *J Am Acad Orthop Surg*. 2018; 26(11): 386-395. doi: [10.5435/JAAOS-D-16-00565](https://doi.org/10.5435/JAAOS-D-16-00565)
- Frosh KH, Balcarek P, Walde T, Sturmer KM. A new posterolateral approach without fibula osteotomy for the treatment of tibial plateau fractures. *J Orthop Trauma*. 2010; 24(8): 515-520. doi: [10.1097/BOT.0b013e3181e5e17d](https://doi.org/10.1097/BOT.0b013e3181e5e17d)
- Müller ME, Nazarian S, Koch P, Schatzker J. *The Comprehensive Classification of Fractures of Long Bones*. New York, NY, USA: Springer; 1990: 148-156.
- Schatzker J, McBroom R, Bruce D: The tibial plateau fracture: The toronto experience 1968--1975. *Clin Orthop Relat Res*. 1979; 138: 94-104.
- Maripuri SN, Rao P, Manoj-Thomas A, Mohanty K. The classification systems for tibial plateau fractures: How reliable are they? *Injury*. 2008; 39(10): 216-222. doi: [10.1016/j.injury.2008.01.023](https://doi.org/10.1016/j.injury.2008.01.023)
- Honkonen SE. Indications for surgical treatment of tibial condyle fractures. *Clin Orthop Relat Res*. 1994; 302: 199-205.
- Zhang W, Luo CF, Putnis S, Sun H, Zeng ZM, Zeng BF. Biomechanical analysis of four different fixations for the posterolateral shearing tibial plateau fracture. *Knee*. 2012; 19(2): 94-98. doi: [10.1016/j.knee.2011.02.004](https://doi.org/10.1016/j.knee.2011.02.004)
- Waldrop JI, Macey TI, Trettin JC, Bourgeois WR, Hughston JC. Fractures of the posterolateral tibial plateau. *Am J Sports Med*. 1988; 16(5): 492-498. doi: [10.1177/036354658801600511](https://doi.org/10.1177/036354658801600511)
- Luo CF, Sun H, Zhang B, Zeng BF. Three-column fixation for complex tibial plateau fractures. *J Orthop Trauma*. 2010; 24(11): 683-692. doi: [10.1097/BOT.0b013e3181d436f3](https://doi.org/10.1097/BOT.0b013e3181d436f3)
- Hongwei C, Gang-sheng Z, Wang Z-y, Pan J, Wu L-j, Xu B, et al. Computed tomographic classification of posterior condylar tibial plateau fractures. *Natl Med J China*. 2011; 91(3): 180-184.
- Rossmann M, Fensky F, Ozga AK, Rueger JM, Märdian S, Rus-

sow G, et al. Tibial plateau fracture: Does fracture classification influence the choice of surgical approach? A retrospective multicenter analysis. *Eur J Trauma Emerg Surg.* 2020. doi: [10.1007/s00068-020-01388-z](https://doi.org/10.1007/s00068-020-01388-z)

13. Cho JW, Kim J, Cho WT, Kim J-K, Samal P, Gujjar PH, et al. Approaches and fixation of the posterolateral fracture fragment in

tibial plateau fractures: A review with an emphasis on rim plating via modified anterolateral approach. *Int Orthop.* 2017; 41(9): 1887-1897. doi: [10.1007/s00264-017-3563-6](https://doi.org/10.1007/s00264-017-3563-6)

14. Asprinio DE, Issack PS. Lateral tibial plateau fracture with posterolateral fragment and fibular head entrapment: A case report. *JBJS Case Connector.* 2012; 2(4): e55. doi: [10.2106/JBJS.CCL.00040](https://doi.org/10.2106/JBJS.CCL.00040)