

Original Research

Balloon Kyphoplasty: Cement Augmentation in Acute Osteoporotic Thoraco-Lumbar Fractures

Abdulrazzaq Alobaid, MD, FRCSC^{1*}; Abdulaziz Al-Mutair, BHSc, MBChB, FRCSC²; Islam Elsayed, BCH³; Elsayed Mahgoub, MD⁴; Abdullah Al-Shatti, RCSI-MUB⁵

¹Orthopedic Spine Surgeon, Chief of Spine Surgery Unit, Alrazi Hospital, Kuwait

²Orthopedic Spine Surgeon, Division of Spine Surgery, Alrazi Hospital, Kuwait

³Orthopedic Registrar, Division of Spine Surgery, Alrazi Hospital, Kuwait

⁴Orthopedic Surgeon, Division of Spine Surgery, Alrazi Hospital, Kuwait

⁵School of Medicine, Bahrain

*Corresponding author

Abdulrazzaq Alobaid, MD, FRCSC

Orthopedic Spine Surgeon, Chief of Spine Surgery Unit, Alrazi Hospital, P.O. Box 1160, Surra 45172, Kuwait; Tel. (+965) 60606216; E-mail: dralobaid@hotmail.com

Article information

Received: May 3rd, 2017; Accepted: May 30th, 2017; Published: June 21st, 2017

Cite this article

Alobaid A, Al-Mutair A, Elsayed I, Mahgoub E, Al-Shatti A. Balloon kyphoplasty: Cement augmentation in acute osteoporotic thoraco-lumbar fractures. *Orthop Res Traumatol Open J.* 2017; 3(1): 1-19. doi: [10.17140/ORTOJ-3-111](https://doi.org/10.17140/ORTOJ-3-111)

ABSTRACT

Background

Several techniques have been developed for simpler and safer procedures during the last 2 decades. Techniques of vertebral body augmentation have been developed in an effort to treat these refractory cases. The injection of low-viscosity poly-methylmethacrylate (PMMA) under high pressure poses a potential risk for neural compromise and pulmonary embolism by uncontrolled leakage. Therefore, balloon kyphoplasty and vertebroplasty using a large cannula low pressure injection of PMMA in a high-viscosity state has been introduced. Percutaneous kyphoplasty (PKP) is a recently developed, minimally invasive surgical approach for the treatment of osteoporotic vertebral compression fractures (OVCF).

Objective

Our objective is directed towards the study of the role of kyphoplasty in the management of osteoporotic thoracolumbar fractures, following the analysis of clinical and radiographic outcomes. Our objective is to evaluate the efficacy and safety of kyphoplasty in the treatment of acute vertebral osteoporotic compression fractures and to validate the hypothesis that kyphoplasty will help diminish pain, disability and improve the quality of life (QoL). The goal of this study was to determine the safety and effectiveness of kyphoplasty in improving vertebral body height, decreasing pain, and improving affected functions.

Patients and Methods

A prospective analysis of 30 patients (10 males and 20 females), being treated with kyphoplasty, was performed at our institution, after a clinical follow-up of 6 months. The patients had vertebral compression fractures (VCFs) at levels T7 to L4 due to osteoporosis arising from primary and secondary etiological factors. There were 41 VCFs in these 30 patients. The median age was 69 years (range 53-87 years). Subjects were excluded if they had associated spinal stenosis, neurologic deficit, an active infection, and severe comorbidities, such as uncorrected coagulopathy.

Results

According to the pain scores, 26 (87%) patients showed a drastic post-operative improvement whereas, in 2 cases, significant improvement was noted after a follow-up in 3 months. On the other hand, 2 (7%) patients showed a deteriorated pain score. 24 (80%) patients showed constant improvement over a period of 6 months. 7 patients (23%) showed further improvement after the 6 months clinical follow-up.

Conclusion

All PMMA extravasations were asymptomatic; the cement was observed at a close vicinity to the treated vertebrae. We treated 41 fractures with balloon kyphoplasty (BKP); however, the failure of balloon distension occurred in 6 fractures (14%), which were managed with conventional vertebroplasty; Therefore, the exact cause behind the failure of the procedure is still unclear.

Keywords

Kyphoplasty; Osteoporotic fractures; Vertebral fractures.

Abbreviations

VCFs: Vertebral Compression Fractures; PKP: Percutaneous kyphoplasty; PMMA: Poly-methylmethacrylate; OVCF: Osteoporotic Vertebral Compression Fractures; BKP: Balloon kyphoplasty.

INTRODUCTION

The National Osteoporosis Foundation has estimated that more than 100 million people worldwide are at a risk of developing fractures secondary to osteoporosis. Osteoporotic vertebral compression fractures (OVCFs) constitute a major healthcare problem in the Western Countries, not only because of the high incidence of these lesions, but also due to their direct and indirect negative implications on the patient's quality of life (QoL) owing to health concerns, and the costs associated with the healthcare system. Compression fractures lead to a loss in the height of the vertebral segment, and the resulting spinal deformity can lead to a decrease in the pulmonary capacity and mobility, malnutrition and depression. Kyphosis secondary to the osteoporotic vertebral compression fractures attributes a 2 to 3 times greater incidence of death primarily on account of pulmonary causes.^{1,4}

Although, the usual treatment strategy for an osteoporotic vertebral compression fracture may be bedrest, the application of analgesics, and bracing, some fractures may lead to progressive deformity and a debilitating pain. Several techniques have been developed for simpler and safer procedures during the last 2 decades. Techniques of vertebral body augmentation have been developed in an effort to treat these refractory cases. The high-pressure injection of low-viscosity poly-methylmethacrylate (PMMA) poses potential risks for neural compromise and pulmonary embolism due to uncontrolled leakage. Therefore, balloon kyphoplasty (BKP) and vertebroplasty, using a large cannula low-pressure injection of PMMA in a high viscosity state has been introduced.

Percutaneous kyphoplasty (PKP) is a recently developed, minimally invasive surgical approach for the treatment for OVCF. PKP with acrylic cement PMMA is a procedure aimed at preventing vertebral body collapse and pain in patients with pathological vertebral bodies. PKP is a promising therapeutic technique for controlling pain in patients with bone marrow failure. PKP for OVCFs are typically performed by delivering double balloons implementing a bilateral or unilateral transpedicular approach; the balloons are inflated simultaneously for elevating the end plate to support vertebral body height balanced restoration.

The deformity is purportedly corrected by the insertion and expansion of a balloon into a fractured vertebral body. After a reduction of the fracture bone, the cement is deposited into the cavity created by the balloon to repair the fracture. Good clinical outcomes as well as restoration of the vertebral body height have been reported with kyphoplasty.⁵⁻⁷

Absolute contraindications to any vertebral augmentation procedure includes asymptomatic osteoporotic vertebral compression fractures, local or systemic infection, uncorrectable coagulopathy, or improving pain with the use of appropriate medications. Fracture of the posterior elements (without vertebral body fractures) is among the other absolute contraindications of the procedure. The complications associated with balloon kyphoplasty include non-target PMMA embolization, adjacent vertebral body or rib fracture and infection.⁸

PATIENTS AND METHODS

A prospective analysis of 30 patients treated with kyphoplasty was performed at our institution. These patients had VCFs at levels T7 to L4 due to osteoporosis arising from primary and secondary osteoporosis. There were 41 VCFs in these 30 patients. The goals of this study were to determine the safety and effectiveness of kyphoplasty in improving vertebral body height, decreasing pain, and improving function. The study included 30 patients (10 male, 20 female), who were followed up after six months. The median age was 69 years (range 53-87 years). Subjects were excluded if they had associated spinal stenosis, neurologic deficit, an active infection, and severe comorbidities, such as uncorrected coagulopathy.

The date of the fracture was carefully determined by a retrospective chart review. During the pre-operative visit, the patient was subjectively asked to recall a traumatic event or the cause of the sudden onset of pain. The interval between the date of fracture and the date of surgery determined the age of the fracture. The age of the fracture could be determined for 39 of the 41 fractures based on this method of data collection. Two patients (no. 8, MS) and (no. 21, NM) could not recall a specific incident which marked the beginning of their focal pain. A fracture was defined as fresh up to the 28th day following the event causing the injury.

Physical examination combined with lateral radiographs, magnetic resonance imaging (MRI) and computerized tomography (CT), were performed to diagnose the vertebral body compression fractures.

Radiographic Evaluation

Standing films were used to detect the kyphosis of fractures associated with the vertebral body. In some patients, pre-operative standing films could not be obtained on account of reported pain. In these cases, measurements were taken from the available supine films (Tables 1 and 2).

Kyphotic angles across the fractured levels were measured using the Cobb technique: measurements were taken from the superior end plate of the vertebra from one level above the treated vertebra, to the inferior endplate of the vertebral body one level below the treated vertebra. When non-adjacent levels of the vertebrae were treated in a patient, separate Cobb angles were measured for each treated level. When adjacent level vertebral fractures were treated, a single Cobb angle measurement across the treated levels was performed. Thoracic and lumbar fractures were analyzed for alterations in the angles of kyphosis and lordosis, respectively. Plain radiographs were obtained pre-operatively, immediate post-operatively, after three months and after the last follow-up. This method has been shown to be the least variable and the most reliable technique in the measurement of fractures due to kyphosis.

Not all patients underwent MRI on account of their financial issues. In those patients who underwent MRI, the fractured levels which needed augmentation, showed the evidences of edema on T2-weighted images and short T1 inversion recovery sequences (STIR view) following MRI; hence, causing pain. These

Table 1. Study Demographics	
(Present & past), physical examination and neurological examination parameters	Number
Subjects	
No. Females	20
No. Males	10
Total number	30
Median subject age (years)	69
Range of age	(53-87)
Etiology of index fracture	
No. of primary osteoporosis cases	27
No. of secondary osteoporosis cases	3
Index fracture age	
No. less than 60	3
No. between 60-80	24
No. more than 80	3
Index fracture treated	
No. One	21
No. Two	7
No. Three	2
Location of fracture	
Total number (T7-L4)	41
Thoracic (T7-T9)	1
Thoraco-Lumbar junction (T10-LV2)	33
Lumbar (LV3-LV4)	7

patients were therefore considered for treatment. CT scans were performed in patients who were at a risk of developing posterior wall fracture. Fluoroscopic and radiographic images were used to monitor the extravasation associated with all the treated vertebral levels. The operation was performed when painful thoracic or lumbar osteoporotic fractures were diagnosed without affecting the posterior vertebral edge.

Device Design

The kyphoplasty system consists of a balloon, of which one or two each are inserted into the vertebral body and simultaneously inflated with a contrast saline solution, under a pressure of up to (150-200) PSI, to symmetrically expand both the balloons. After the balloon expansion is sufficient and/or complete, the balloons are deflated and retrieved, leaving both the restored height, and PMMA cement injected into the cavities (Figure 1).

Surgical Technique

A radiolucent table and 2 C-arm fluoroscopy machines, Mobile Digital C-Arm were used for performing kyphoplasty at our institute. The 2 fluoroscopy machines placed orthogonally across the radiolucent table allowed simultaneous viewing of the anteroposterior and lateral projections of the fractured level. This process helped to speed up the operation and minimize the risks of contamination during the operation. The patient was then taken to the operating room, where general anesthesia was administered in 18

procedures and local anesthesia with heavy sedation in 12 interventions.

The patient was carefully turned prone and all bony prominences were protected. To prevent infection, a pre-operative single shot of I.V dose of a third-generation cephalosporin was administered. Two fluoroscopy machines were then wheeled into the position, and the fractured level was centered in both the anteroposterior and lateral projections, before the patient was draped and prepared for the surgery. The fluoroscopy machines were also covered with appropriate sterile covers following which a 1 cm incision was made, lateral and superior to both the pedicles.

Under continuous fluoroscopic guidance, the guide wires were inserted into the superior outer pedicle quadrant using slight manual pressure and controlled blows from a hammer. The working sleeves over a side opening cannula were applied and the guide wires were removed. At this stage, any bone fragment that was extracted through the cannulae, was collected for biopsy and sent for histopathological examination. A drill was manually twisted into the vertebral body to create a tract for the balloon. The balloon catheters were inserted bilaterally or unilaterally and this was continued till the white indicator on the catheter shaft aligned with the top of the working sleeves and then the packaging wires were removed.

The prepared kyphoplasty inflation systems were connected bilaterally and the air bubbles were evacuated out of the

Table 2. Data Relevant to the Treated Patients: Initials, Age of the Patient, Sex, Level Treated, Age of the Fracture (Pre-operative Symptoms), Pre-operative Vertebral Kyphosis, Post-operative Vertebral Kyphosis

No.	Patient	Age	Gender	Age of fracture (days)	Level of fracture	Anesthesia	Pre-operative Kyphosis (°)	Post-operative kyphosis	Approach
1	M.A	76	M	13	D12	L	32	25	BI
2	M.S	64	M	9	D12	L	12	4	BI
3	L.E	76	F	21	D7	L	29	22	BI
4	S.A	76	F	16	L3	G	48	34	BI
5	M.H	72	F	8	D12	G	15	7	UNI
5	M.H	72	F	8	L2	G	2	0	UNI
5	M.H	72	F	8	L4	G	25	22	UNI
6	A.H	84	M	3	L2,3	L	11	9	UNI
7	T.M	62	F	25	L4	L	35	35	BI
8	M.S	85	M	UNKNOWN	D11	L	18	18	BI
9	G.M	71	F	16	D12	G	10	8	UNI
9	G.M	71	F	16	L2	G	16	10	UNI
10	M.M	72	M	5	D12	G	8	8	BI
10	M.M	72	M	5	L2	G	12	10	BI
11	F.A	58	F	35	D12,L1	G	40	29	UNI
12	Z.H	87	F	5	D10,11,12	G	60	43	BOT
13	M.S	65	F	18	D10,11	G	28	17	BI
14	L.M	66	F	9	D12	L	20	11	UNI
15	G.A	62	M	18	D12	G	30	16	BI
16	S.S	53	F	1	L1	G	25	8	BI
17	A.M	74	M	2	D10	L	11	5	UNI
18	S.A	77	F	12	L3	L	6	2	UNI
19	Z.A	79	M	14	L1	G	10	7	BI
20	FE	73	F	33	D12	L	16	12	UNI
20	FE	73	F	33	L3	L	20	15	UNI
21	N.M	66	F	UNKNOWN	D10,1	G	21	18	UNI
22	N.D	59	F	18	D12	G	16	12	BI
23	L.O	67	F	6	L4	G	38	29	BI
24	K.B	73	F	5	D12	L	15	12	UNI
25	M.K	63	M	4	D12	G	28	18	BI
26	M.S	65	F	10	L1	G	8	5	BI
27	D.L	71	F	9	L1	L	20	14	UNI
28	A.N	64	M	8	L1	G	30	22	UNI
29	K.T	60	F	6	L1	G	8	5	UNI
30	M.A	64	F	7	L1	G	12	10	UNI

catheters. According to the visual (fluoroscopic) and manometric parameters, the criteria for stopping the balloon inflation were: when the fracture reduced, when the balloon violated the confines of the bone, when the inflation pressure reached (150-200) psi, or when a maximum balloon volume was obtained.


The balloons were gradually deflated and removed through the working sleeves. PMMA cement corresponding to the combined volume of the inflated balloons was inserted bilaterally, using the side-opening cannulae. Each step was performed under fluoroscopic control.

The criteria for stopping the cement injection was the incidence of cement leakage anteriorly, posteriorly or across the disc spaces and when the injected volume showed a reading of 3 cc. Thus, the cannulae were pulled back slightly but kept in position until the cement hardened, then twisted to break off any connected cement from being left behind in the pedicles (Figures 2, 3, 4, 5, 6, 7, 8 and 9).

Clinical Outcome Measurements

Clinical outcomes were measured pre-operatively and post-operatively.

Figure 1. Kyphoplasty Balloon Set



tively using the visual analogue scale (VAS) and the Oswestry disability index (ODI) score.

Visual Analog Scale (VAS)

Patients were asked to mark their pain on a scale of 0.0 to 10.0 cm where 0.0 cm indicated no pain at all and 10.0 cm was indicative of the worst pain imaginable. VAS scores were examined before the procedure, and 1, 4, 12 and 24 weeks after the procedure (Figure 9).

Oswestry Disability Index (ODI)

The ODI is a low back pain-specific questionnaire that assesses the ability of the patient to perform various activities of daily living. The ODI shows high test-retest reliability and is the most commonly recommended condition-specific outcome scoring measure in patients with chronic low back pain. Although, the ODI was initially developed specifically for low back pain, even thoracic fractures causing a great degree of referred low back pain and thus, impairing the functional capabilities of the affected individual, can

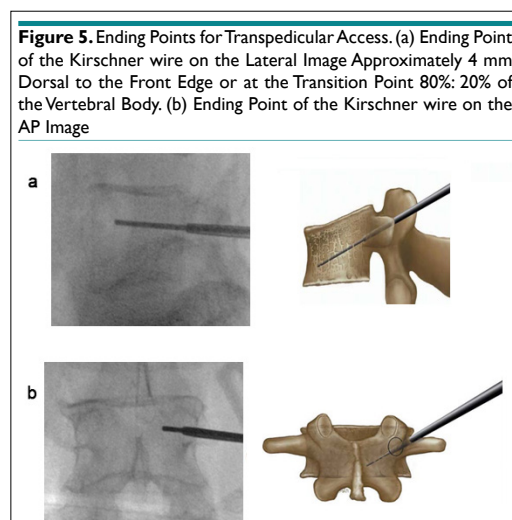
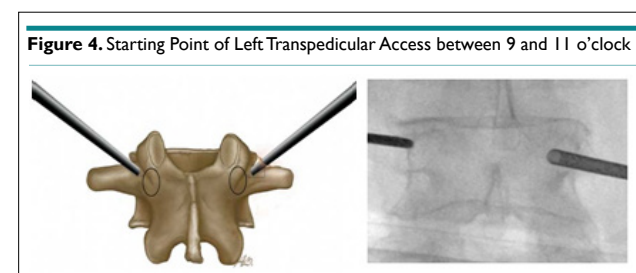
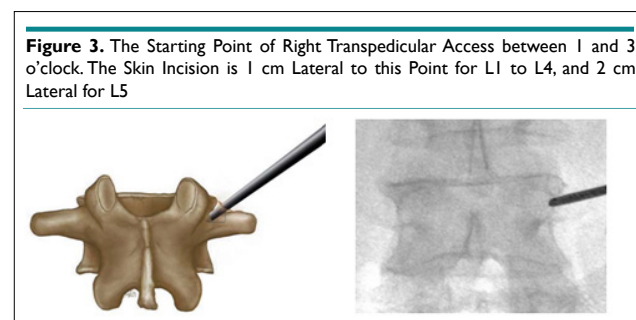
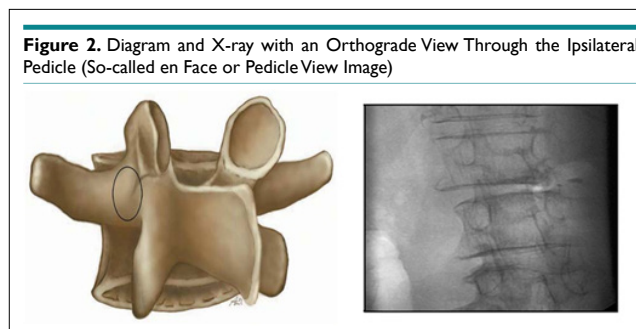


Figure 6. Introduction of the Jamshidi Needle and the Operating Cannula (osteointroducer). (a) Starting Point of the Jamshidi Needle on the Lateral View (b-d) The Cranial-Caudal Orientation of the Jamshidi Needle has to be Adapted According to the Type of Fracture. (b) Fracture Type A1.2.1. (c) Fracture Type A1.2.3. (d) Fracture Type A1.3. (e) Ending Point of the Jamshidi Needle with a Slight Perforation of the Posterior wall on the Lateral View. (f) Ending Point of the Jamshidi Needle on the Anteroposterior View. The Medial Limitation of the Pedicle Ring should not be Exceeded. (g) Ending Point of the Operating Cannula Lying at Least 2-3 mm Ventrally of the Posterior wall of the Vertebral Body. (h) Biopsy with Bonefiller. (i) Preparing the Cannula for the Balloon

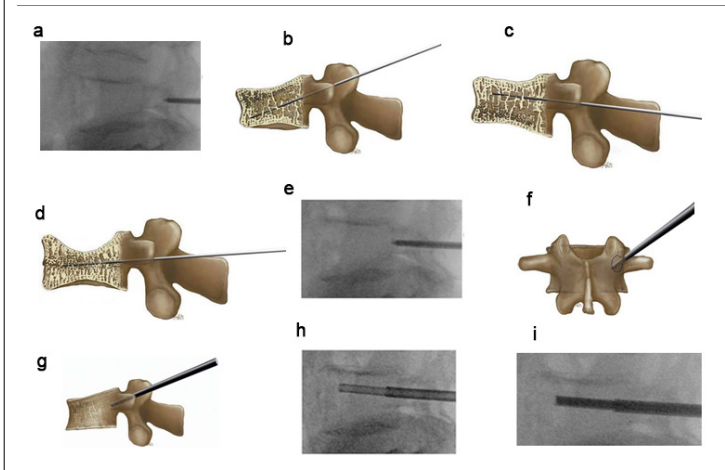
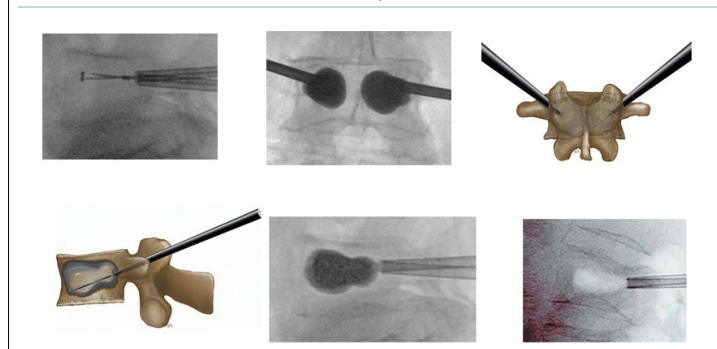


Figure 7. Non-Inflated Balloons in the Vertebra, both Markings of the Balloons must lie Outside the Operating Cannula. Ending Points of the Balloons, the Balloons should not Perforate any Cortical Substance, Neither on the Antero Posterior, nor on the Lateral View. The Removal of the Balloons Leaves an Extensive Cavity in the Vertebra



be evaluated using the ODI score. The ODI scores were recorded before the procedure, and at 4, 12 and 24 weeks after the procedure.

RESULTS

A total of 30 patients with 41 VCFs underwent cement augmentation at our institution from February 2011 to June 2013. The study population included 10 males (33.3%) and 20 females (66.6%). The median age of the patients was 69 years (range 53-87 years). The follow-up period was 24 weeks (Figure 10)(Table 3).

There were 24 patients (80%) who were included in the age group (60-80 years), 3 patients (10%) who were included in the age group (above 80 years) and 3 patients (10%) who were aged less than 60-years-old. The mean age of the patients was 69 years (Table 4)

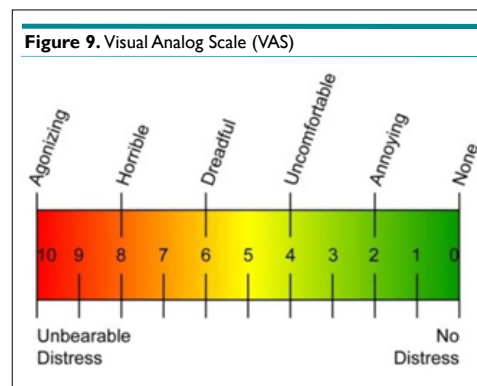
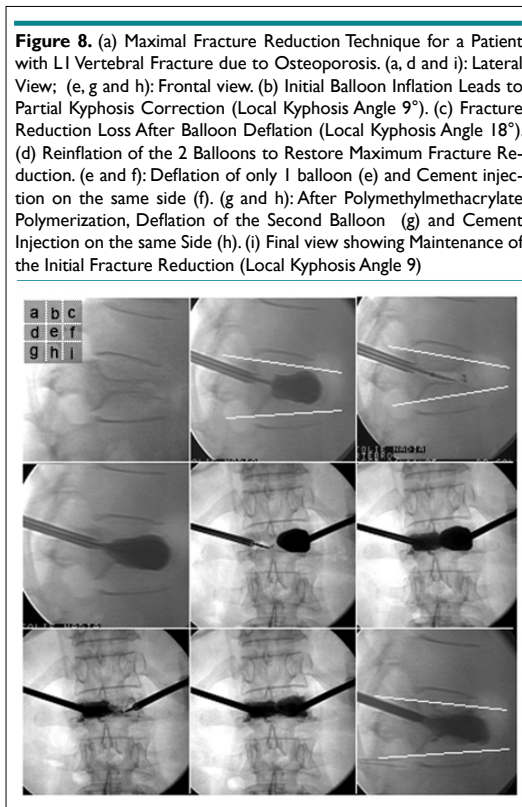
The causes of injury were either simple fall on the ground

for 14 patients (46.7%), real time adjudication (RTA) in 6 (20%) patients, 4(13.3%) patients had a history of lifting heavy objects preceding their feeling of pain and 6(20%) patients developed a sudden onset of pain without precipitating the incident (Table 5).

Fifteen (50%) patients presented with a history of fracture of less than 10 days whereas 11 (36.7%) patients reported the incidence of a fracture 10-30 days back. 2 patients (6.7%) presented with a history of fracture 30-40 days before. It was noted that in 2 patients (6.7%), the exact age of the fracture could not be estimated (Table 6).

In 21 (70%) patients, one level fracture was treated while in 7 patients (23%) two levels were augmented. In 2 (7%) patients, three levels were treated (Table 7).

There were 3 patients (10%) who reported secondary osteoporosis. This condition was caused by long-term corticosteroid therapy in one patient and renal failure in two patients. The remaining 27 (90%) patients were assumed to have primary osteo-



porosis (Figure 11).

The largest concentration of fractures was detected in the thoraco-lumbar junction where T12 revealed 12 (27%) fractures, LV1 sustained 9 (30%) fractures and LV3 revealed 5 (11%) fractures (Table 8).

Eighteen interventions were performed under intubation, and 12 (40%) patients were operated with the application of local anesthetics in combination with IV sedation (Table 9).

All the patients were mobilized within the first 48 hours after surgery. 26 patients (87%) were hospitalized for 1-3 days. Due to additional injuries, 4 (13%) patients were kept in the hospital for a maximum of 10 days.

The Clinical Outcomes

Change in spinal sagittal alignment

The median kyphosis angle was 21.8° before the procedure and decreased by a median value of 6.7° after the operation. 60% of the patients experienced a reduction in kyphosis by more than 5° (Interquartile range of 10°). In an analysis of this subgroup of patients, faster pain relief was achieved relative to the patients who showed minimal to no reduction in the kyphotic angle. The VCFs were then analyzed in the spinal region (thoracic or lumbar). 23 thoracic vertebral compression fractures were treated in 18 patients with a median improvement of 5.8° (range 0° to 17°) in the sagittal alignment across the treated segments. 18 lumbar vertebral compression fractures were treated in 16 patients with a 5.6° (range 0°-17°) median improvement in the angle of lordosis (Table 15). If fractures that were considered reducible by BKP (defined as at

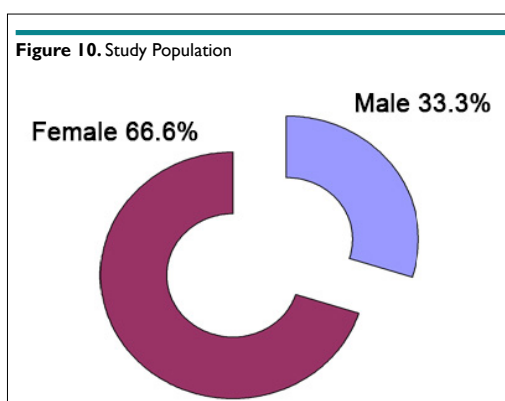


Table 3. Age Groups of the Patients

Age groups	Number	Percentage
Below age 60 years	3	10
60-80 years	24	80
Above 80 years	3	10
Total	30	100

Table 4. Mechanism of Injury

Mechanism	Number	Percentage
Simple fall	14	46.7%
RTA	6	20%
Lifting heavy	4	13.3%
No obvious cause	6	20%
Total	30	100%

Table 5. Index Fracture Age

Age of patients	Number	Percentage
No. less than 10	15	50%
No. 10-30	11	36.7%
No. 30-40	2	6.7%
Unknown	2	6.7%
Total	30	100%

Table 6. Index Fracture Treated

Number of levels	Number	Percentage
No. One	21	70%
No. Two	7	23%
No. Three	2	7%
Total	30	100%

Table 7. Etiology of Fractures

Etiology	Number	Percentage
Primary	27	90%
Secondary	3	10%
Total	30	100%

least 5° improvement in sagittal alignment) were analyzed, 18 fractures in 18 patients showed an improvement in the sagittal alignment of 10° (range 6° to 17°) (Table 1). Statistical significance in improvement of the sagittal angle from pre-operative to postoperative measurements reached the $p < 0.0001$ level (Wilcoxon signed-rank test) for all fractures combined, thoracic fractures, lumbar fractures, and reducible fractures (Tables 10, 11 and 12).

Note that, in 3 fractures (7%), the reduction was achieved by less than 2°, while a reduction of 2-5° occurred in about 17 fractures (42%). In 11 (27%) fractures, a reduction of about 6-10°. On the other hand, a reduction by about 11-17° was achieved in about 10 reported fractures.

Visual Analogue Scale (VAS)

The median VAS scores dropped from 8.7 pre-operatively to 3.5 within one week post-operatively, to 1.7 at 12 weeks following the

procedure and to 1.5 at 24 weeks and in the last follow-up (Figure 12) (Table 13).

Two patients reported deterioration; one of them (no. 20, F.E) indicating a change of score from “2” after a 3 months follow-up to “7” after 6 months. On further examination of this patient, no adjacent level fractures were detected and the patient was treated conservatively using epidural injections which improved the patient’s condition and physiotherapy and medications were continued. The other patient (no. 18, S.A) reported an exacerbating condition of pain, 6 months following the BKP. Upon further assessment of the patient, no adjacent level fractures were noted, but the patient’s condition presented a clinical picture of discitis for which the patient is still undergoing further investigation and treatment (Table 14).

26 (87%) patients achieved a dramatic post-operative improvement whereas, in 2 cases, significant improvement was

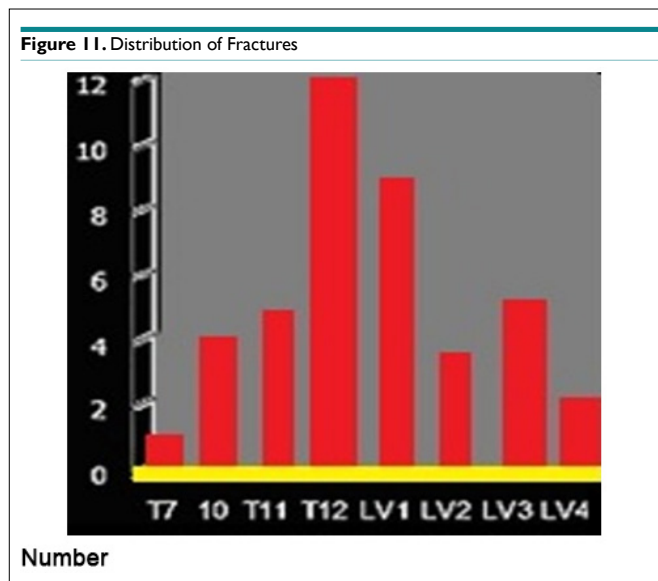


Table 8. Mode of Anesthesia

Anesthesia	Number	Percentage
General	18	60%
Local with heavy dose	12	40%
Total	30	100%

Table 9. Post-operative Hospital Stay

Duration of stay	Number	Percentage
1-3 days	26	87%
3-10 days	4	13%
>10 days	None	None
Total	30	100%

reported after the 3 months follow-up. On the other hand, 2 (7%) patients showed a further deterioration in the pain score. 24 (80%) patients showed a constant improvement over a period of 6 months, with further improvement noted in 7 patients (23%) (Table 15) (Figure 13).

The mean pre-operative ODI score was 80, decreasing to 32 following the 1st month post-operatively, and improving to 21 and 17 after the 3-month and the last follow-up, respectively (Figure 14).

The median pre-operative ODI score was 85.00, improving to 32.6 after the 1st month post-operatively, and decreasing to 22 and 18 after the 3rd month and the last follow-up (Table 16).

Complications

There were 3 medical complications reported. Seven days after BKP, pulmonary embolism was diagnosed in a patient (no. 8, M.S) with a history of deep vein thrombosis (no evidence of PMMA leakage to the lungs by (CT angiography). The other two patients (no. 1, M.A and no. 18, S.A) underwent peri-operative renal impairment marked by an increase in the creatinine level and thus needed close medical follow-up (Table 17) (Figure 15).

Cement Leakage

Evaluation of intraoperative and post-operative radiographs revealed extra vertebral cement leaks in 11 (27%) of the 41 vertebral

fractures treated (Tables 18 and 19) (Figure 16).

In 3 fractures, the cement leaked into the adjacent intervertebral disc, in 4 fractures, leakage occurred anterior to the vertebral body, and in 3 fractures the leakage occurred lateral to the vertebral body and in 1 patient, (no. 17, A.M) the cement leaked posteriorly into the spinal canal but with no obvious complications. All PMMA extravasations were asymptomatic, the cement remained in the immediate vicinity of the treated vertebrae, and no medical or surgical intervention was required to remove the extravasated PMMA. The clinical results of the group of patients with PMMA extravasation did not differ from those subjects in whom it was not observed.

Failure of Balloon Distension

Forty-one fractures were treated with BKP. The failure of the balloon distension occurred in 6 fractures (14%), so these fractures were treated with conventional vertebroplasty and the possible reasons associated with it have been discussed in the following paragraphs.

Fracture of Bone Filler

We treated 41 fractures with BKP. The fracture of the bone filler occurred only in 1 patient, (no. 13, M.S), further managed by wound dilatation. The sawing of the bone filler near the bone and the remaining lift inside the pedicle was treated by an administration of I.V third generation cephalosporin 1gm twice daily for 5

Table 10. Data of the Treated Patients: Level Treated, Pre-operative Vertebral Kyphosis, Reduction Achieved, and Correction in Percent

No.	Patient	Level of Fracture	Kyphotic pre-operative (°)	Kyphotic post-operative (°)	Reduction (°)	Reduction (%)
1	M.A	D12	32	25	7	22%
2	M.S	D12	12	4	8	67%
3	LE	D7	29	22	7	24%
4	S.A	L3	48	34	14	29%
5	M.H	D12	15	7	8	53%
5	M.H	L2	2	0	2	100%
5	M.H	L4	25	22	3	12%
6	A.H	L2,3	11	9	2	18%
7	T.M	L4	35	35	0	0%
8	M.S	D11	18	18	0	0%
9	G.M	D12	10	8	2	20%
9	G.M	L2	16	10	6	37%
10	M.M	D12	8	8	0	0%
10	M.M	L2	12	10	2	16%
11	FA	D12,L1	40	29	11	27%
12	Z.H	D10,11,12	60	43	17	28%
13	M.S	D10,11	28	17	11	39%
14	LM	D12	20	11	9	45%
15	G.A	D12	30	16	14	47%
16	SS	L1	25	8	17	68%
17	A.M	D10	11	5	6	54%
18	S.A	L3	6	2	4	66%
19	Z.A	L1	10	7	3	30%
20	FE	D12	16	12	4	25%
20	FE	L3	20	15	5	25%
21	N.M	D10,11	21	18	3	14%
22	N.D	D12	16	12	4	25%
23	L.O	L4	38	29	9	23%
24	K.B	D12	15	12	3	20%
25	M.K	D12	28	18	10	36%
26	M.S	L1	8	5	3	38%
27	D.L	L1	20	14	6	30%
28	A.N	L1	30	22	8	27%
29	K.T	L1	8	5	3	38%
30	M.A	L1	12	10	2	17%

Table 11. Improvement in Spinal Sagittal Alignment

	N (Fractures/Patients)	Median Preoperative Cobb Angle (Range)	Median Postoperative Cobb Angle (Range)	Median Change in CobbAngle (Range)	p-value*
Overall	41/30	21.8° (1-60°)	16° (2-43°)	6.7° (0-17°)	<0.0001
Thoracic	22/18	17.8° (8-60°)	12.9° (4-43°)	5.8° (0-17°)	<0.0001
Lumbar	19/16	19.8° (2-48°)	14.8° (0-34°)	5.6° (0-14°)	<0.0001
Readily reduced^o	18/18	29° (11-60°)	19° (4-43°)	10° (6-17°)	<0.0001

* Wilcoxon signed-rank test, preoperative vs. postoperative Cobb angles.
^o Improvement in kyphosis of >5°.

Table 12. Change in Kyphoticangle

	No. of patients	Percentage
Minimal to reduction<2	3	7%
Reduction 2-5 degrees	17	42%
Reduction 6-10 degrees	11	27%
Reduction 11-17 degrees	10	24%
Total	41	100%

Figure 12. Median VAS Pain Scores in which 1 Indicates No Pain and 10 Indicates Severe Pain. Compared with Pre-operative Scores, there was a Significant Pain Relief ($p < 0.001$) at all Post-operative Values

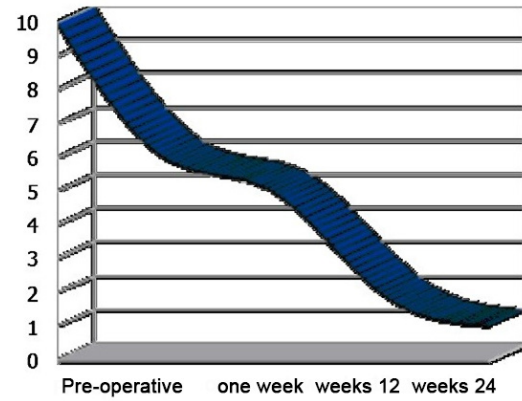


Table 13. Pain Score as given on VAS (1-10), Pre-operatively and at Follow-ups. For Average Values, 1 Patient Counts as a Single Procedure

No.	Patient	Level of fracture	Pre-operative	1 week	12 weeks	24 weeks
1	M.A	D12	6	2	2	0
2	M.S	D12	8	6	0	2
3	L.E	D7	9	8	8	9
4	S.A	L3	10	6	5	2
5	M.H	D12	8	2	2	1
6	A.H	L2,3	10	6	5	4
7	T.M	L4	10	0	0	1
8	M.S	D11	8	6	3	1
9	G.M	D12	8	2	0	0
10	M.M	D12	7	1	4	5
11	FA	D12,L1	10	0	0	0
12	Z.H	D10,11,12	6	4	4	1
13	M.S	D10,11	10	2	-	-
14	LM	D12	7	1	0	1
15	G.A	D12	10	3	0	0
16	S.S	L1	9	4	1	0
17	A.M	D10	8	3	1	0
18	S.A	L3	10	8	7	4
19	Z.A	L1	7	5	3	2
20	FE	L3	9	5	2	7
21	N.M	D10,11	8	5	1	0
22	N.D	D12	10	4	0	1
23	L.O	L4	9	3	0	0
24	K.B	D12	10	6	2	6
25	M.K	D12	10	3	0	0
26	M.S	L1	8	0	0	0
27	D.L	L1	9	3	0	1
28	A.N	L1	9	3	2	1
29	K.T	L1	8	1	0	-
30	M.A	L1	9	3	-	-

Table 14. Modes of Improvement

	Number	Percentage
Immediate post-operative follow-up	26	87%
Over 3 months	2	2%
Constant	24	80%
Further	2	7%
Further	7	23%

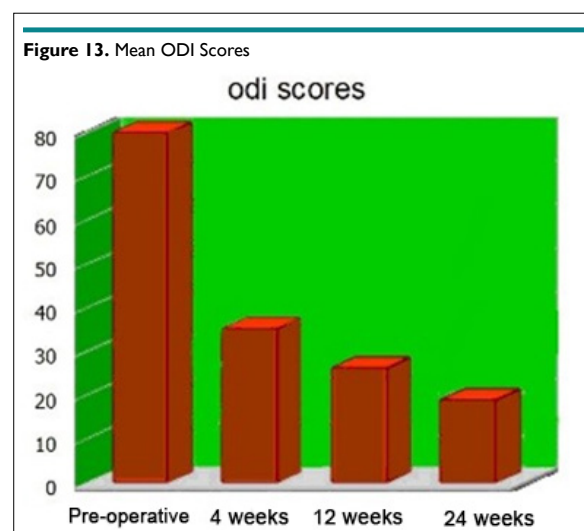
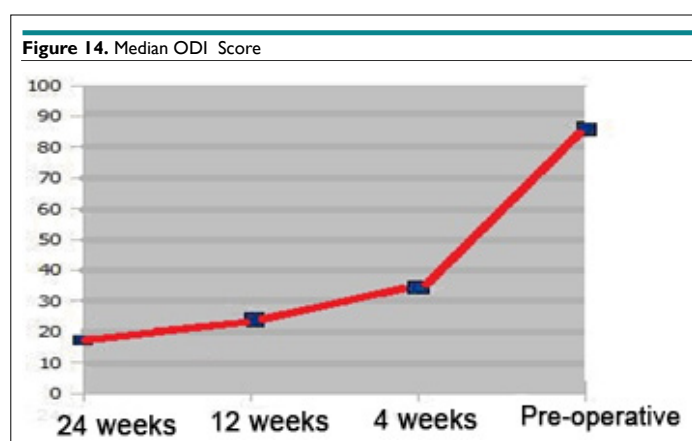


Table 15: Oswestry Disability Index.

	Means±SE	Median	Std. Deviation	Interquartile
Pre-operative ODI	80± 2.5	85.000	14.529	22.500
1 month post-operative	32± 3.256	32.6	13.200	18.200
3 months post-operative	21.4667±2.909	22.000	10.936	13.500
Last follow-up	17.933±2.727	18.000	6.339	9.400

SE: standard error; ODI: Oswestry Disability Index; Std. deviation: Standard deviation.



days. The cause of this problem was attributed to the late removal of the bonefiller till the P.M.M.A was hardened. The clinical results did not differ from those subjects in whom it was not observed.

DISCUSSION

Vertebral fractures are the most commonly reported fractures in patients who suffer from osteoporosis. The estimated prevalence of vertebral fractures in women aged between 50 years and older is between 25-26%. The lifetime risk for a 50-year-old woman to develop at least 1 traumatic vertebral fracture is 32%. Multiple vertebral fractures are found in about half of the reported cases such that 84% are associated with pain. While the incidence of vertebral

fracture is high, a minority of vertebral fractures (about one-third) requires clinical diagnosis. In the U.S.A, osteoporotic vertebral fractures account for approximately 650,000 clinically detected fractures per year.⁹⁻¹¹

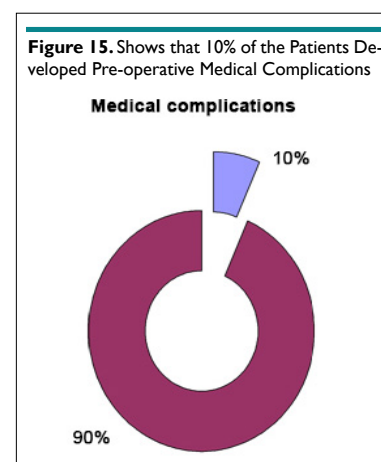
Acute vertebral fractures may present with pain, although clinically silent fractures may account for one half of the radiographically visible vertebral fractures. Pain management under acute conditions is not standardized and inadequate data is available on the natural history of acute painful vertebral fracture. Common management strategies include rest, activity modification, and the use of local and/or systemic analgesics.⁹

Table 16. ODI Scores, Pre-operatively and at Follow-ups. 1 Month, 3 Months and 6 Months Post-operative

No.	Patient	Level of fracture	Pre-operative	4 weeks	12 weeks	24 weeks
1	M.A	D12	60.00	20.00	36.00	24.00
2	M.S	D12	56.00	2.00	2.00	24.00
3	L.E	D7	80.00	52.00	80.00	74.00
4	S.A	L3	94.00	72.00	72.00	64.00
5	M.H	D12	82.00	34.00	20.00	20.00
6	A.H	L2,3	96.00	70.00	64.00	64.00
7	T.M	L4	98.00	2.00	2.00	2.00
8	M.S	D11	66.00	70.00	38.00	42.00
9	G.M	D12	60.00	6.00	2.00	2.00
10	M.M	D12	72.00	2.00	34.00	26.00
11	F.A	D12,L1	100.00	2.00	2.00	2.00
12	Z.H	D10,11,12	76.00	56.00	58.00	26.00
13	M.S	D10,11	100.00	8.00	-	-
14	L.M	D12	52.00	2.00	0.00	0.00
15	G.A	D12	88.00	20.00	2.00	0.00
16	S.S	L1	100.00	28.00	0.00	0.00
17	A.M	D10	80.00	18.00	0.00	0.00
18	S.A	L3	100.00	90.00	76.00	42.00
19	Z.A	L1	88.00	66.00	42.00	36.00
20	F.E	L3	86.00	50.00	20.00	38.00
21	N.M	D10,11	80.00	56.00	26.00	0.00
22	N.D	D12	100.0	36.00	6.00	0.00
23	L.O	L4	80.00	32.00	2.00	0.00
24	K.B	D12	100.00	44.00	22.00	58.00
25	M.K	D12	100.00	26.00	0.00	0.00
26	M.S	L1	80.00	18.00	2.00	0.00
27	D.L	L1	100.00	40.00	42.00	0.00
28	A.N	L1	100.00	32.00	8.00	8.00
29	K.T	L1	80.00	4.00	0.00	2.00
30	M.A	L1	98.00	30.00	2.00	0.00

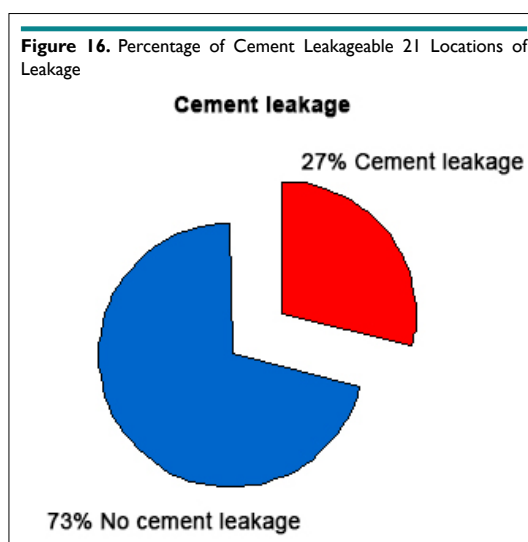
Table 17: Medical Complications.

	Number	Percentage
Medical complications	3	10%
No medical complications	27	90%
Total	30	100%



	Number	Percentage
Cement leakage	11	27%
No cement leakage	30	73%
Total	41	100%

Location of leakage	Number	Percentage	Complications
Adjacent intervertebral	3	27%	No
Anterior to vertebral	4	36%	No
Lateral to vertebral body	3	27%	No
In the spinal canal	1	9%	No
Total	11	100%	No



Chronic pain, usually following multiple vertebral fractures, tends not to respond to the management strategies implemented for acute pain. The source of chronic pain after vertebral compression fracture is not thought to be the vertebra itself, but is believed to relate predominantly to a strain on muscles and ligaments secondary to kyphosis. This type of pain is not frequently improved with the use of analgesics and may be better addressed through performing exercises. Epidemiologic studies also suggest that vertebral compression fractures may be associated with long-term mortality. In a prospective cohort study of women older than 65 years, 10-year mortality was recorded to be proportional to the number of symptomatic vertebral compression fractures, rising from 19 per 1,000 person-years with no fractures to 44 per 1,000 person-years in women with 5 vertebral compression fractures.^{9,12}

Pain can be caused by nociceptors in the bone itself, the disc complex, the perivertebral structures, through nerve compression, joint or muscle pain. Although most of the patients with this injury experience a benign and self-limited course of gradually resolving pain, a significant number continues to experience chronic pain, progressive kyphosis and disability. Long-term consequences include significantly decreased activities of daily living (ADL) accounting for five million limited activity days in the US.¹³

As a consequence, the patients suffer from an increased dependence on others, sleeping disorders and clinical anxiety, in-

cluding reduced mobility. Finally, hyperkyphotic patients are at a risk of experiencing reduced pulmonary functions.¹⁴

As our population ages, the rate of osteoporotic fractures is expected to triple over the next few decades.¹⁵ An ideal strategy for the treatment of VCF should be towards relieving fracture related pain and improving the QoL. Kyphoplasty was designed to address the kyphotic deformity and to help realign the spine.¹⁶⁻¹⁸

The first reported case of kyphoplasty was published by Wong et al¹⁷ in the Journal of Women's Imaging in 2000. They reported a study conducted on 85 patients. Over 90% of the patients indicated good or excellent pain relief. The height restoration was 62%. Lieberman et al¹⁹ presents a prospective clinical examination of phase-I investigation for the treatment of 30 patients with 70 Kyphoplasty procedures performed. Local cement leakage was observed in 8.6% of the reported cases. The restoration of the VB height was 47% in 70% of the cases, and in the remaining 30% of the cases, no measurable correction was achieved.

In 18 patients, 55 kyphoplasty procedures were performed. With respect to height loss, 34% was restored, and leakage was observed in 4% of the vertebrae.²⁰ Theodorou et al²¹ reports the treatment of 15 patients with 24 BKP. Height restoration was best observed in the mid-vertebral body with 65% of the patients. Kyphosis correction was 9.5° in an average or was achieved by

62%. Pain was improved in all the patients after a follow-up of 6-8 months.²¹ Coumans et al²² presents a prospective study with kyphoplasty with a minimal follow-up of 1 year. Of 78 patients with 188 kyphoplasty procedures, 62% were available for a follow-up evaluation. They report five cases of asymptomatic extravasation SF36; Oswestry score and pain (VAS) did improve immediately post-operatively with a lasting effect at FU. The kyphosis correction is not mentioned.²²

It has been reported that kyphoplasty can improve the kyphotic angle in the range of (3.4° to 8.8°) degrees. However, clinically, 34% of the cases of kyphoplasty do not show a demonstrable reduction in the kyphotic angle or restoration of the vertebral body height. One reason for inadequate height preservation in kyphoplasty is the loss of vertebral body height after balloon deflation, prior to the cement injection.²³ Despite positioning the patient in a lordotic position (prone position with a concave curvature of the spine), compression forces of approximately 110 N are still exerted on the vertebrae and may contribute to the collapse of the created cavity.^{23,24} This is an inherent problem associated with the procedure of kyphoplasty.

In our study, we observed that the median kyphosis angle was 21.8° before the procedure and decreased by a median of 6.7° following the surgery. 60% of the patients experienced a reduction in kyphosis by more than 5° (Interquartile range of 10°). In an analysis of this subgroup of patients, faster pain relief was achieved compared with patients who showed minimal to no reduction in the kyphotic angle. The VCFs were then examined on the basis of the spinal region (thoracic or lumbar) in which it occurred. 22 thoracic vertebral compression fractures were treated in 18 patients with a median improvement of 5.8° (range 0° to 17°) in sagittal alignment across the treated segments. Eighteen lumbar vertebral compression fractures were treated in 16 patients causing a 5.6° (range 0°-17°) median improvement in the angle of lordosis. If fractures that were considered reducible by BKP (defined as at least 5° improvement in sagittal alignment) were analyzed, 18 fractures in 18 patients showed an improvement in the sagittal alignment by 10° (range 6° to 17°). Statistical significance in the improvement of the sagittal angle from pre-operative to post-operative measurements reached the $p < 0.0001$ level (Wilcoxon signed-rank test) for all the fractures combined, thoracic fractures, lumbar fractures, and reducible fractures.

Long-term follow-up will be required to determine whether the improvement in spinal kyphosis will reduce the disability, morbidity, or risks of developing subsequent VCFs associated with kyphotic deformity from osteoporotic vertebral fractures. The clinical and radiographic results showed that the effects of BKP are immediate and dramatic, and showed no evidence of deterioration with time. Alleviation of pain, reduction in the use of pain medications, and improved mobility occurred within the first few post-operative days to weeks and remained stable for the entire length of the study.

Pain relief after BKP was rapid and evident within the first week following the procedure. The pain relief was sustained for upto 6 months after the procedure. Most patients also reported a return to the pre-fracture functional levels. This effect was ob-

served due to at least a 4-point decrease in the VAS pain score in 26 (87%) patients who achieved dramatic post-operative improvement whereas, in 2 cases, significant improvement was noted during the 3 months follow-up. On the other hand, 2 (7%) patients showed a further deterioration in the pain score. Twenty four (80%) patients showed constant improvement over a period of 6 months, suggesting further improvement in 7 patients following the 6 month period (23%).

There was a rapid and marked improvement in the QoL scores (ODI score) in this study. The mean pre-operative ODI score was 80, decreasing to 32 after 1 month postoperatively, and improving to 21 and 17 after the 3 month and the last follow-up, respectively.

The current study has several limitations. Firstly, the influence of the fracture etiology on the patient outcomes could not be assessed because of the relatively small number of subjects with secondary osteoporosis. Secondly, the current study, like most of the orthopedic literature on VCF treatment, lacks a control group. In 1999, one of the authors (S.R.G.) attempted to conduct a randomized controlled study comparing balloon kyphoplasty to non-operative care. Initiated at 39 US centers, this study was terminated after 2 years after having enrolled only 41 subjects. Although, the study was not extensive, a prominent improvement in pain and function after balloon kyphoplasty was evident relative to non-surgical care.²⁵ This study was undertaken to document the long-term benefits of balloon kyphoplasty in a large cohort, as recently suggested.²⁶

Davis et al²⁷ found that in women, a prevalent vertebral fracture increases the risk of incidence of fractures anywhere in the spine by 30%. However, if the prevalence fracture was in L2-L5, the odd ratio increased from 1.3 to 5.7 compared to women with no prevalent fracture. Their results suggested that the increased risk of fracture in women with prevalent fractures extends beyond the nearby vertebrae, which can affect the vertebrae both above and below the prevalent fracture. Existing fractures are strong and independent predictors of the risk of future vertebral fractures.²⁷ Thus, the vertebra adjacent to the site of cement injection is at no higher risk of fracture than any other vertebrae. The authors discuss three reasons as to why a prevalent fracture increases the risk of incident fracture.

First, the prevalent fracture is an indicator of impaired bone strength. Second, the loading is altered and third, the prevalent fractures are also due to other risk factors for developing fractures, such as falling.

Jenson and Dion²⁸ studied 109 patients with 174 fractures retrospectively and found no statistical difference in the rate of adjacent level fractures between patients who returned with new fractures following vertebroplasty and a control group consisting of patients who presented with multiple fractures of the same acuteness.

Additionally, some investigators have suggested that vertebral body augmentation may alter stiffness, leading to an in-

creased risk of subsequent adjacent-level VCFs. However, the bio-mechanical basis for this theory is poorly documented.²⁹⁻³¹

As our patient population was so small and the duration period of follow-up was relatively short, we were not able to conclude anything definite about the problem of adjacent-level fractures.

In our study, evaluation of intra-operative and post-operative radiographs revealed extra vertebral cement leaks in 11 (27%) of the 41 vertebral fractures treated. From our experience, it seems that the use of BKP limits the occurrence of extravasation supported by our results indicating reduced extravasation than that reported by conventional vertebroplasty.

Many theories about extravasation during the osteoporotic vertebral fractures augmentation continue to exist. During vertebroplasty and kyphoplasty, a bone filler is introduced into the fractured vertebral body to stabilize the fracture. For vertebral augmentation procedures, PMMA has been the most widely used bone filler, and most of the serious complications reported are related to the leakage of PMMA outside the confines of the vertebral body during injection.³²

The PMMA may exit the vertebral body through deficiencies or fractures in the vertebral cortex or by injection of the cement into the vertebral venous system.²⁶ Leakage of the cement through the vertebral cortex may result in direct injury to or compression of the adjacent structures such as the spinal cord.

When injected cement enters the venous system, it has the potential to fill the epidural veins and cause spinal cord or nerve root compression, or PMMA pulmonary embolism.³³

In addition, high-pressure interosseous injection of cement may lead to embolization of methylmethacrylate monomer and bone marrow contents of the lungs, with negative cardiopulmonary sequelae.^{29,34-37} Pressurization of PMMA during joint arthroplasty surgery has been associated with occasional cardiovascular collapse. During vertebroplasty, the high-pressure injection of low-viscosity cement directly into cancellous bone makes it difficult to control the cement flow in the vertebral body, thus creating an unpredictable risk of cement extravasation outside the vertebral body. In fact, extra vertebral cement extravasation commonly is seen during vertebroplasty. However, proponents of this technique have reported infrequent clinical sequelae of the leakage.

Kyphoplasty is an attempt to address the shortcomings of vertebroplasty (i.e., the inability to correct spinal deformity and high-pressure injection of cement into the fractured vertebral body). During kyphoplasty, the creation of an intervertebral cavity with the increasing block tariffs (IBTs) allows for a range of filler options, placing it under lower pressure.

In addition, the IBT compacts the trabecular bone, which may seal potential osseous or venous leak paths. When PMMA is used, it can be placed in the partially cured (viscous) form into the created cavity, which may reduce the risk of leakage.

Cadaver and clinical studies support the evidences of reduced leakage rate with kyphoplasty. Belkoff et al³⁸ reported extravertebral PMMA (Simplex P) leakage in 5 of the 8 fractured human cadaveric vertebral bodies treated with vertebroplasty, with no cement leakage seen in the fractured vertebra treated with kyphoplasty.

In a similar cadaver model, Belkoff et al³⁸ reported that when vertebroplasty was performed with the cement of varying materials, cement leaks occurred in 8 of the 12 treated vertebral bodies.

In a clinical Phase 1 efficacy study, Lieberman et al¹⁹ reported 30 patients who had osteopenic VCFs treated with kyphoplasty at 70 vertebral levels and noted extravertebral cement leakage at six levels (8.6%). No neurological complications occurred.

In a report of the initial 1471 VCFs treated with kyphoplasty in the United States, only one case of neurologic compromise related to cement intrusion into the spinal canal or neural foramen was mentioned.¹⁶ With the vertebroplasty contrast injection, cement leakage was observed through the vertebral cortex in 60% of the injections, raising a concern for direct PMMA leakage outside the bony spine.

CONCLUSION

In this study, all PMMA extravasations were asymptomatic; the cement remained in the immediate vicinity of the treated vertebrae. Forty one fractures were treated with BKP. The failure of balloon distension occurred in 6 fractures (14%) which were managed with conventional vertebroplasty and the exact cause behind that is still unclear. But, we can conclude from our experience, the possible causes behind a similar situation. Firstly, when the balloons were inserted in long standing old fractures (more than 2 months), tight ligaments and fibrosed disc spaces prevent the inflation of the balloon. Secondly, when the balloons were not inserted into the fractured area. Finally, when the balloons ruptured due to bone spikes.

CONFLICTS OF INTEREST

The authors declare that they have no conflicts of interest.

REFERENCES

1. Cook DJ, Guyatt GH, Adachi JD, et al. Quality of life issues in women with vertebral fractures due to osteoporosis. *Arthritis Rheum.* 1993; 36: 750-756. doi: [10.1002/art.1780360603](https://doi.org/10.1002/art.1780360603)
2. Kado DM, Browner WS, Palermo L, Nevitt MC, Genant HK, Cummings SR. Vertebral fractures and mortality in older women. *Arch Intern Med.* 1999; 159: 1215-1220. doi: [10.1001/archinte.159.11.1215](https://doi.org/10.1001/archinte.159.11.1215)
3. Lyles KW, Gold DT, Shipp KM, Pieper CF, Martinez S, Mulhausen PL. Association of osteoporotic vertebral fractures with

- impaired functional status. *Am J Med.* 1993; 94: 595-601. doi: 10.1016/0002-9343(93)90210-G
4. Silverman SL. The clinical consequences of vertebral compression fracture. *Bone.* 1992; 13(suppl 2): 27-31. doi: 10.1016/8756-3282(92)90193-Z
5. Berlemann U, Franz T, Orler R, Heini PF. Kyphoplasty for treatment of osteoporotic vertebral fractures: A prospective non-randomized study. *Euro Spine J.* 2004; 13: 496-501. doi: 10.1007/s00586-004-0691-7
6. Garfin SR, Yuan HA, Reiley MA. New technologies in spine: Kyphoplasty and vertebroplasty for the treatment of painful osteoporotic compression fractures. *Spine.* 2001; 26: 1511-1515. Web site. http://journals.lww.com/spinejournal/Abstract/2001/07150/New_Technologies_in_Spine__Kyphoplasty_and.2.aspx. Accessed May 2, 2017.
7. Lieberman IH, Dudeney S, Reinhardt MK, et al. Initial outcome and efficacy of kyphoplasty in the treatment of painful osteoporotic vertebral compression fractures. *Spine.* 2001; 26: 1631-1638. Web site. http://journals.lww.com/spinejournal/Abstract/2001/07150/Initial_Outcome_and_Efficacy_of__Kyphoplasty__in.26.aspx. Accessed May 2, 2017.
8. Taylor RS, Fritzell P, Taylor RJ. Balloon kyphoplasty in the management of vertebral compression fractures: An updated systematic review and meta-analysis. *Eur Spine J.* 2007; 16: 1085-1100. doi: 10.1007/s00586-007-0308-z
9. Cooper C, Atkinson EJ, O'Fallon WM, Melton JL 3rd. Incidence of clinically diagnosed vertebral fractures: A population-based study in Rochester, Minnesota, 1985-1989. *J Bone Miner Res.* 1992; 7: 221-227. doi: 10.1002/jbmr.5650070214
10. Melton LJ 3rd, Kan SH, Frye MA, Wahner HW, O'Fallon WM, Riggs BL. Epidemiology of vertebral fractures in women. *Am J Epidemiol.* 1989; 129: 1000-1011. doi: 10.1093/oxfordjournals.aje.a115204
11. Coumans JV, Reinhardt MK, Lieberman IH. Kyphoplasty for vertebral compression fractures: 1-year clinical outcomes from a prospective study. *J Neurosurg Spine.* 2003; 99: 44-50. doi: 10.3171/spi.2003.99.1.0044
12. American Academy of Orthopedic Surgeons (AAOS). The treatment of symptomatic osteoporotic spinal compression fractures: Guideline and evidence report (v1.1_033111). Rosemont, IL, USA: American Academy of Orthopaedic Surgeons; 2010. Web site. <http://www.aaos.org/Research/guidelines/SCFguide-line.pdf>. Accessed May 2, 2017.
13. Riggs BL, Melton LJ 3rd. The worldwide problem of osteoporosis: insights afforded by epidemiology. *Bone.* 1995; 17(Suppl 15): 505S-511S. doi: 10.1016/8756-3282(95)00258-4
14. Schofer MD, Efe T, Timmesfeld N, Kortmann HR, Quante M. Comparison of kyphoplasty and vertebroplasty in the treatment of fresh vertebral compression fractures. *Arch Orthop Trauma Surg.* 2009; 129: 1391-1399. doi: 10.1007/s00402-009-0901-1
15. Trumes E. Osteoporosis. *Spine.* 2001; 26: 930-932.
16. Garfin SR, Yuan HA, Reiley MA. Kyphoplasty and vertebroplasty for the treatment of painful osteoporotic compression fractures. *Spine.* 2001; 26(14): 1511-1515.
17. Wong W, Riley MA, Garfin S. Vertebroplasty/kyphoplasty. *J Womens Imaging.* 2000; 2: 117-124.
18. Compression fractures. *J Bone Miner Res.* 18: 24-29.
19. Lieberman IH, Dudeney S, Reinhardt HK, Bell G. Initial outcome and efficacy of kyphoplasty in treatment of painful osteoporotic vertebral compression fractures. *Spine.* 2001; 26(14): 1631-1638. Web site. http://journals.lww.com/spinejournal/Abstract/2001/07150/Initial_Outcome_and_Efficacy_of__Kyphoplasty__in.26.aspx. Accessed May 2, 2017.
20. Dudeney S, Lieberman IH, Reinhardt MK, Hussein M. Kyphoplasty in the treatment of osteolytic vertebral compression fractures as a result of multiple myeloma. *J Clin Oncol.* 2002; 20: 2382-2387. doi: 10.1200/JCO.2002.09.097
21. Theodorou DJ, Theodorou SJ, Duncan TD, Garfin SR, Wong WH. Percutaneous balloon kyphoplasty for the correction of spinal deformity in painful vertebral body compression fractures. *Clin Imaging.* 2002; 26: 1-5. doi: 10.1016/S0899-7071(01)00350-3
22. Coumans JV, Reinhardt MK, Lieberman IH. Kyphoplasty for vertebral compression fractures: 1-year clinical outcomes from a prospective study. *J Neurosurg.* 2003; 99(Suppl 1): 44-50. doi: 10.3171/spi.2003.99.1.0044
23. Sato K, Kikuchi S, Yonezawa T. In vivo intradiscal pressure measurement in healthy individuals and in patients with ongoing back problems. *Spine.* 1999; 24: 2468-2474. Web site. http://journals.lww.com/spinejournal/Abstract/1999/12010/In_Vivo_Intradiscal_Pressure_Measurement_in.8.aspx. Accessed May 2, 2017.
24. Wilke HJ, Neef P, Caimi M, Hoogland T, Claes LE. New in vivo measurements of pressures in the intervertebral disc in daily life. *Spine.* 1999; 24: 755-762. web site. <http://journals.lww.com/spinejournal/Abstract/1999/04150/New-In-Vivo-Measurements-of-Pressures-in-the.5.aspx>. Accessed May 2, 2017.
25. Gaitanis I, Hadjipavlou A, Katonis P, Tzermiadianos MN, Pasku DS, Patwardhan AG. Balloon kyphoplasty for the treatment of pathological vertebral compressive fractures. *Eur Spine J.* 2005; 14: 250-60. doi: 10.1007/s00586-004-0767-4
26. Keller RB, Atlas SJ. Is there a continuing role for prospective observational studies in spine research? *Spine.* 2005; 30: 847-849. Web site. <http://journals.lww.com/spinejournal/>

- Citation/2005/04150/Is_There_a_Continuing_Role_for_Prospective.2.aspx. Accessed May 2, 2017. 10.1080/02841850410005615
27. Davis JW, Grove JS, Wasnich RD, Ross PD. Spatial relationships between prevalent and incident spine fractures. *Bone*. 1999; 24: 261-264. doi: 10.1016/S8756-3282(98)00176-8
28. Jensen ME, Dion JE. Percutaneous vertebroplasty in the treatment of osteoporotic compression fractures. *Neuroimaging Clin North Am*. 2000; 10: 547-568.
29. Hallberg I, Rosenqvist AM, Kartous L, Löfman O, Wahlström O, Toss G. Health-related quality of life after osteoporotic fractures. *Osteoporosis Int*. 2004; 15: 834-841. doi: 10.1007/s00198-004-1622-5
30. Komp M, Ruetten S, Godolias G. Minimally invasive therapy for functionally unstable osteoporotic vertebral fracture by means of kyphoplasty: Prospective comparative study of 19 surgically and 17 conservatively treated patients. *J Miner Stoffwech*. 2004; 11(Suppl 1): 13-15.
31. Kasperk C, Hillmeier J, Noldge G, et al. Treatment of painful vertebral fractures by kyphoplasty in patients with primary osteoporosis: A prospective non randomized controlled study. *J Bone Miner Res*. 2005; 20: 604-612. doi: 10.1359/JBMR.041203
32. Kim SH, Kang HS, Choi JA, Ahn JM. Risk factors of new compression fractures in adjacent vertebrae after percutaneous vertebroplasty. *Acta Radiol*. 2004; 45: 440-445. doi: 10.1080/02841850410005615
33. Moreland DB, Landi MK, Grand W. Vertebroplasty: Techniques to avoid complication. *Spine J*. 2001; 1: 65-70. doi: 10.1016/S1529-9430(01)00013-4
34. Markel DC, Femino JE, Farkas P, Markel SF. Analysis of lower extremity embolic material after total knee arthroplasty in a canine model. *J Arthroplasty*. 1999; 14(2): 227-232. doi: 10.1016/S0883-5403(99)90131-6
35. Orsini EC, Byrick RJ, Mullen JB, Kay JC, Waddell JP. Cardiopulmonary function and pulmonary micro-emboli during arthroplasty using cemented or non-cemented components: The role of intra-medullary pressure. *J Bone Joint Surg Am*. 1987; 69: 822-832.
36. Pinto PW. Cardiovascular collapse associated with the use of methylmethacrylate. *AANA J*. 1993; 61: 613-616.
37. Rudigier JF, Ritter G. Pathogenesis of circulatory reactions triggered by nervous reaction during the implantation of bone cements. *Res Exp Med*. 1983; 183: 77-94. doi: 10.1007/BF01851774
38. Belkoff SM, Mathis JM, Jasper LE, et al. An ex vivo biomechanical evaluation of a hydroxyapatite cement for use with vertebroplasty. *Spine*. 2001; 26: 1542-1546. Web site: http://journals.lww.com/spinejournal/Abstract/2001/07150/An_Ex_Vivo_Bio-mechanical_Evaluation_of_a.8.aspx. Accessed May 2, 2017.