

Research

*Corresponding author

Lorenzo Dioscoridi, MD

Department of Surgery and Translational Medicine

University of Florence

Florence, Italy

E-mail: dioscoridi.lorenzo@virgilio.it

Volume 1 : Issue 1

Article Ref. #: 1000POJ1104

Article History

Received: November 7th, 2015

Accepted: December 1st, 2015

Published: December 3rd, 2015

Citation

Dioscoridi L, Sordi S, Breschi L, Fortuna D, Paparozzi C, Bechi P. Evaluation of the best power setting of laser waves in pancreatic surgery: ECHO ND-YAG laser ablation on bovine pancreatic tissue. *Pancreas Open J.* 2015; 1(1): 9-13. doi: [10.17140/POJ-1-104](https://doi.org/10.17140/POJ-1-104)

Copyright

©2015 Dioscoridi L. This is an open access article distributed under the Creative Commons Attribution 4.0 International License (CC BY 4.0), which permits unrestricted use, distribution, and reproduction in any medium, provided the original work is properly cited.

Evaluation of the Best Power Setting of Laser Waves in Pancreatic Surgery: ECHO ND-YAG Laser Ablation on Bovine Pancreatic Tissue

Lorenzo Dioscoridi^{1*}, Silvia Sordi¹, Luca Breschi², Damiano Fortuna³, Carlo Paparozzi¹ and Paolo Bechi¹

¹Department of Surgery and Translational Medicine, University of Florence, Florence, Italy

²Elesta srl., El.En. Group, Via Baldanzese 17, Calenzano 50041, Firenze, Italy

³Photobiolab Research Unit, El.En. Group, Via Baldanzese 17, Calenzano 50041, Firenze, Italy

ABSTRACT

Background: Pancreatic surgery is one of the most difficult and life-threatening surgical therapy especially during necrotizing pancreatitis and advanced solid neoplasms.

Aim of the study: To evaluate the possibility to use ECHO Neodymium-Doped Yttrium Aluminium Garnet (ND-YAG) laser in pancreatic surgery and to establish the best power setting for the application on pancreatic tissue.

Methods: An ECHO Laser ND-YAG 1064 nm, at the constant fluence of 1800 J/cm² was used. The laser waves were inserted inside of the samples with optical fibers of 500 micron diameter for a pre-established timing (11 min, 6 min, 4 min) in order to reach the constant fluence. Samples were, then, prepared for histological examination.

Results: At 3W power setting, the pancreatic tissue was not macroscopically modified except for an increased cutting consistency. Histological examination showed no substantial microscopical differences in pancreatic cells that appeared only partially burnt (in fact, nuclei and membranes are still recognizable). The vessels in the surrounding area have the normal morphological aspects.

At 5W, macroscopically the presence of a completely burnt area, corresponding to the site of direct interaction of laser and tissue, was found and the surrounding tissue did not appear substantially modified.

Histological examination showed the complete absence of cells in the burnt area and an important heat damage of the surrounding cells till the 2nd centimeter from the site of laser application. The vessels in the heat damage area appeared completely coagulated.

At the power of 7 W, the burnt area was about twice than in the previous setting and histological examination showed the complete absence of cells in the burnt area and a larger heat damage of the nearest cells (till the 4th centimeter from the application site). The vessels in heat damage area were found completely coagulated.

Conclusions: A power setting between 4 and 6 W have been found as the best one for laser application on pancreatic tissue because a complete destruction of the cells in the site of application but a limited heat damage in the surrounding healthy cells have been obtained.

KEYWORDS: Vessels; Surgery; Laser; Pancreatic cells.

ABBREVIATIONS: ND-YAG: Neodymium-Doped Yttrium Aluminium Garnet; ANP: Acute Necrotizing Pancreatitis; CT: Computed Tomography; H&E: Haematoxylin and Eosin.

BACKGROUND

Acute Necrotizing Pancreatitis (ANP) surgery is one of the hardest challenges in gen-

eral surgery.¹⁻⁸ Tissue is loose, friable and much vascularized; so, pancreatitis and major bleedings are well-described during surgery.¹

Approximately 20% of patients with acute pancreatitis develop pancreatic necrosis, and mortality rates up to 39% have been reported.¹⁻⁸ Surgical debridement (so-called necrosectomy) is the traditional management of necrotizing pancreatitis with specific indications.¹⁻⁹

In severe AP, current indications for surgery include the presence of infected pancreatic necrosis, extensive sterile necrosis in patients in whom symptoms have failed to resolve despite maximal conservative treatment or in patients who develop catastrophic complications related to pancreatic necrosis such as bleeding, visceral perforation or infarction.¹⁻⁸

The Computed Tomography (CT) evaluation of necrotic pancreatitis often show a superficial necrosis of the gland that contains vital tissue, this has led to gradually abandoning the performance of demolitive resection in favor of a treatment that combines the debridement of necrotic tissue associated with different draining techniques and postoperative cleaning procedures with open or closed packing.

These procedures are associated with a lower mortality and a lower rate of impairment of the functions of the endocrine and exocrine pancreatic gland compared to the demolitive ones (100% of diabetes in the surgical resection *versus* 52% post-necrosectomy).^{8,9}

Today the treatment of infected necrosis can be performed in both open and laparoscopic procedure even if it is preferred the classic technique followed by open-abdomen techniques in order to facilitate possible re-operations.

Pancreatic adenocarcinoma, commonly known as pancreatic cancer, represents the 12th most common type of cancer in the United States.¹ With a national age-adjusted incidence rate of 12.3 per 100,000, approximately 46,420 individuals were diagnosed with pancreatic cancer in 2014. Although the disease is relatively rare, pancreatic cancer is one of the most fatal cancers among adults in the United States. Pancreatic cancer has the lowest 5-year survival rate of any cancer, is the fourth leading cause of cancer death in the nation, and approximates breast cancer's death toll.

No major professional group recommends routine screening for pancreatic cancer; the natural history of the disease is not fully understood and current screening tools, including imaging modalities and serum biomarkers, are limited in diagnostic accuracy. Because screening is not recommended and the cancer typically develops with few symptoms, the majority of patients are diagnosed at an advanced stage. As an aggressive disease, the 5-year survival rate is <5%, and despite occasional cases of early disease detection, nearly all patients die from pan-

creatic cancer within 1-2 years.²

The main risk factors of pancreatic cancer include smoking, obesity, long-standing diabetes, and family history of disease. Cigarette smoking is the most well-established risk factor for pancreatic cancer. Smoking cigarettes causes a 75% increase in the risk of pancreatic cancer compared to non-smokers. Accordingly, 20% of pancreatic tumors may be attributed to cigarette smoking. Epidemiological investigations have also reported a 20-50% increased risk of disease among obese relative to no obese individuals. Although the relationship between diabetes and pancreatic cancer is complex, long-term type 2 diabetes has been associated with a significant increase in the risk of pancreatic cancer as well. Lastly, up to 10% of patients have a family history of pancreatic cancer, and the risk of disease is considerably greater (80%) among persons with affected family members compared to those without.¹

Promising data about the application of Neodymium Doped Yttrium Aluminium Garnet (ND-YAG) and CO₂ laser in clinical fields are available.^{10,11}

The use of ND-YAG laser in this kind of surgery could prove useful due to its ablative, antiseptic and hemostatic properties at the same time that would enable us to perform necrosectomies with a minimum invasiveness and without touching the inflamed tissue. Only few studies are disponsible in the international literature.¹⁰⁻¹³

AIM OF THE STUDY

The authors have focused the study on two main points:

1. To assess the viability of ND: YAG 1064 nm laser employment in the pancreatic surgery, particularly with regard to its possible application in necrosectomies for severe acute necrotizing pancreatitis.
2. To evaluate which are the best settings to achieve efficient ablation of the necrotic or tumoral areas intended as a thermal coagulation of the tissue and at the same time saving the surrounding healthy tissue.

Secondary endpoints are: To evaluate vessel damage due to laser application on pancreatic tissue (considering any interruption of the endothelial line).

MATERIALS AND METHODS

For this purpose, the authors used bovine pancreas on which different experimental settings were tested and subsequently evaluated both macroscopically and microscopically in order to show if the laser waves have performed a complete destruction of pancreatic cells in the site of application and how far the heat damage has arrived.

We have used the ECHO LASER 1064 ND-YAG with fluence of 1800 J and at increasing power settings: 3 W, 5 W and 7 W.

The laser waves were collected in the tissue with an optical fiber of 500 μ diameter inserted inside of the pancreatic tissue.

The timing of application was 11 minutes at the power of 3 W, 6 minutes at 5 W, 4 minutes at 7 W (that are the time needed to reach the fluence of 1800J).

Immediately after the laser application, all specimens were fixed in 10% neutral buffered formalin, dehydrated through a crescent ethanol series, embedded in paraffin, sectioned (3 micron thickness) and stained with Haematoxylin and Eosin (H&E) for examination with light microscope. All the specimens were analyzed by the same pathologist. H&E) for examination with a light microscope

RESULTS

We have analyzed 100 pancreatic bovine tissue samples without any pathological findings before laser application (Table 1).

Power (W)	N. samples	Time (min)	Area of burnt in mm ² (+/-)	Area of heat damage in mm ² (+/-)
3	33	11	0	1500(100)
5	34	6	70(20)	2000(130)
7	33	4	90(45)	4000(205)

Table 1: Mean value of area of burnt and area of heat damage at different power settings.

Direct observation of tissue samples after treatment with ECHO ND-YAG laser at the power setting of 3 W on 33 samples shows that the pancreatic tissues is not macroscopically modified except for the increased cutting consistency.

Histological examination shows no substantial microscopical differences in pancreatic cells that appear only partially burnt (in fact, nuclei and membranes are still recognizable). The

vessels around the point of application do not show microscopically any sign of damage.

Increasing the power of laser waves to 5 W on 34 samples, macroscopically the presence of an area, corresponding to the site of direct interaction of laser and tissue, completely burnt was found and the surrounding tissue did not appear substantially modified.

Histological examination shows the complete absence of cells in the burnt area (with a complete destruction of the lissome containing amylases) and an important heat damage of the surrounding cells (the authors think that this cells have been definitively compromised and are supposed to undergo apoptosis) till the 2th centimeter from the site of laser application. (Figure 1) The vessels around the point of application are all coagulated.

At the power of 7 W on 33 samples, the burnt area is obviously higher, about twice than in the previous setting.

Histological examination shows the complete absence of cells or any cell’s components (including lissome) in the burnt area and a larger heat damage of the nearest cells (till the 4th centimeter from the application site). The vessels around the point of application are, again, all coagulated. (Figure 2)

DISCUSSION

The results obtained in this study show how increasing laser power setting increases its effectiveness in coagulation and thermoablation of pancreatic tissue both *de visu* and microscopically: we have found that a power setting between 4 and 6 W could be acceptable for applications on pancreatic tissue.

Our data confirm the few ones already available in the international literature^{12,13} as we agree that the best power setting is between 4 W and 6 W. Moreover, we were able to find out why in the previous studies,¹² the authors found no hemorrhage: the laser waves, in fact, allow a complete coagulation of the vessels in the area of application.

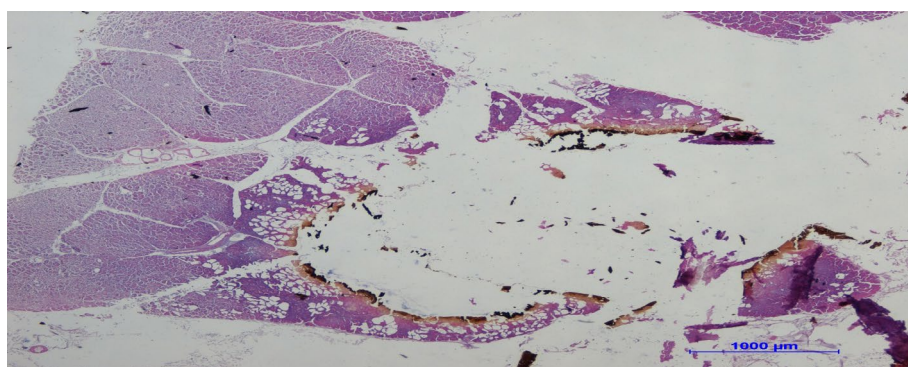


Figure 1: Site of application at the 5W setting. The burnt area (without colored cells, with black margins) and the surrounding area of heat damage (in which vacuolization is present) can be seen. In the distal part of the samples, a normal pancreatic tissue can be seen.

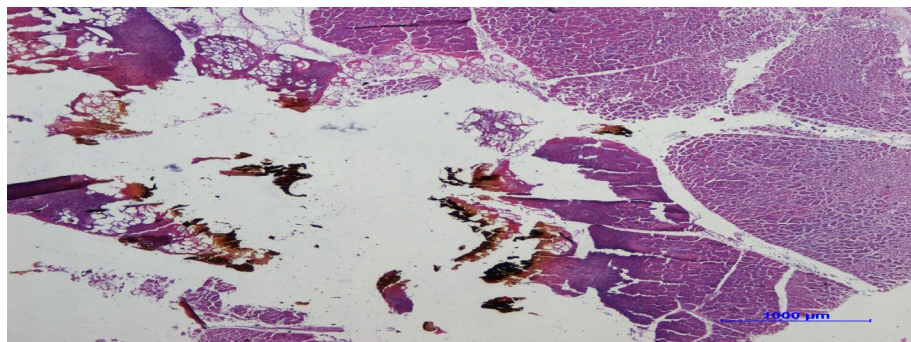


Figure 2: Site of application at 7W setting. The burnt area is in the central part (with some black group of necrotic material). The heat damage area is around with the typical vacuolization and it is wider than in the previous setting. Once again, in the marginal areas (upper part of the figure), normal tissue can be seen.

The main limitations of the present study are that this is an *ex vivo* study and not on human tissue. Despite the early stage of our research, we can assume that this new technique, once developed and optimized, can be used in many different ways and with interesting surgical applications (necrosectomy, thermoablation of solid not resectable neoplasm, biopsies of pancreatic tissues).

The main advantages in fact in this type of treatment are the possibility of an operating treatment without touching the parenchyma (*touch-sparing technique*) and the capability to ablation, coagulation and disinfection at the same time of the treated tissue (*aseptic thermoablative technique*). Moreover, the laser ablation is more defined than other types of thermoablation (i.e. radiofrequency) and this is important in order to save as much tissue as possible without damaging the healthy part of the organ. Further studies are needed to continue analyzing the interaction of laser waves on pancreatic tissue.

CONFLICTS OF INTEREST

The authors declare that they have no conflicts of interest.

CONSENT

No consent is required to our article publication regarding the paper "Evaluation of the best power setting of laser waves in pancreatic surgery: ECHO ND-YAG laser ablation on pancreatic tissue samples and its potential applications in necrosectomy and other pancreatic pathologies".

REFERENCES

1. UK Working Party on Acute Pancreatitis. UK guidelines for the management of acute pancreatitis. *Gut*. 2005; 54. doi: [10.1136/gut.2004.057026](https://doi.org/10.1136/gut.2004.057026)
2. Uhl W, Warshaw A, Imrie C, et al. IAP guidelines for the surgical management of acute pancreatitis. *Pancreatology*. 2002; 2: 565-573. doi: [10.1159/000067684](https://doi.org/10.1159/000067684)
3. Kimura Y, Takada T, Kawarada Y, et al. JPN guidelines for the management of acute pancreatitis: treatment of gallstone-induced acute pancreatitis. *J Hepatobiliary Pancreat Surg*. 2006; 13: 56-60. doi: [10.1007/s00534-005-1052-6](https://doi.org/10.1007/s00534-005-1052-6)
4. Banks PA, Freeman ML. Practice Parameters Committee of the American College of Gastroenterology. Practice guidelines in acute pancreatitis. *Am J Gastroenterol*. 2006; 101: 2379-2400. doi: [10.1111/j.1572-0241.2006.00856.x](https://doi.org/10.1111/j.1572-0241.2006.00856.x)
5. Chiang DT, Anozie A, Fleming WR, Kiroff GK. Comparative study on acute pancreatitis management. *ANZ J Surg*. 2004; 74: 218-221. doi: [10.1111/j.1445-2197.2004.02958.x](https://doi.org/10.1111/j.1445-2197.2004.02958.x)
6. Chiang DT, Thompson G. Management of acute gallstone pancreatitis: so the story continues. *ANZ J Surg*. 2008; 78: 52-54. doi: [10.1111/j.1445-2197.2007.04356.x](https://doi.org/10.1111/j.1445-2197.2007.04356.x)
7. Aly EAH, Milne R, Johnson CD. Non-compliance with national guidelines in the management of acute pancreatitis in the United Kingdom. *Dig Surg*. 2002; 19: 192-198.
8. Foitzik T, Klar E. (Non-)Compliance with guidelines for the management of severe acute pancreatitis among German surgeons. *Pancreatology*. 2007; 7: 80-85. doi: [10.1159/000101882](https://doi.org/10.1159/000101882)
9. Banks PA, Freeman ML. Practice Parameters Committee of the American College of Gastroenterology. Practice guidelines in acute pancreatitis. *Am J Gastroenterol*. 2006; 101: 2379-2400. doi: [10.1111/j.1572-0241.2006.00856.x](https://doi.org/10.1111/j.1572-0241.2006.00856.x)
10. Tóth T, Bátorfi J. The potentials of CO₂ laser in the surgery of the liver, biliary tract and pancreas. *Acta Chir Hung*. 1991; 32(1): 39-44.
11. Joffe SN. Contact YAG laser system in abdominal surgery, in particular hepatic and pancreatic surgery. *Semin Surg Oncol*. 1989; 5(1): 48-56.
12. Di Matteo F, Martino M, Rea R, et al. US-guided application of ND-YAG laser in porcine pancreatic tissue: an *ex vivo* study

and numerical simulation. *Gastrointest Endosc.* 2013; 78: 750-755. doi: [10.1016/j.gie.2013.04.178](https://doi.org/10.1016/j.gie.2013.04.178)

13. Di Matteo F, Martino M, Rea R, et al. EUS-guided ND-YAG laser ablation of normal pancreatic tissue: a pilot study in a pig model. *Gastrointest Endosc.* 2010; 72: 358-356. doi: [10.1016/j.gie.2010.02.027](https://doi.org/10.1016/j.gie.2010.02.027)