


**Case Report**

# Potential Application of Pre-Induction Scalp Block in High-Risk Neurosurgical Procedures in a von Hippel-Lindau Disease Patient

Anjali Singh, MD;  Uma Hariharan, MBBS, DNB\*; Jyoti Singh, MD; Neerja Banerjee, MD

Department of Anaesthesia, Dr RML Hospital and ABVIMS, New Delhi, India

\*Corresponding author

Uma Hariharan, MBBS, DNB

Associate Professor, Department of Anaesthesia, Dr RML Hospital and ABVIMS, New Delhi, India; E-mail: [uma1708@gmail.com](mailto:uma1708@gmail.com)**Article information**Accepted: March 10<sup>th</sup>, 2025; Published: March 20<sup>th</sup>, 2025**Cite this article**Singh A, Hariharan U, Singh J, Banerjee N. Pre-induction scalp block in a patient of von hippel-lindau disease: promising use in high-risk neurosurgical procedures. *Res Pract Anesthesiol Open J.* 2025; 9(1): 5-7.**ABSTRACT**

Multiple modalities have been tried for post-craniotomy pain relief, but controversy exists as to the optimal approach. Pre-induction scalp block is a promising technique in high-risk neurosurgical procedures, which reduces the haemodynamic response to skull pin insertion and craniotomy incision, and affords post-operative analgesia. von hippel-lindau (VHL) disease is a rare autosomal dominant disorder with multi-system involvement and various visceral manifestations, the most common of these-being cerebellar hemangioblastoma. Other anomalies include pancreatic-renal cysts, erythrocytosis, hypernephroma, pheochromocytoma and retinal capillary hemangioblastoma. Central nervous system (CNS) hemangioblastomas are often an early manifestation of the disease, and are typically seen in the second decade of life. The majority of hemangioblastomas occur in the cerebellum followed by the spinal cord and brain stem. They are benign vascular tumours but can cause neurological symptoms secondary to pressure or haemorrhage. We hereby present a case of previously diagnosed VHL with recurrent cerebellar hemangioblastoma scheduled for neurosurgical tumour excision and the beneficial use of a pre-induction scalp block to compliment anaesthesia for the patient.

**Keywords**

Peri-operative anaesthesia; Neurosurgery; Pheochromocytoma; Cerebellar hemangioblastoma; Scalp block; VHL disease.

**INTRODUCTION**

Von hippel-lindau (VHL) syndrome is a disease with multisystem involvement.<sup>1</sup> Coordination of efforts between various medical and surgical specialities is crucial for patient management. Although rare, hemangioblastomas in VHL syndrome, which can occur repeatedly over the patient's lifetime, can be potentially lethal if not treated with surgical excision, which is the definitive treatment in majority of cases. Coexistence of other tumours like pheochromocytoma, spinal cord tumors, renal tumours and cystic lesions can make the anaesthetic management of such patients more challenging.<sup>2</sup> A thorough pre-anaesthetic assessment to rule out co-existing lesions and attention to peri-operative pain management is vital for optimal patient outcomes. Pre-induction scalp blocks have been shown to enhance peri-operative analgesia and hemodynamic stability.<sup>3,4</sup>

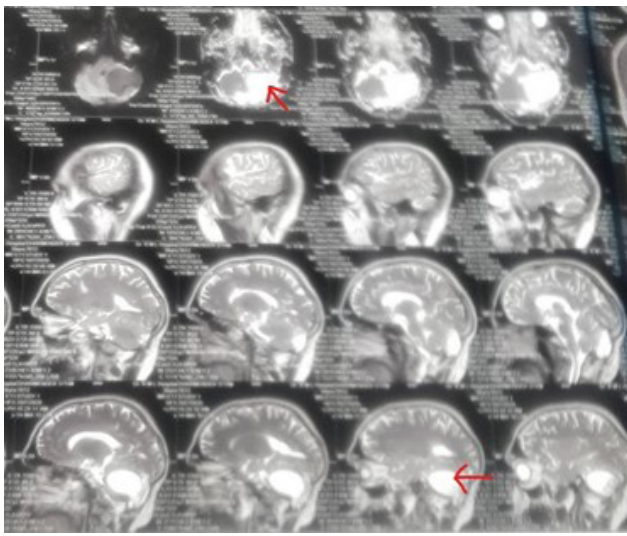
**CASE PRESENTATION**

A 27-year-old male presented with complaints of difficulty in standing and walking, vertigo, vomiting and headache for the past

6-months. The patient carried a diagnosis of VHL disease with a *3p gene* deletion. He had successfully undergone a midline sub-occipital craniotomy with tumour decompression of a left cerebellar tumour under general anaesthesia (without pre-induction scalp block), 8-years previously for similar complaints.

In pre-anaesthetic evaluation, he was hemodynamically stable with a normal neurologic exam and a Glasgow scale of 15/15. Airway examination was normal. The patient had no complaints suggestive of end-organ damage or any features suggestive of occult pheochromocytoma. All blood investigations were normal, except for erythrocytosis, which is a common finding in patients with VHL. An electrocardiogram (ECG) showed a normal sinus rhythm with no signs of left ventricular hypertrophy or strain. Respiratory and cardiovascular system involvement was ruled out with a normal chest X-ray and screening 2D Echo. Contrast-enhanced magnetic resonance imaging (CE-MRI) of the brain revealed a well-defined lesion of size 3×5.5 cm in the left cerebellar hemisphere along with old gliotic, post-operative changes in the left cerebellar region and left occipital bone (Figure 1).

**Figure 1.** Red Arrow Depicting Cerebellar Mass



Cranial nerve examination revealed a partially impaired gag reflex along with presence of cerebellar signs like nystagmus, dysdiadochokinesis, ataxia and intention tremors. The patient was scheduled for a left paramedian suboccipital craniotomy with tumour excision and lax duroplasty under general anaesthesia with supplemental pre-incisional scalp block.

The patient was premedicated with a per oral sedative anxiolytic. In the operating room, after attaching standard American Society of Anesthesiologists (ASA) monitors, an 18 G intravenous cannula was secured. Following this a pre-induction scalp block was performed. The Auriculotemporal, Greater Occipital and Lesser Occipital Nerves were blocked using 3-4 ml of 0.5% Bupivacaine with epinephrine (5 µg/ml of 1:200000) using landmark technique.<sup>5</sup> Thereafter, the patient was placed in supine position and administered a standard intravenous induction with Midazolam (1 mg), Fentanyl (100 µg), Etomidate (18 mg) and Rocuronium bromide (35 mg). Patient was intubated with a cuffed flexo-metallic endotracheal tube of size 8.0 mm ID and bilateral air entry checked. Using aseptic precautions, the left radial artery was cannulated using Seldingers technique for continuous invasive blood pressure monitoring and arterial blood gas analysis. The right internal jugular vein was also cannulated using a 7 Fr triple lumen catheter for central venous pressure monitoring. Another 16 G intravenous cannula was secured. Thereafter, the patient was placed in prone position, taking care to avoid abdominal compression along with padding of all bony prominences. The hemodynamic variables were monitored and their variations noted during skull pin insertion as well as scalp incision and dissection. Anaesthesia was maintained with oxygen, air and Isoflurane. The surgery lasted for 3-hours and total blood loss was 1 litre. Intravenous fluid replacement included 2 litres of lactated Ringers and 2 units of packed red blood cells (packed red blood cells (pRBCs) transfusion). The hemodynamic variables were maintained within normal limits peri-operatively. No additional opioids or analgesics were given intra-operatively, apart from 1 g Paracetamol (intravenous).

Extubation following standard reversal was uneventful. He recovered well in the post-anaesthesia care unit and then was transferred to the intensive care unit (ICU) for further monitoring in the post-operative period. Patient had stable hemodynamics and vital signs throughout the recovery period and required minimal post-operative analgesics prior to discharge from the medical center.

## DISCUSSION

In addition to a detailed pre-anaesthetic evaluation to exclude other tumours (especially pheochromocytoma), maintenance of stable peri-operative hemodynamics is important in these patients to minimize blood loss and the risk of post-operative neurologic sequelae. Many patients with VHL undergo craniotomies and pain following craniotomy may often be overlooked. Nearly 60% of these patients experience moderate to severe pain. Unrelieved somatic pain can cause increase in catecholamine release and oxygen consumption resulting in brain hyperemia and raise intracranial pressure, which may contribute to post-operative complications and prolong hospital stay.<sup>6</sup> Hypertension in post-operative period can precipitate intracranial haemorrhage and further compromise the neurological status of the patient.<sup>7</sup>

Multiple modalities have been tried for post-craniotomy pain relief, but controversy exists as to what approach is optimal. Opioid use is common but may be accompanied by excessive sedation which can mask onset of a new neurological deficit. Respiratory depression, hypercarbia, increased intracranial pressure and delayed weaning from ventilator are other concerns associated with opioid analgesic use.

In our patient, we used Bupivacaine 0.5% to block the nerves supplying the posterior scalp, prior to induction of general anaesthesia, which proved beneficial. Firstly, during head pin insertion for stabilising the head and neck for surgery, there was minimal variation in heart rate and blood pressure.<sup>8</sup> No additional opioid dosing, apart from that used for induction of anaesthesia, or increased inhalational agent use was required during head pin fixation, contributing to preventing undesired sudden hypotension. Stable hemodynamic parameters were observed throughout the surgical procedure. No additional intravenous analgesics were given beyond the induction dose of fentanyl (100 µ) and paracetamol. Secondly, the scalp block appeared to provide adequate post-operative analgesia to the patient and aided accurate neurological assessment following surgery. In addition, the use of scalp block decreased the frequency of request for rescue analgesia, while increasing the time between completion of surgery and the first request of analgesic by the patient which was 8 hours post-operatively.<sup>7</sup> Another advantage of scalp block is a reduced risk of nerve damage, as the nerves blocked are superficial terminal branches.<sup>8</sup> Observation of decreased pain scores in the post-operative period promoted early patient ambulation and discharge. Scalp block is a useful method to maintain hemodynamic stability during craniotomy and contribute to peri-operative pain management as well.

## CONCLUSION

von hippel-lindau syndrome is a multisystem disease often produc-

ing multiple tumours as well as diffuse cystic lesions. Thorough pre-operative evaluation of these patients is of paramount importance. In this setting, the use of regional anaesthetic blockade with pre-induction scalp block is safe and can help in maintaining intraoperative hemodynamic stability by blunting the sympathetic response to stimulation. It can aid in perioperative management of patients undergoing craniotomies, including awake craniotomies, especially in high-risk population. Scalp block has been found to reduce post-craniotomy pain in the short-term, without any difference between using it pre-or-post-operatively.<sup>6</sup>

### CONSENT

The authors have received written informed consent from the patient.

### CONFLICTS OF INTEREST

The authors declare that they have no conflicts of interest.

### REFERENCES

1. Sriganesh K, Sinha PK, Koshy T, Rao S. Von Hippel Lindau Syndrome and Anaesthetic considerations. *Indian J Anaesth.* 2006; 50: 472-475.
2. Mugawar M, Purohit AK, Sastry RA, Sundaram C, Rammurthi S, Rajender Y. Anaesthetic management of von hippel lindau syndrome for excision of cerebellar hemangioblastoma and pheochromocytoma surgery. *Anesth Analg.* 1998; 86: 673-674. doi: [10.1213/00000539-199803000-00045](https://doi.org/10.1213/00000539-199803000-00045)
3. Schmid S, Gillessen S, Binet I, et al. Management of von hippel lindau disease: An interdisciplinary review. *Oncol Res Treat.* 2014; 37: 761-771. doi: [10.1159/000369362](https://doi.org/10.1159/000369362)
4. Murthy TVSP, Gupta P, Prabhakar T, Singh P, Mohan C. Anaesthetic implication of von hippel landau disease. *Med J Armed Forces India.* 2006; 62: 181-183. doi: [10.1016/S0377-1237\(06\)80067-5](https://doi.org/10.1016/S0377-1237(06)80067-5)
5. Dsouza S, Sewell D. Scalp block: Techniques and applications. *Regional Anaesthesia.* 2022; 480: 1-8.
6. Yanting C, Jianqiang N, Xiang L, Jialei Z, Gang C. Scalp block for postoperative pain after craniotomy: A meta-analysis of randomized control trials. *Front Surg.* 2022; 9: 1018511. doi: [10.3389/fsurg.2022.1018511](https://doi.org/10.3389/fsurg.2022.1018511)
7. Haldar R, Kaushl A, Gupta D, Srivastava S, Singh PK. Pain following Craniotomy: Reassessment of the available options. *Biomed Res Int.* 2015; 2015: 509164: doi: [10.1155/2015/509164](https://doi.org/10.1155/2015/509164)
8. Osborn I, Sebeo MD, Sebeo J. Scalp block during craniotomy: A classic technique revisited. *J Neurosurg Anesthesiol.* 2010; 22: 187-194. doi: [10.1097/ANA.0b013e3181d48846](https://doi.org/10.1097/ANA.0b013e3181d48846)