

## Research

### Corresponding author

Tuğrul Demirel, MD

General Surgeon

Ardıçlı Golevleri, Kuru Cıkmazı Sk.

Istanbul, Turkey

Tel. +(90) 506 6885408

E-mail: [tugrul.demirel@gmail.com](mailto:tugrul.demirel@gmail.com)

Volume 4 : Issue 1

Article Ref. #: 1000SROJ4120

### Article History

Received: June 30<sup>th</sup>, 2017

Accepted: July 24<sup>th</sup>, 2017

Published: July 24<sup>th</sup>, 2017

### Citation

Demirel T, Ugale S. Ileal interposition with gastric bipartition and a weight-adjusted sleeve gastrectomy: A new model of metabolic surgery. *Surg Res Open J.* 2017; 4(1): 6-11. doi: [10.17140/SROJ-4-120](https://doi.org/10.17140/SROJ-4-120)

### Copyright

©2017 Demirel T. This is an open access article distributed under the Creative Commons Attribution 4.0 International License (CC BY 4.0), which permits unrestricted use, distribution, and reproduction in any medium, provided the original work is properly cited.

# Ileal Interposition with Gastric Bipartition and a Weight-Adjusted Sleeve Gastrectomy: A New Model of Metabolic Surgery

Tuğrul Demirel, MD<sup>1\*</sup>; Surendra Ugale, MD<sup>2</sup>

<sup>1</sup>Ardıçlı Golevleri, Kuru Cıkmazı Sk., Istanbul, Turkey

<sup>2</sup>Asian Bariatrics and Kirloskar Hospital, Hyderabad, India

## ABSTRACT

**Background:** Metabolic surgery for the treatment of type 2 diabetes patients, with body mass index (BMI) less than 35 kg/m<sup>2</sup> has been found to be increasing every year. Duodenoileal interposition with sleeve gastrectomy and transit bipartition (TB) has strong effects on control of type 2 diabetes mellitus. However, both procedures may have long-term problems. Due to duodenal exclusion, endoscopic evaluation of the duodenum and biliary tract becomes impossible after duodenoileal interposition. The TB may have the risk of severe malabsorption due to enlargement of the gastroileostomy. We performed ileal interposition and TB in patients with class 1 obesity having type 2 diabetes, with ethical approval. The new modification included in this paper, was performed in 3 patients, one of whom had a BMI of 30 kg/m<sup>2</sup>. The aim of this innovation is to treat obese (BMI >30 kg/m<sup>2</sup>), type 2 diabetes patients with an effective, but less malabsorptive procedure.

**Objectives:** The modification that we propose, aims to preserve normal duodenal anatomy and prevent possible duodenal transection related surgical problems and secure the absorptive component of proximal intestines without the need of an adjustment in gastroileostomy anastomosis.

**Materials and Methods:** All patients underwent total laparoscopic ileal interposition with gastric bipartition and a weight-adjusted sleeve gastrectomy.

**Results:** All three patients stopped insulin use after surgery. No complications occurred.

**Conclusions:** Ileal interposition with gastric bipartition and a weight-adjusted sleeve gastrectomy is a safe and effective procedure for treatment of type 2 diabetes patients with or without obesity.

**KEY WORDS:** Gastric bipartition; Weight-adjusted sleeve gastrectomy; Duodenoileal interposition; Transit bipartition; Type 2 diabetes; Metabolic surgery; Obesity; Gastroileostomy anastomosis.

**ABBREVIATIONS:** BMI: Body Mass Index; TB-SG: Transit bipartition with sleeve gastrectomy; OAD: Oral Anti Diabetic; ICV: Ileocecal valve; II-DSG: Interposition with diverted sleeve gastrectomy;

## INTRODUCTION

Metabolic surgery for type 2 diabetes patients with BMI <35 kg/m<sup>2</sup> is increasing every year with promising outcomes. However, the difficult learning curve is the prominent factor leading to very slow widespread acceptance.<sup>1</sup> Ileal interposition with diverted sleeve gastrectomy (II-DSG) has powerful metabolic effects, giving good control of type 2 diabetes and associated problems (Figure 1).<sup>2-22</sup> Transit bipartition with sleeve gastrectomy (TB-SG) has been getting increased acceptance due to its greater feasibility compared to II-DSG and the advan-

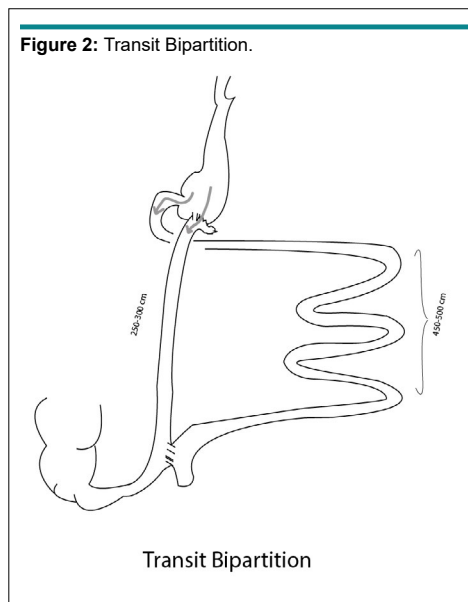
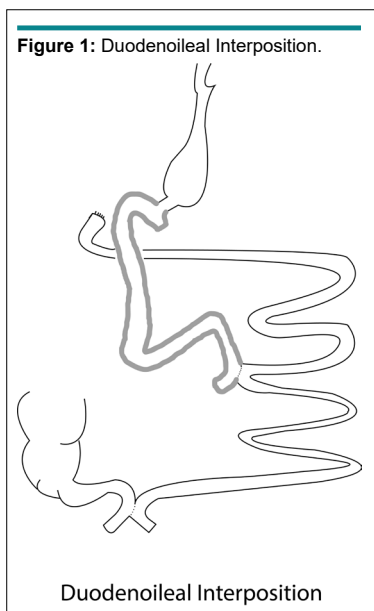
tage of preservation of the normal physiology and anatomy of duodenum; although, both procedures have some pros and cons. II-DSG patients have a bypassed duodenum which is important in eliminating the foregut’s negative incretin effects on insulin; however, this prevents any biliary access, if required later. TB-SG overcomes this problem by preserving the normal duodenal access, which makes the procedure more physiologic and easier to perform. With time, the gastroileal anastomosis has a tendency to enlarge resulting in “functional bypass” of duodenum, enhancing the anti-diabetic effect of the procedure. However, as the food is directed more into the ileum, greater malabsorption may occur which will be a severe risk for low BMI patients (Figure 2).

The modification that we propose is aimed at overcoming these factors by eliminating the risk of malabsorption and the inability to reach the duodenum endoscopically. As time

goes by, there is an increasing amount of food that is directed through the gastro-ileal anastomosis, causing functional bypass of the duodenum to diminish the foregut suppression on insulin without causing severe malabsorption due to redirection of food to proximal jejunum to be digested, mimicking normal anatomy. We present this report of the first 3 cases of this procedure in obese type 2 diabetic patients.

**MATERIALS AND METHODS**

All three patients were males, with ages 43, 45 and 56 years. They had been undergoing diabetes treatment for longer than 3 years with poor control of diabetes, having HbA1c >7.5 % with medical treatment and lifestyle modification. The first patient was using only oral anti-diabetic (OAD) treatment, while the other two were using insulin for more than a year besides OADs. The data of the patients are detailed in the Tables 1 and 2.



**Table 1: Pre-Operative Data.**

Patient	Age	BMI (kg/m <sup>2</sup> )	Diabetes Duration (Years)	Fasting Glucose (mg/dL)	PP Glucose (mg/dL)	Fasting C-Peptide (ng/ml)	PP C-Peptide (ng/ml)	HbA1c (%)	OAD	Insulin
1	45	40	8	189	284	3.79	5.90	9.6	Yes	No
2	56	37	6	190	273	4.15	5.52	9.7	Yes	1 y
3	43	30	9	296	349	2.86	3.19	10.2	Yes	2 y

BMI: Body Mass Index; PP: Post Prandial; OAD: Oral Anti-Diabetic Drugs.

**Table 2: Operative Data.**

Patient	Age	Gender	BMI (kg/m <sup>2</sup> )	Previous Surgery	Surgery time (min)	Discharge day	Complication
1	45	Male	40	No	198	4	No
2	56	Male	37	No	201	5	No
3	43	Male	30	No	178	4	No

BMI: Body Mass Index

The ileal interposition and transit bipartition (TB) was performed internationally. The procedure we propose is not a completely new procedure but a modification to the existing procedures (Figure 3). Thus, only a detailed informed consent was deemed necessary at our hospital. All of the patients were given detailed comparative information about the surgery, with the alternatives *via* videos, animations and pictures of the procedures. All three patients gave detailed informed consents prior to surgery.

Surgery was carried out after completing all the pre-operative preparations. The patients were placed in a supine position with legs spread and a reverse Trendelenburg at 30 degrees. Central venous catheter and arterial lines were then placed. We used a left paraumbilical port as usual for camera. A 15 mm trocar in the right upper quadrant and a 12 mm trocar in the left upper quadrant were placed for dissection and transections. A 5 mm trocar at the xyphoid for gastric mobilization and liver retraction and another 5 mm at the left lower quadrant for measurement of the bowels were placed. The dissection is started as usual for stomach mobilization on greater curvature. A 36 F bougie is used for calibration and to start transection. After the sleeve was performed, the staple line was oversewn with running 3/0 polydioxanone (PDS) suture. Then the table was set to neutral position for bowel preparation. The omentum was transected up to the transverse colon, enabling the ileal graft to be taken up in an antecolic fashion, with least tension. The complete small bowel was measured from the ligament of Treitz to the ileocecal valve (ICV) with a measuring grasper having marking at 10 cm. The jejunum was marked at 100 cm from the Treitz with double legged suture distally and thermal mark with harmonic scalpel proximally. The terminal ileum was transected at 40 and 200 cm from ICV. The distal end of the ileal segment was marked with a double legged suture and proximal end with a single legged one. The distal ileum and the proximal

bilio-pancreatic limb were staple anastomosed side-to-side and the mesenteric defect was closed with separate prolene sutures. The proximal end of the ileal segment was brought next to the antrum in an antecolic fashion. The ileum was fixed to the posterior wall of the antrum for 4-5 cm with interrupted sutures. The gastro-ileostomy is fashioned side-to-side with stapler and the staple orifice is closed with PDS 3/0 running suture. Leak tests were done with methylene blue dye to check the integrity of the gastro-ileal anastomosis.

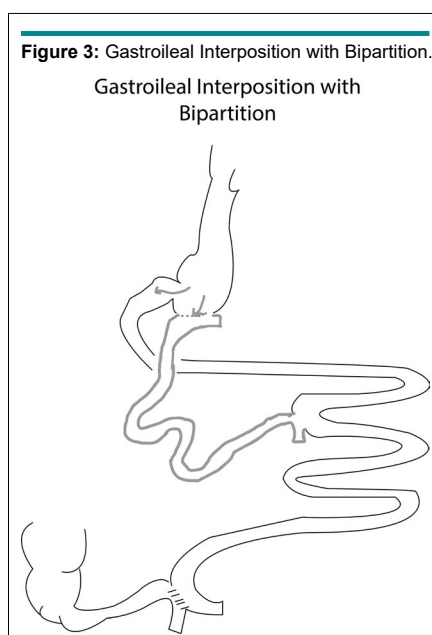
After the leak test, the Peterson's defect was closed with interrupted 3/0 prolene sutures. The last anastomosis was side-side between the distal end of the ileal segment and proximal 100 cm of jejunum from the Treitz. The mesenteric defect was again closed with interrupted 3/0 prolene sutures. A single drain was placed under the gastroileostomy. The patients were discharged on the 4<sup>th</sup>-5<sup>th</sup> post-operative days without any clinical problem.

## RESULTS

Patients were followed-up for early complications during the first 30 days after surgery and for the glycemic control at 1 and 3 months. No complications were observed in any of the patients. Data from patients were collected during the 30 and 90 days follow-ups. All patients achieved remission of diabetes with HbA1c <6.5 %, 90 days after surgery. The data of the 30 days and 90 days follow-ups are detailed in Tables 3 and 4.

## DISCUSSION

Type 2 diabetes is a condition prevalent ubiquitously, mostly linked with mild to severe obesity. Bariatric surgery has proven superiority over conservative treatments and lifestyle changes for patients with BMI >35 kg/m<sup>2</sup>. The promising results of



**Table 3:** Post-Operative 30 Days Data.

Patient	Duration (Days)	BMI (kg/m <sup>2</sup> )	% Excess BMI Loss (%EBMIL)	% Total Body Weight Loss (% TBWL)	Fasting Glucose (mg/dL)	PP Glucose (mg/dL)	HbA1c (%)	OAD	Insulin
1	30	33.8	15 %	15%	110	140	6.9	No	No
2	30	32.6	11 %	12 %	116	107	6.7	No	No
3	30	27.4	11 %	10 %	139	142	8.9	No	No

BMI: Body Mass Index; %EBMIL: Percentage Excess Body Mass Index Loss; % TBWL: Percentage Total Body Weight Loss; PP: Post Prandial; OAD: Oral Anti-Diabetic Drugs.

**Table 4:** Post-Operative 3 Months Data.

Patient	Duration	BMI (kg/m <sup>2</sup> )	% Excess BMI Loss (%EBMIL)	% Total Body Weight Loss (% TBWL)	Fasting Glucose (mg/dL)	PP Glucose (mg/dL)	HbA1c (%)	OAD	Insulin
1	3 months	27.4	31 %	30%	110	90	6.4	No	No
2	3 months	28.2	21 %	21 %	85	103	5.9	No	No
3	3 months	26	16 %	17 %	90	98	5.8	No	No

BMI: Body Mass Index; %EBMIL: Percentage Excess Body Mass Index Loss; % TBWL: Percentage Total Body Weight Loss; PP: Post Prandial; OAD: Oral Anti-Diabetic Drugs.

bariatric surgery, in obesity related diabetes amongst morbidly obese and class II obese patients (BMI >35 kg/m<sup>2</sup>), had triggered the search for treatment of diabetes associated with severe insulin resistance and/or insulinopenia in patients with BMI <35 kg/m<sup>2</sup>. Although, the classical bariatric procedures might have good results to some extent, the purely restrictive techniques lack sufficient glycemic control, while malabsorptive techniques carry the risk of severe malnutrition. II-DSG surgery, proposed by De Paula et al had opened a new era for effective “non-malabsorptive” metabolic surgical option for low BMI diabetic patients.

De Paula et al<sup>2</sup> briefly explained and showed the “neuroendocrine ileal brake” mechanism which strongly supports the hind-gut hypothesis with promising results in type 2 diabetes. The technique is challenging and has a long learning curve to be safely practiced and therefore, has not gained widespread acceptance. TB proposed by Santoro et al<sup>21</sup> has a simpler technique compared to II-DSG with almost the same promising results on the control of type 2 diabetes, though in higher BMI patients. The advantages of this technique are preserving the anatomical continuity of the pylorus and duodenum, and maintaining endoscopic access to the biliary tree; it is also simpler to perform as it avoids duodenal dissection, transection and anastomosis and there is no fear of duodenal stump leaks. No intestinal segment is anatomically bypassed. However, the diameter of the gastro-ileostomy tends to enlarge to direct the food mainly to distal ileal segment to create a functional biliopancreatic diversion of proximal intestines and malabsorption. Santoro et al<sup>21</sup> had to revise the diameter of the gastroileostomy after primary surgery. This is an unwanted problem for the true definition of “metabolic surgery” and there must not be any anastomotic and/or volume restrictions to preserve the metabolic outcomes for a surgical technique to be considered as metabolic, in our opinion. The II-DSG is a good example of true metabolic surgery having good outcomes (including our humble experience), whereas the

TB has the risk of unpredictable progress depending on the size of the gastro-ileal anastomosis. If the anastomosis gets narrowed by a stricture, then all of the metabolic benefits may diminish, whereas if it enlarges, the surgery might become severely malabsorptive in time.

Two of our patients who had II-DSG had developed biliary stones that needed surgery because it is impossible to perform endoscopic retrograde cholangiopancreatography (ERCP) when the duodenum is anatomically excluded. As our experience with TB increased and we observed good and satisfactory control of diabetes in a similar patient population as with II-DSG, we started to think of how we could modify and combine the advantages of these two techniques. The solution was very simple: to transect the alimentary limb of the TB, proximal to the distal ileostomy and connect to proximal jejunum in order to divert the bowel contents back to the beginning of the small intestines.

This is a simple modification of the II-DSG and TB. This easily and intentionally, directs undigested food to the interposed distal ileal segment and avoids any concerns regarding size of the gastro-ileostomy. We eliminated the risk of severe malabsorption by connecting the distal end of the interposed ileal segment to the very proximal part of the jejunum so that food has sufficient small bowel length, to maintain almost normal absorption of micronutrients. Our modification preserves the anatomical continuity of pylorus and duodenum as in TB. As we do a liberal anastomosis, and if we assume it to dilate with time, then we suppose that most of the gastric contents will functionally bypass the duodenum and go through the gastro-ileostomy.

This will give the operation a further benefit of “functional duodenal exclusion”, which is expected in TB and anatomically present in II-DSG; also a better and stronger ileal stim-

ulation to evoke more potent incretin effect. However, in TB, this “functional exclusion of proximal intestines” might provoke a risk of “functional malabsorption”, due to massive food transit directly to the very distal intestines. In gastro-ileal interposition, as we divert the ileal contents back to the proximal jejunum, the normal absorption will continue after the metabolic stimulation is done.

The proposed technique is of moderate complexity, in between two well-known metabolic surgeries. The additional anastomosis gives greater security with respect to malabsorption when TB is considered. The gastro-ileostomy is simpler than duodeno-ileostomy, avoiding duodenal preparation and transection, and any possible complications due to this dissection.

This first and early report of our technique lacked the long-term follow-up with respect to glycemic control and weight stabilization with a very limited patient number. These are the limitations of this report. Further long-term follow-up with a greater number of patients will give a better understanding of the efficacy of this new metabolic surgery.

## CONCLUSION

Ileal interposition and gastric bipartition with BMI-adjusted sleeve gastrectomy is a feasible technique which preserves the hind gut stimulation and normal duodenal anatomy for future endoscopy, while eliminating the risk of malabsorption due to enlargement of the gastro-ileal anastomosis. Further studies will give us a better understanding of our primitive assumptions.

## CONFLICTS OF INTEREST

None of the authors have anything to disclose.

## REFERENCES

- Rubino F, Nathan DM, Eckel RH, et al. Metabolic surgery in the treatment algorithm for type 2 diabetes: A joint statement by international diabetes organizations. *Obes Surg*. In press.
- De Paula AL, Macedo ALV, Prudente AS, et al. Laparoscopic sleeve gastrectomy with ileal interposition (“neuroendocrine break”)-pilot study of a new operation. *Surg Obes Relat Dis*. 2006; 2(4): 464-467. doi: [10.1007/s00464-007-9472-9](https://doi.org/10.1007/s00464-007-9472-9)
- De Paula AL, Macedo ALV, Rassi N, et al. Laparoscopic treatment of metabolic syndrome in patients with type 2 diabetes mellitus. *Surg Endosc*. 2008; 22(12): 2670-2678. doi: [10.1007/s00464-008-9808-0](https://doi.org/10.1007/s00464-008-9808-0)
- De Paula AL, Macedo ALV, Rassi N, et al. Laparoscopic treatment of type 2 diabetes mellitus for patients with a body mass index less than 35. *Surg Endosc*. 2008; 22: 706-716. doi: [10.1007/s00464-008-9808-0](https://doi.org/10.1007/s00464-008-9808-0)
- De Paula AL, Macedo ALV, Schraibman V, Mota BR, Vencio S. Hormonal evaluation following laparoscopic treatment of type 2 diabetes mellitus patients with BMI 20-34. *Surg Endosc*. 2009; 23(8): 1724-1732. doi: [10.1007/s00464-008-0168-6](https://doi.org/10.1007/s00464-008-0168-6)
- De Paula AL, Macedo ALV, Mota RB, Schraibman V. Laparoscopic ileal interposition associated to a diverted sleeve gastrectomy is an effective operation for the treatment of type 2 diabetes mellitus patients with BMI 21-29. *Surg Endosc*. 2009; 23(6): 1313-1320. doi: [10.1007/s00464-008-0156-x](https://doi.org/10.1007/s00464-008-0156-x)
- De Paula AL, Stival A, Halpern A, Vencio S. Thirty-day morbidity and mortality of the laparoscopic ileal interposition associated with sleeve gastrectomy for the treatment of type 2 diabetic patients with BMI<35: An analysis of 454 consecutive patients. *World J Surg*. 2011; 35(1): 102-108. doi: [10.1007/s00268-010-0799-3](https://doi.org/10.1007/s00268-010-0799-3)
- De Paula AL, Stival AR, Macedo ALV et al. Prospective randomized controlled trial comparing 2 versions of laparoscopic ileal interposition associated with sleeve gastrectomy for patients with type 2 diabetes with BMI 21-34 kg/m<sup>2</sup>. *Surg Obes Relat Dis*. 2011; 6(3): 296-305. doi: [10.1016/j.soard.2009.10.005](https://doi.org/10.1016/j.soard.2009.10.005)
- De Paula AL, Stival AR, De Paula CCL, Halpern A, Vencio S. Impact on dyslipidemia of the laparoscopic ileal interposition associated to sleeve gastrectomy in type 2 diabetic patients. *J Gastrintest Surg*. 2010; 14(8): 1319-1325. doi: [10.1007/s11605-010-1252-5](https://doi.org/10.1007/s11605-010-1252-5)
- Vencio S, Stival AR, Alfredo H, Depaula CC, DePaula AL. Early mechanisms of glucose improvement following laparoscopic ileal interposition associated with a sleeve gastrectomy evaluated by the euglycemic hyperinsulinemic clamp in type 2 diabetic patients with BMI below by the euglycemic hyperinsulinemic clamp in type 2 diabetic patients with BMI below 35. *Dig Surg*. 2011; 28: 293-298. doi: [10.1159/000330272](https://doi.org/10.1159/000330272)
- De Paula AL, Stival A, Halpern A, et al. Improvement in insulin sensitivity and b-cell function following ileal interposition with sleeve gastrectomy in type 2 diabetic patients: Potential mechanisms. *J Gastrintest Surg*. 2011; 15: 1344-1355. doi: [10.1007/s11605-011-1550-6](https://doi.org/10.1007/s11605-011-1550-6)
- De Paula AL, Stival AR, DePaula CC, Halpern A, Vencio S. Surgical treatment of type 2 diabetes in patients with BMI below 35: Mid-term outcomes of the laparoscopic ileal interposition associated with a sleeve gastrectomy in 202 consecutive cases. *J Gastrintest Surg*. 2012; 16(5): 967-976. doi: [10.1007/s11605-011-1807-0](https://doi.org/10.1007/s11605-011-1807-0)
- Tinocco A, El-Kadre L, Aquiar L, Tinoco R, Savassi-Rocha P. Short-term and mid-term control of type 2 diabetes mellitus by laparoscopic sleeve gastrectomy with ileal interposition. *World J Surg*. 2011; 35(10): 2238-2244. doi: [10.1007/s00268-011-1188-2](https://doi.org/10.1007/s00268-011-1188-2)

14. Kumar KV, Ugale S, Gupta N, et al. Ileal interposition with sleeve gastrectomy for control of type 2 diabetes. *Diabetes Technol Ther.* 2009; 11(12): 785-789. doi: [10.1089/dia.2009.0070](https://doi.org/10.1089/dia.2009.0070)
15. Kota SK, Ugale S, Gupta N, et al. Ileal Interposition with Diverted sleeve gastrectomy for treatment of Type 2 diabetes. *Indian J Endocrinol Metab.* 2012; 16(Suppl 2): S458-S459. doi: [10.1089/dia.2009.0070](https://doi.org/10.1089/dia.2009.0070)
16. Kota SK, Ugale S, Gupta N, Modi KD. Laparoscopic ileal interposition with diverted sleeve gastrectomy for treatment of type 2 diabetes. *Diabetes Metab Syndr.* 2012; 6(3): 125-131. doi: [10.1016/j.dsx.2012.09.014](https://doi.org/10.1016/j.dsx.2012.09.014)
17. Kota SK, Ugale S, Gupta N, et al. Ileal interposition with sleeve gastrectomy for treatment of type 2 diabetes mellitus. *Indian J Endocrinol Metab.* 2012; 16(4): 589-598. doi: [10.4103/2230-8210.98017](https://doi.org/10.4103/2230-8210.98017)
18. Ugale S, Gupta N, Modi KD, et al. Prediction of remission after metabolic surgery using a novel scoring system in type 2 diabetes - a retrospective cohort study. *J Diabetes Metab Disord.* 2014; 13(1): 89. doi: [10.1186/s40200-014-0089-y](https://doi.org/10.1186/s40200-014-0089-y)
19. Celik A, Ugale S, Ofluoglu H, et al. Metabolic outcomes of laparoscopic diverted sleeve gastrectomy with ileal Transposition (DSIT) in obese type 2 diabetic patients. *Obes Surg.* 2015; 25(11): 2018-2022. doi: [10.1007/s11695-015-1671-1](https://doi.org/10.1007/s11695-015-1671-1)
20. Ramakrishnapillai P, Pai M, Shams F, et al. Effectiveness of minimally invasive hybrid surgery for ileal interposition (MIHSII) for the resolution of type 2 diabetes. *Surg Innov.* 2015 pii: 1553350615589523. doi: [10.1177/1553350615589523](https://doi.org/10.1177/1553350615589523)
21. Santoro S, Castro LC, Velhote MC, et al. Sleeve gastrectomy with transit bipartition: A potent intervention for metabolic syndrome and obesity. *Ann Surg.* 2012; 256(1): 104-110. doi: [10.1097/SLA.0b013e31825370c0](https://doi.org/10.1097/SLA.0b013e31825370c0)
22. Mui WL, Lee DW, Lam KK. Laparoscopic sleeve gastrectomy with loop bipartition: A novel metabolic operation in treating obese type II diabetes mellitus. *Int J Surg Case Rep.* 2014; 5(2): 56-58. doi: [10.1016/j.ijscr.2013.12.002](https://doi.org/10.1016/j.ijscr.2013.12.002)