

## Original Research

# Prostaglandin's In Vivo Impact on Conjunctival Goblet Cells

Matthieu Randon, MD, MSc, FEBO<sup>1\*</sup>; Rachid Abbas, MD<sup>2</sup>

<sup>1</sup>Inserm, Centre d'Investigation Clinique 1418 (CIC1418) Epidémiologie Clinique, Paris, France

<sup>2</sup>Département d'Epidémiologie et Recherche Clinique, CIC-EC 1425, Groupe Hospitalier Paris Nord Val de Seine, AP-HP, Hôpital Bichat, Paris France

\*Corresponding author

Matthieu Randon, MD, MSc, FEBO

Head of the Department, Department of Ophthalmology, Centre Hospitalier National d'Ophthalmologie des Quinze-Vingts, DHU View Maintain, INSERM-DHOS CIC 1423, Paris, F-75012, France; Tel. +594 594 39 50 50; E-mail: [matthieu.randon@gmail.com](mailto:matthieu.randon@gmail.com)

### Article information

Accepted: June 30<sup>th</sup>, 2025; Published: July 11<sup>th</sup>, 2025

### Cite this article

Randon M, Abbas R. Prostaglandin's In Vivo Impact on Conjunctival Goblet Cells. *Ophthalmol Open J.* 2025; 8(1): 14-19.

## ABSTRACT

### Introduction

To evaluate the density of conjunctival goblet cells (GCs) from *in vivo* confocal microscopy (IVCM) and impression cytology (IC) and mucin expression in ten glaucomatous patients treated with preservative-free latanoprost (Monoprost®)

### Methods

Ten glaucomatous patients (10 eyes) were enrolled. Conjunctiva was examined clinically and morphologically by IVCM and IC. Both IVCM and IC were performed at baseline, and after the 1st and 4th month of Monoprost® therapy. GC density (GCD) in cells/mm<sup>2</sup> was the main outcome measurement.

### Results

At baseline, mean GCD was 147+/-78 cells/mm<sup>2</sup> for IVCM and 114+/-62 cells/mm<sup>2</sup> for IC GCD. At month one, mean GCD was 149+/-69 and 120+/-56 measured with IVCM and IC, respectively ( $p=0.31$  for IVCM and  $p=0.40$  for IC). At month four, GCD increased to 162+/-81 and 134+/-61 measured with IVCM and IC, respectively ( $p=0.02$  for IVCM and  $p=0.02$  for IC).

### Conclusion

Treatment with preservative-free (PF) latanoprost was associated with an increase in conjunctival GCD in glaucomatous eyes. Further studies are mandatory to verify this finding because its validation may have important consequences in the medical management of glaucoma.

### Keywords

*In vivo* confocal microscopy; Conjunctiva; Goblet cell; Prostaglandin; Cytology impression; Polymerase chain reaction (PCR).

## INTRODUCTION

The conjunctiva is permanently exposed to mechanical, toxic and microbial attacks from the external environment. Its ability to adapt enables it to retain its role as a barrier, immune watchdog and mucin secretion. Histologically, the conjunctiva consists of a non-keratinized stratified surface epithelium resting on a lamina propria separated by a basement membrane.<sup>1</sup> Among the different cell populations, there are squamous epithelial cells and goblet cells (also called mucocytes), which ensure the production of most of the mucins, an essential constituent of the tear film. The conjunctiva fulfills a defense role, not only mechanical, but also immune thanks to the presence of immunocompetent cells, T and B-lymphocytes, and antigen-presenting cells, including Langerhans cells, which are endowed with migratory and recruit-

ment phenomena during an attack or an inflammatory episode. Accessory lacrimal glands constantly produce some of the watery portion of the tear film.<sup>2</sup>

Mucins are high molecular weight glycoproteins and form the glycocalyx, the framework of the mucinous layer. They make this part of the tear film hydrophilic and reduce its surface tension. Without this layer, the film would not adhere and the epithelium would suffer. Mucins 1, 4 and 16 are transmembrane and produced by squamous epithelial cells, while mucins encoded by the *MUC5AC* gene are soluble and secreted by goblet cells. A low-level of mucins is associated with dry eye syndromes which can lead to partial keratinization of the conjunctiva associated with a decrease in the density of mucus cells. The mucocyte density is between 24 and 2226 cells/mm<sup>2</sup>.<sup>3,4</sup> Higher densities are expected in

healthy conjunctiva as well as in areas of conjunctiva not exposed to the atmosphere.<sup>5</sup> No difference in density depending of the age was demonstrated.<sup>6</sup> These cells disappear during ocular dryness or after long-term use of antiglaucoma eye drops containing preservatives<sup>7</sup> and are therefore important to assess clinically. The  $2\alpha$  PGFs (latanoprost, travoprost, etc.) have an action on the prostaglandin F-receptors. The link between the prostaglandin F-receptor and the secretion of mucins is partially explained in particular by work on the respiratory epithelium during pathologies such as cystic fibrosis or chronic obstructive pulmonary disease.<sup>8</sup> A study shows the role of CREB, a transcription factor activated by PGs, in increasing the formation of *MUC5AC*.<sup>9</sup> The abrogation of all downstream signaling activities *via* suppression of each signaling molecule along the pathway indicates that a single pathway from prostaglandin F-receptor to cAMP Response Element-Binding Protein (CREB) is responsible for inducing *MUC5AC* overproduction.<sup>9,10</sup> There could be a link between prostaglandin preservative free treatment and goblet cell density and secretion.

The study of the conjunctiva is essentially based on slit lamp examination with and without vital dyes. The most reliable and widespread method for cytological analysis of the conjunctiva is the conjunctival impression.<sup>3</sup> Nevertheless, *in vivo* confocal microscopy (IVCM), an emerging non-invasive technique, shows an ability to analyze the conjunctiva *in vivo* at a cytological scale and thus to detect mucus cells that synthesize mucins of the *MUC5AC* type, the main mucins tear film.<sup>11</sup> Recently, reverse transcription-polymerase chain reaction (RT-PCR) studies allow the quantification of messenger ribonucleic acids (mRNAs) of mucins and class II molecules of the major histocompatibility complex such as human leucocyte antigen DR (HLA-DR) directly from conjunctival impressions and can thus provide additional functional information.<sup>12</sup>

The objectives of this study are therefore to evaluate the goblet cells density (GCD) obtained by *in vivo* confocal microscopy (IVCM) and conjunctival impression, secondary the clinical ocular surface parameters and finally the gene expression of *MUC1*, *MUC5AC*, *HLA-DR* in glaucomatous patients treated with latanoprost without preservative.

## PATIENTS AND METHODS

The prospective study was conducted at the center of clinical examination at the Quinze-Vingts National Eye center over a period of 4-months in ten patients with open-angle glaucoma: four patients had never had treatment, six others had preserved PG and two had a filtering surgery. Prior to inclusion, an interview detailed the pathologies and treatments of the patients, who all signed a consent form containing the terms of the study. The study was conducted in accordance with the Declaration of Helsinki (1964) at the Center of Clinical Investigations (CIC 503) at the Quinze-Vingts National Eye Center, Paris, France, with the approval of the Institutional Review Board of Saint-Antoine University Hospital (CPP-Ile de France 5, national agreement 10793). If both eyes were eligible for the study, the most symptomatic eye was chosen. Before the beginning of an hypotonic treatment with an analogue of the prostaglandin  $PGF_{2\alpha}$ , latanoprost in single-dose eye drops

at 50  $\mu\text{g/ml}$  eye drops (Monoprost<sup>®</sup>, Théa, France), a complete examination was carried out including a battery of tests: the determination of the index of suffering of the ocular surface (ocular surface disease index, OSDI), Schirmer I test, tear film break-up time (TBUT), Oxford score, measurement of intraocular pressure (IOP) and tear osmolarity, imaging of the conjunctiva by IVCM, and sampling of conjunctival impressions. Confocal microscopy and impression were made on the upper bulbar conjunctiva at 12 o'clock. Follow-up was performed at M1 and M4 after the first visit and assessed the same parameters.

IVCM was performed in all patients with Heidelberg retina Tomograph II<sup>®</sup>, Rostock Cornea Module.<sup>7</sup> After topical anesthesia with a drop of 0.4% oxybuprocaine, the patient's chin and forehead were positioned facing the microscope. After contact of the lens with the cornea, the patient looked down thus exposing the superior bulbar conjunctiva, the digital images were visible in real time on the control screen. The duration of the examination was approximately 10-minutes. The mucocyte density was evaluated after taking photographs using the counting software integrated into the device, by averaging the results of 5 images.

After rinsing the eye with a 0.9% NaCl solution and topical anesthesia with 0.4% oxybuprocaine, two conjunctival impressions (Supor<sup>®</sup>, Gelman, USA) were applied to the upper bulbar conjunctiva and gently removed. A fingerprint was immediately stored at  $-80^{\circ}\text{C}$  to be used for RNA extraction and real-time – quantitative polymerase chain reaction (RT-qPCR) and the other was fixed in a 10% formaldehyde solution and then stained with 1% cresyl violet (Merck, Fontenay-sous-Bois, France). The mucocytes were counted by an operator in a masked manner and their mean density was determined over 5 consecutive fields at x400 magnification.

An evaluation of the transcripts was carried out by qPCR in order to compare the expression levels of the mRNAs from the cells obtained from the conjunctival imprint samples. Total RNAs were extracted from human cells using the RNA XS extraction kit (Macherey Nagel<sup>®</sup>, Düren, Germany) according to the supplier's protocol and resin column methodology. The RNAs obtained were quantified by spectrophotometry using the Nanodrop 100 (Thermo Fisher<sup>®</sup>, MA, USA). Reverse transcription was performed on 500 ng of RNA in 20  $\mu\text{l}$  using the complementary deoxyribonucleic acid (DNA) synthesis kit, ADNc (high-capacity complementary DNA (cDNA) Reverse transcription kit, Life Technologies<sup>®</sup>, CA, USA) in a thermal cycler according to the following protocol: 25  $^{\circ}\text{C}$  for 10 min, 37  $^{\circ}\text{C}$  for 60 min and 85  $^{\circ}\text{C}$  for 5-seconds. The cDNAs resulting from this enzymatic reaction were used for the PCR reaction. A real-time PCR using Taqman technology (Table 1 for the references of the probes of interest *MUC1*, *MUC5AC*, *HLA-DR*, and *GAPDH* gene of a ubiquitous enzyme serving as control) was carried out from 25 ng of cDNA subjected to the following thermal cycles: 95  $^{\circ}\text{C}$ . (10 min) and 40 cycles 95  $^{\circ}\text{C}$ . (15 sec) and 60  $^{\circ}\text{C}$ . (1 min). The reaction was performed on the 7300 real time PCR system instrument (Applied Biosystems<sup>®</sup>, MA, USA). The results and the relative quantification of the transcripts were analyzed using the threshold cycle comparison method with the following equation:  $2^{-(\Delta\Delta\text{CT})}$  or  $\Delta\Delta\text{CT} = \Delta\text{Ct sample} - \Delta\text{Ct calibrator}$ .

The RT-PCR analysis of the conjunctival impressions was carried out on the 10 patients, taking as a calibrator the D0 moment just before the start of treatment with latanoprost single dose.

Taqman® probes	Name	Laboratory
MUC1	Hs00159357_m1	Taqman® life technologies
MUCSAC	Hs00873651_mH	Taqman® life technologies
HLA-DR	Hs 00219575_m1	Taqman® life technologies
GADPH	402869	Taqman® life technologies

All the numerical characteristics of the patients were described according to their mean and their standard deviation. Depending on their distributions, the variables were compared using parametric or non-parametric tests. Correlations of data from repeated measurements were taken into account. All the tests were carried out bilaterally with an  $\alpha$  risk of 5%, using the R 3.1.2 software (R Core Team 2014, Vienna, Austria).<sup>13</sup>

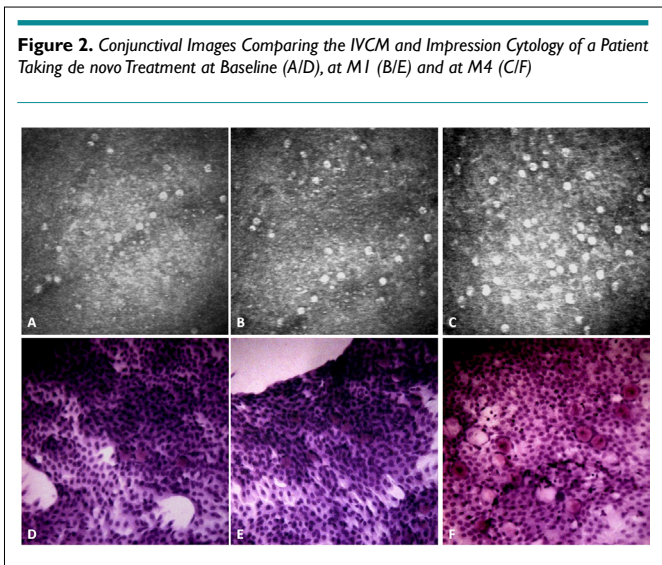
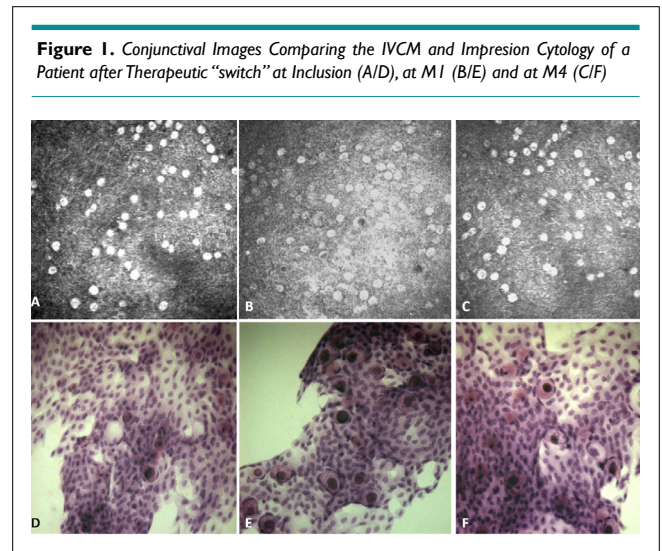
## RESULTS

### Analysis of IVCM Images and Conjunctival Impressions

Image comparisons between IVCM and conjunctival impression collected from the same patients show excellent similarities. Indeed, conjunctival folds (in 12 patients), polynuclears (in 9 patients), mucocytes (in 30 patients), dendritic cells (in 6 patients), pseudocysts (in 6 patients), snake-like chromatin (in 6 patients) were found with both imaging methods.

In IVCM, mucocytes appeared large, oval, and hyper-reflective with a hyporeflective clustered or scattered nucleus in the superficial layers of the epithelium. The mucocyte density

was generally found to be higher in IVCM (Table 2, Figures 1 and 2) ( $153 \pm 96$  cells/mm<sup>2</sup> in IVCM *versus*  $123 \pm 79$  cells/mm<sup>2</sup> ( $p < 0.001$ ) on imprints). The pseudocysts were also better visible in IVCM.



		D0	M1	M4	p*
Mean IOP	P1	14.8+/-2.3	11+/-1.5	10.8+/-1.2	0.16
	P2	14.8+/-4	14.7+/-3	14.3+/-3	0.97
	Global population	14.8+/-3.4	13.2+/-2.7	12.9+/-3	0.51
OSDI	P1	23.9+/-6	20.3+/-7	19.3+/-6	0.66
	P2	32.4+/-23	25+/-14	31+/-19	0.94
	Global population	29.0+/-16	23.3+/-11	26.8+/-15	0.88
TBUT	P1	7+/-1	7.8+/-1	6.8+/-1	0.68
	P2	4.5+/-1	5.7+/-1	6.5+/-1	0.11
	Global population	5.5+/-2	6.5+/-1	6.6+/-1	0.27
Schirmer I	P1	21+/-6	25+/-6	25+/-5	0.52
	P2	13.2+/-4	18.7+/-7	20.7+/-7	0.25
	Global population	16.2+/-5	21.1+/-6	22.2+/-6	0.14
Osmolarity	P1	309+/-11	307+/-12	300+/-8	0.44
	P2	13.2 +/- 4	18.7+/-7	20.7+/-7	0.42
	Global population	308.5+/-11	305.8+/-11	298.1+/-7	0.16

\*Kruskall - Wallis test

### Evolution of the Clinical Parameters and GCD

On inclusion, the patients suffering from open angle glaucoma had an average age of  $73 \pm 10$ -years with an average IOP of  $14.8 \pm 4.1$  mmHg, an OSDI at  $29.0 \pm 21.2$ , a TBUT at  $6 \pm 2$  sec, a Schirmer I test at  $16.2 \pm 7.3$  mm and an osmolarity at  $309 \pm 15$  mOsm/L. There were 5 men for 5 women. Four patients started the latanoprost single dose in first intention (P1) while the six others introduced it following the discontinuation of bimatoprost (Lumigan®, New Delhi, India 0.01%) or travoprost (Travatan®, TX, USA) (P2).

During the follow-up of GAO patients, the mean IOP was  $14.8 \pm 3$  mmHg at D0,  $13.2 \pm 3$  mmHg at M1 and  $12.9 \pm 3$  mmHg at M4 ( $p = 0.51$ ). The subgroup analysis showed a tendency to pressure lowering in the P1 group ( $p = 0.16$ ), while the P2 group did not show any pressure change ( $p = 0.97$ ) (Table 2).

Clinical dry eye parameters such as the ocular surface disease index (OSDI), tearfilm breakup time (TBUT), Schirmer I, and osmolarity did not vary significantly (Table 2).

The GCD was stable between D0 and M1, going from 147+/-78 cells/mm<sup>2</sup> to 149+/-69 cells/mm<sup>2</sup> ( $p=0.31$ ) in IVCM as well as in impression (114+/-62 cells /mm<sup>2</sup> at D0 and 120+/-56 cells/mm<sup>2</sup> at M1,  $p=0.40$ ). The GC density increased at M4 reaching 162+/-81 cells/mm<sup>2</sup> in IVCM ( $p=0.02$ ) and 134+/-61 cells/mm<sup>2</sup> in impression ( $p=0.02$ ) (Table 3).

GC densities	D0	M1	M4	p*
IVCM	147.4+/-79	149+/-69		0.31
			162+/-81	0.02
Impression cytology	114+/-62	120+/-56		0.40
			134+/-61	0.02

\*test of signed ranks

### Molecular Analysis of Conjunctival Epithelial Cell Transcripts

RT-PCR analysis of the conjunctival fingerprints found mean HLA-DR mRNA expression reduced by -5% at M1 ( $p=0.40$ ) and by -14% at M4 ( $p=0.04$ ). The mean expression of MUC1 mRNAs

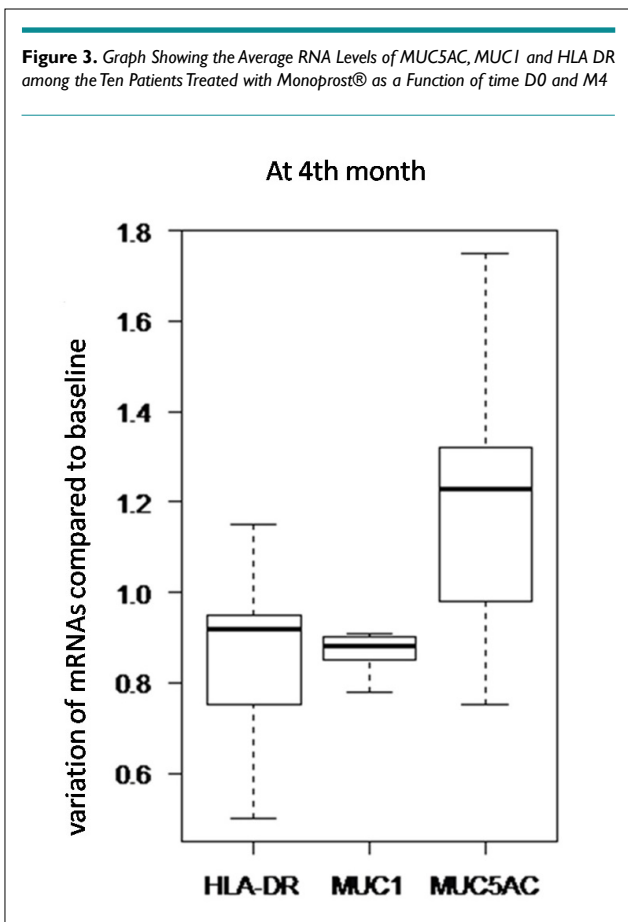
was reduced by -24% at M1 ( $p=0.01$ ) and by -11% at M4 0.89 ( $p=0.06$ ). The mean expression of MUC5AC mRNAs was increased by +23% at M1 ( $p=0.14$ ) and at M4 +23% ( $p=0.05$ ). In total, the expression of HLA DR and MUC1 revealed a decreasing trend over time, and on the other hand, that of MUC5AC revealed an increasing trend (Figure 3).

### DISCUSSION AND CONCLUSION

The IVCM is a valuable tool for examining the conjunctiva of patients and detecting goblet cells, sensitive to attacks on the ocular surface, which are clearly visible during this examination. The IVCM is a painless procedure that allows real-time analysis. It is not traumatic for the conjunctival epithelium and can therefore allow iterative examinations. The combination with the conjunctival impression is not new<sup>12,14</sup> but no study has comprehensively compared these two methods of imaging the conjunctiva. The methods of measuring goblet cells density are still subjects of debate today.<sup>3,4</sup> Confocal microscopy allows analysis of all the epithelial strata, whereas the impression only samples the most superficial part of the conjunctiva.<sup>3</sup> In our study, the cell density was lower in conventional cytology as has already been reported in the literature.<sup>14</sup> Conjunctival microcysts can be counted as goblet cell although no evidence has been provided that the microcyst is an evolved goblet cell. On filtration blebs, the morphology and immunostaining of the mucosae strongly suggested the link between the two structures.<sup>15</sup> The detection of inflammatory cells (polymorphonuclear and dendritic cells) was similar with the two methods. Conserved or non-preserved prostaglandins are used as first-line therapy in the treatment of glaucoma. They are paracrine and autocrine signaling agents that activate many G-protein-coupled 7-transmembrane receptors (GPCRs).<sup>16</sup> Hypotonic therapy currently offered to glaucomatous patients is based on the administration of latanoprost (Xalatan®, PA, USA and Monoprost®, Oakville, Canada), bimatoprost (Lumigan®, New Delhi, USA) or travoprost (Travatan®, TX, USA) which increase the uveoscleral flow of aqueous humor, bimatoprost increasing also trabecular flow.<sup>17</sup>

Numerous observational clinical studies have shown that hypertonic or glaucomatous patients treated complain more often of dry eye symptoms than all patients of the same age. The respective roles of active ingredients, preservatives and excipients are not fully understood. Nevertheless, the toxic and irritating effects of benzalkonium chloride (BAC), which is the most frequently used preservative, seem to be largely involved in the occurrence of these side effects.<sup>18</sup> The instillation of preservatives on the conjunctiva can have several closely related consequences: cytotoxicity, activation of a subclinical immuno-allergic reaction, development of subconjunctival fibrosis, which can lead to progressive conjunctival scarring. The consequences on the lacrimal system (loss of goblet cells, dissolution of the lipid component of the tear film, dry eye) can be serious and lead to dry eye which is itself detrimental for the conjunctiva and the cornea. A decrease in the density of goblet cells has been observed following instillation of eye drops containing a preservative in both humans and animals.<sup>19</sup> The first consequence of this cell loss is a change in the composition and quality of the tear film. Liang et al<sup>19</sup> showed greater ocular surface toxicity of preserved PGs compared to preservative-free tafluprost

**Figure 3.** Graph Showing the Average RNA Levels of MUC5AC, MUC1 and HLA DR among the Ten Patients Treated with Monoprost® as a Function of time D0 and M4



in rabbit conjunctiva. The clinical trial refers to confocal microscopy studies carried out with timolol 0.1% without preservative<sup>20</sup> and on tafluprost<sup>14</sup> which showed an increase in goblet cell density with treatment duration. Our study also finds this increase in IVCN and impression cytology. The interest was to add a study of mucins by PCR from conjunctival imprints, in fact the count of goblet cells alone is not enough because cell density may therefore increase without increased secretion into the tear film.<sup>21</sup> This study also finds an increase in *MUC5AC* transcripts and a decrease in *MUC1* and *HLA-DR* transcripts. Clinical dry eye parameters such as OSDI, TBUT, Schirmer I, and osmolarity showed a slight improvement but not significantly. Our real-life study illustrates that once-daily dosing of preservative free latanoprost might result in GCD increase and could improve the ocular surface of glaucomatous patient. Overall, given the multiple functions of GCs in the ocular surface homeostasis, dedicated strategies should be adopted to preserve this cell population during the course of glaucoma.

#### ACKNOWLEDGMENTS

We thank the CIC of the CHNO of Quinze-Vingts and the Institute of Vision for their logistics and their technical assistance.

#### FUNDING

This study was not funded at all.

#### CONFLICTS OF INTEREST

The authors declare that they have no conflicts of interest.

#### REFERENCES

- Singh R, Joseph A, Umapathy T, Tint NL, Dua HS. Impression cytology of the ocular surface. *Br J Ophthalmol*. 2015; 89: 1655-1659. doi: [10.1136/bjo.2005.073916](https://doi.org/10.1136/bjo.2005.073916)
- Pisella P-J. The cellular players in allergy. *J Fr ophthalmol*. 2007; 30: 283-287. doi: [10.1016/s0181-5512\(07\)89593-3](https://doi.org/10.1016/s0181-5512(07)89593-3)
- Doughty M. Goblet cells of the normal human bulbar conjunctiva and their assessment by impression cytology sampling. *Ocul Surf*. 2012; 10: 149-169. doi: [10.1016/j.jtos.2012.05.001](https://doi.org/10.1016/j.jtos.2012.05.001)
- Yang M, Ngo W, Srinivasan S, Heynen ML, et al. Optimization of goblet cell density quantification methods. *Exp Eye Res*. 2021; 207: 108607. doi: [10.1016/j.exer.2021.108607](https://doi.org/10.1016/j.exer.2021.108607)
- Huang W, Zhang X. Relationship of goblet cell density and glaucoma filtration surgery outcome. *Invest Ophthalmol Vis Sci*. 2016; 57: 5405. doi: [10.1167/iovs.16-20234](https://doi.org/10.1167/iovs.16-20234)
- Hong J, Zhu W, Zhuang H, et al. In vivo confocal microscopy of conjunctival goblet cells in patients with Sjogren's syndrome dry eye. *Br J Ophthalmol*. 2010; 94: 1454-1458. doi: [10.1136/bjo.2009.161059](https://doi.org/10.1136/bjo.2009.161059)
- Hedengran A, Begun X, Müllertz O, et al. Benzalkonium chloride-preserved anti-glaucomatous eye drops and their effect on human conjunctival goblet cells in vitro. *Biomed Hub*. 2021; 6: 69-75. doi: [10.1159/000517845](https://doi.org/10.1159/000517845)
- Samsuzzaman M, Uddin MS, Shah MA, Mathew B. Natural inhibitors on airway mucin: Molecular insight into the therapeutic potential targeting MUC5AC expression and production. *Life Sci*. 2019; 231: 116485. doi: [10.1016/j.lfs.2019.05.041](https://doi.org/10.1016/j.lfs.2019.05.041)
- Chung WC, Ryu SH, Sun H, Zeldin DC, Koo JS. CREB mediates prostaglandin F2 $\alpha$ -induced MUC5AC overexpression. *J Immunol*. 2009; 182: 2349-2356. doi: [10.4049/jimmunol.0713637](https://doi.org/10.4049/jimmunol.0713637)
- Akaba T, Komiya K, Suzuki I, Kozaki Y, Tamaoki J, Rubin BK. Activating prostaglandin E2 receptor subtype EP4 increases secreted mucin from airway goblet cells. *Pulm Pharmacol Ther*. 2018; 48: 117-123. doi: [10.1016/j.pupt.2017.11.001](https://doi.org/10.1016/j.pupt.2017.11.001)
- Srinivasan S, Heynen ML, Martell E, Ritter R, Jones L, Senchyna M. Quantification of MUCIN 1, cell surface associated and MUCIN16, cell surface associated proteins in tears and conjunctival epithelial cells collected from postmenopausal women. *Mol Vis*. 2013; 19: 970-979.
- Labbé A, Gheck L, Iordanidou V, Mehanna C, Brignole-Baudouin F, Baudouin C. An in vivo confocal microscopy and impression cytology evaluation of pterygium activity. *Cornea*. 2010; 29: 392-399. doi: [10.1097/ICO.0b013e3181bd44ce](https://doi.org/10.1097/ICO.0b013e3181bd44ce)
- R Core Team. The R Project for Statistical Computing. 2014. Web site. <http://www.R-project.org/>. Accessed August 11, 2022.
- Mastropasqua L, Agnifili L, Fasanella V, et al. Conjunctival goblet cells density and preservative-free tafluprost therapy for glaucoma: An in vivo confocal microscopy and impression cytology study. *Acta Ophthalmol*. 2013; 91: e397-e405. doi: [10.1111/aos.12131](https://doi.org/10.1111/aos.12131)
- Amar N, Labbé A, Hamard P, Dupas B, Baudouin C. Filtering blebs and aqueous pathway an immunocytological and in vivo confocal microscopy study. *Ophthalmology*. 2008; 115: 1154-1161. doi: [10.1016/j.ophtha.2007.10.024](https://doi.org/10.1016/j.ophtha.2007.10.024)
- Ricciotti E, FitzGerald GA. Prostaglandins and inflammation. *Arterioscler Thromb Vasc Biol*. 2011; 31: 986-1000. doi: [10.1161/ATVBAHA.110.207449](https://doi.org/10.1161/ATVBAHA.110.207449)
- Winkler NS, Fausch MP. Effects of prostaglandin analogs on aqueous humor outflow pathways. *J Ocul Pharmacol Ther*. 2014; 30: 102-109. doi: [10.1089/jop.2013.0179](https://doi.org/10.1089/jop.2013.0179)
- Baudouin C, Labbé A, Liang H, Pauly A, Brignole-Baudouin F. Preservatives in eyedrops: The good, the bad and the ugly. *Program Retin Eye Res*. 2010; 29: 312-34. doi: [10.1016/j.preteyeres.2010.03.001](https://doi.org/10.1016/j.preteyeres.2010.03.001)
- Liang H, Baudouin C, Pauly A, Brignole-Baudouin F. Conjunctival and corneal reactions in rabbits following short- and repeated

exposure to preservative-free tafluprost, commercially available latanoprost and 0.02% benzalkonium chloride. *Br J Ophthalmol.* 2008; 92: 1275-1282. doi: [10.1136/bjo.2008.138768](https://doi.org/10.1136/bjo.2008.138768)

20. Frezzotti P, Fogagnolo P, Haka G, et al. In vivo confocal microscopy of conjunctiva in preservative-free timolol 0.1% gel for-

mulation therapy for glaucoma. *Acta Ophthalmol.* 2014; 92: e133-e140. doi: [10.1111/aos.12261](https://doi.org/10.1111/aos.12261)

21. Corrales RM, de Paiva CS, Li DQ, et al. Entrapment of conjunctival goblet cells by desiccation-induced cornification. *Invest Ophthalmol Vis Sci.* 2011; 52: 3492-3499. doi: [10.1167/iovs.10-5782](https://doi.org/10.1167/iovs.10-5782)