

Case Report

***Corresponding author**
Somuah Tenkorang, MD

Department of Urology
Hassan II Teaching Hospital
Fez, Morocco
E-mail: snrsomuahtenkorang@gmail.com

Volume 1 : Issue 1

Article Ref. #: 1000UAOJ1105

Article History

Received: February 10th, 2017

Accepted: March 20th, 2017

Published: March 21st, 2017

Citation

Tenkorang S, Omana J-P, Bega BS, et al. Renocolic fistula secondary to tuberculosis: A case report. *Urol Androl Open J.* 2017; 1(1): 18-21. doi: [10.17140/UAOJ-1-105](https://doi.org/10.17140/UAOJ-1-105)

Copyright

©2017 Tenkorang S. This is an open access article distributed under the Creative Commons Attribution 4.0 International License (CC BY 4.0), which permits unrestricted use, distribution, and reproduction in any medium, provided the original work is properly cited.

Renocolic Fistula Secondary to Tuberculosis: A Case Report

Somuah Tenkorang, MD^{*}; Jean-Paul Omana, MD; Bienvenu Shamalirwa Bega, MD; Aboubakry Sow, MD; Soufiane Mellas, MD, PhD; Mohammed Fadl Tazi, MD, PhD; Abdelhak Khallouk, MD, PhD; Mohammed Jamal El Fassi, MD, PhD; Jalal Eddine El Ammari, MD, PhD; Moulay Hassan Farih, MD, PhD

Department of Urology, Hassan II Teaching Hospital, Fez, Morocco

ABSTRACT

Background: Renocolic fistula secondary to tuberculosis has become rare in recent years. The availability of tuberculosis medication and the global campaign towards its eradication has immensely contributed to this result. The management of renocolic fistula is essentially surgical comprising of a nephrectomy and a resection of the affected segment of the colon. The underlying cause of the fistula needs to be determined and must be treated appropriately in order to secure the health of the patient.

Case presentation: We present the case of a 75-year-old Moroccan man who was admitted to our department for perirenal abscess associated with a renocolic fistula. He had a 2 month history of left low back pain, intermittent fever and progressive weight loss. The diagnosis of this patient was established with the help of an abdominal computed tomography (CT) scan. A biopsy of a suspected mass on the CT scan was performed during colonoscopy. Histopathological revealed Tuberculosis (TB) as being the underlying cause of this affection.

Conclusion: Renocolic fistula secondary to TB has recently become rare with no specific clinical and radiological features that allow an easy and sure diagnosis. We therefore present this case report with the view of adding a new and recent case to the English literature. In addition, we will discuss how to best establish diagnosis and manage this disease.

KEY WORDS: Renocolic fistulas; Tuberculosis; Computed tomography (CT) scan.

ABBREVIATIONS: CT: Computed Tomography; TB: Tuberculosis; Z: Pyrazinamid; H: Isoniazid; R: Rifampicin; E: Ethambutol.

INTRODUCTION

Although renocolic fistula is a rare pathology, it is the most common of renoalimentary fistulas. This pathology continues to decrease in frequency in the last 50 years due to early and better management of renal diseases. A variety of etiologies of renocolic fistulas with their mechanisms have been reported. Tuberculosis (TB) used to be the most frequent etiology of all renocolic fistulas but this is no more as treatment medications for tuberculosis and the global campaign towards its eradication have been seriously implemented worldwide.

It is already known that tuberculosis can be an underlying cause for renocolic fistulas. However, the English literature has very few reported cases on this subject. We herein report a renocolic fistula in a 75-year-old Moroccan male diagnosed on a computed tomography (CT) scan. A biopsy of a suspected mass on the CT scan was performed during colonoscopy allowing a histopathological confirmation of TB being the underlying cause of this affection.

This presentation adds a recent case of renocolic fistula secondary to TB to the already existing literature whilst we discuss how to best diagnose and manage this affection.

CASE REPORT

A 75-year-old Moroccan man was admitted in our department for a 2 month history of left low back pain associated with an irritable bowel syndrome, fever and weight loss.

This patient had a medical history of hypertension and ischemic cardiomyopathy under diuretics, β -blockers and low dose aspirin. There was no preceding history of pulmonary tuberculosis.

Physical examinations found the patient in an altered general condition. His blood pressure and body temperature was 160/100 mmHg and 38.5 °C respectively. The patient had a left flank pain and tenderness.

Laboratory test of the patient were as follows: Hemoglobin=8 g/L, white blood cells=12000 /mL with an 80% neutrophil pre-dominance, C-reactive protein=266 mg/L, Blood urea nitrogen=0.83 g/L, Creatinine=16 mg/L, Urine culture grew *Escherichia coli* (E.coli).

An abdominal ultrasound showed a left perinephric abscess.

An abdominal CT scan with contrast objectified an enhanced heterogenous solid-cystic mass of the mid and lower portion of the left kidney containing gas bubbles, infiltrating the Psoas major muscle and in direct contact with the left colic flexure suggestive of a renocolic fistula (Figures 1 and 2).

A colonoscopy was performed to search for lesions and to evaluate a suspected mass revealed on the CT scan. The colonoscopy revealed a totally obstructive and ulcerative mass located at 40 cm from the anus. This mass appeared as an extrinsic process that had invaded the colon. Biopsies of the mass were performed.

Histopathological examination of the biopsies revealed granulomas composed of multiple epithelioid cells and Langhans giant cells with central caseous necrosis. Diagnosis of TB was established.

An ultrasound guided percutaneous drainage of the perirenal abscess was performed and the patient was put under anti-TB treatment. The patient was programmed for surgery of the fistula but he passed away a week after his admission from septic shock and heart failure.

DISCUSSION

Renocolic fistulas often involve the ascending and descending segments of the colon. This pathology was first described by Hippocrates in 460 B.C.¹ Though it is an ancient pathology, it remains rare with a few reported cases in the English literature.

There are various etiologies of renocolic fistulas but these can be categorized as traumatic or spontaneous.² The colon is rarely the origin for renocolic fistulas³ Spontaneous renocolic fistulas are the most frequent and it's largely caused by urinary

Figure 1: Axial Abdominal Enhanced CT Scan Showing a Left Perinephric Abscess Associated with a Renocolic Fistula.

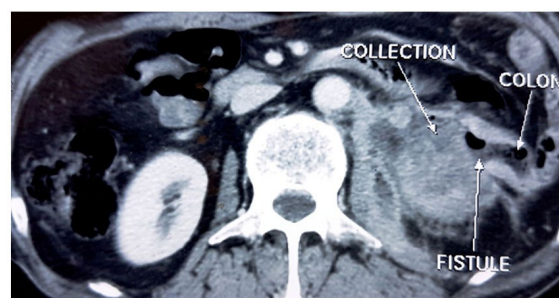
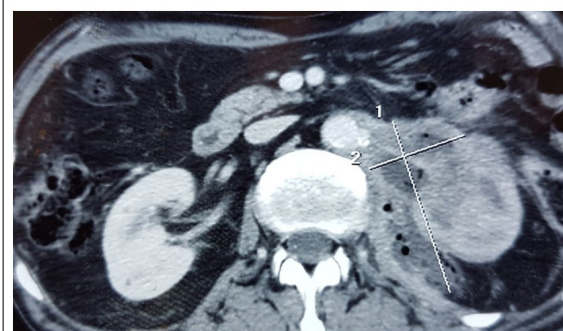


Figure 2: Axial Abdominal Enhanced CT Scan Showing Perinephric Abscess Extending to the Psoas Major Muscle Containing Gas Bubbles.



tract tuberculosis and renal calculus.

Urinary tract TB was previously known to be the most frequent etiology^{4,5} but pyonephrosis secondary to renal calculus has been a predominant etiology in recent years. This can be explained by the availability of medications and efficient management of tuberculosis. Traumatic renocolic fistulas could be iatrogenic or in an event of a severe renal trauma. Iatrogenic causes of renocolic fistulas have reemerged in the last 20 years due to the increased minimal invasive kidney surgeries and percutaneous kidney drainages.⁶

There is no specific clinical sign to diagnose a renocolic fistula. Flank pain and fever are the most frequent symptoms. Pyuria, fecaluria, hematuria and fever can be occasionally present.⁷ Hence, the diagnosis of a renocolic fistula and its underlying cause is largely dependent on radiological imaging. The most useful imaging modalities are CT urography, barium enema, colonoscopy and antegrade or retrograde pyelogram.⁸⁻¹⁰ Each imaging modality has its advantages and disadvantages. The CT scan is by far the best imaging modality to establish the diagnosis of renocolic fistula as in our case. Generally, a couple of these imaging modalities are required to determine the presence of a fistula and its underlying cause.

Surgery is the recommended treatment for renocolic fistula. The affected kidney is often not functioning. Thus, the surgery consists of nephrectomy associated with resection of the involved segment of the colon followed by anastomosis of the healthy colon segments.^{3,10-12} The underlying affection responsible for the fistula must be treated as well. TB was the cause of the renocolic fistula in our case. For this reason, the patient was put on anti-TB medication. The in 2003, Center for Disease Control (CDC) guidelines recommend a nine month regimen which includes Isoniazid, Rifampicin, and Ethambutol, supplemented with Pyrazinamid during the initial 2 months (Z2H9R9E9).¹³⁻¹⁵

CONCLUSION

Although renocolic fistula has been known since ancient times, it is a rare pathology especially in recent times. Tuberculosis was the frequent cause of spontaneous renocolic fistulas. However, there has been a significant decrease in frequency in the last 50 years.

Radiological imaging plays a critical role in the diagnosis of renocolic fistulas as there are no specific symptoms for this pathology. The CT scan is a better diagnostic tool to diagnose renocolic fistulas.

The management of renocolic fistula requires treating the fistula as well as its underlying cause. Hence, in the case of renocolic secondary to tuberculosis, it is recommended to perform surgery consisting of nephrectomy and colon resection-anastomosis. Anti-TB medication must also be administered.

DECLARATIONS

Ethics approval and consent to participate. Not applicable.

ACKNOWLEDGEMENTS

Not applicable.

AVAILABILITY OF DATA AND MATERIALS

No additional file for data and supporting materials.

CONSENT FOR PUBLICATION

Written informed consent was obtained from the patient for publication of this case report and accompanying images.

CONFLICTS OF INTEREST

The authors declare no conflicts of interest.

FUNDING

None.

AUTHORS' CONTRIBUTIONS

TS prepared the manuscript and is the corresponding author OJP, BBS, SA contributed in the review of the articles MS, TMF, EAJE, KA, EFJM, FMH edited the manuscript. All authors read and approved the final manuscript.

REFERENCES

1. Singh G, Gordon-Harris L. Case report: Tubercular renocolic fistula. *Indian J Radiol Imaging*. 2004; 14: 295-297. Web site. <http://ijri.org/article.asp?issn=0971-3026;year=2004;volume=14;issue=3;spage=295;epage=297;aulast=Singh>. Accessed February 9, 2017
2. Patil SB, Patil GS, Kundaragi VS, Biradar AN. A case of xanthogranulomatous pyelonephritis with spontaneous renocolic fistula. *Turk J Urol*. 2013; 39(2): 122-125. doi: [10.5152/tud.2013.026](https://doi.org/10.5152/tud.2013.026)
3. Touiti D, Ameer A, Zrara I, et al. Les fistules pyélocoliques à propos d'une observation. *Ann Urol*. 2001; 35(1): 44-46. doi: [10.1016/S0003-4401\(01\)80012-7](https://doi.org/10.1016/S0003-4401(01)80012-7)
4. Yadav SP, Usha S, Poonam G, Ashwani DK. Reno-colocutaneous fistula: A case report. *Scand J Urol Nephrol*. 1997; 31(4): 411-412. doi: [10.3109/00365599709030632](https://doi.org/10.3109/00365599709030632)
5. Yadav SP, Usha S, Poonam G, Ashwani DK. Reno-colocutaneous fistula: A case report. *Scand J Urol Nephrol*. 1997; 31(4): 411-412. doi: [10.3109/00365599709030632](https://doi.org/10.3109/00365599709030632)

6. Chalise PR, Sharma UK, Gyawali PR, Shrestha GK, Joshi BR, Ghimire RK. Renocolic fistula following percutaneous nephrostomy: A case report. *Nepal Med Coll J.* 2009; 11(2): 143-144.
7. Yu NC, Raman SS, Patel M, Barbaric Z. Fistulas of the genitourinary tract: A radiologic review. *Radiographics.* 2004; 24(5): 1331-1352. doi: [10.1148/rg.245035219](https://doi.org/10.1148/rg.245035219)
8. Mander BJ, Menzies D, Motson RW. Reno-colic fistula. *J R Soc Med.* 1993; 86(10): 601-602.
9. Zafranloo S, Gerard PS, Bryk D. Xanthogranulomatous pyelonephritis in children: Analysis by diagnostic modalities. *Urol Radiol.* 1990; 12(1): 18-21. doi: [10.1007/BF02923958](https://doi.org/10.1007/BF02923958)
10. Parasher R, Sasidharan K. Spontaneous reno-colic fistula. *Indian J Urol.* 2000; 17(1): 64-65. Web site. <http://www.indianjurol.com/article.asp?issn=0970-1591;year=2000;volume=17;issue=1;spage=64;epage=65;aulast=Parasher>. Accessed February 9, 2017.
11. Melvin WS, Burak WE, Flowers JL, Gann DS. Reno-colic fistula following primary repair of the colon: A case report. *J Trauma.* 1993; 35(6): 956. Web site. <http://europepmc.org/abstract/med/8263999>. Accessed February 9, 2017.
12. Hitter E, Ronge R, Walschap G, et al. Asymptomatic nephrocutaneous fistula: A report of 2 cases. *J Urol.* 1988; 139: 1290-1291. Web site. <http://europepmc.org/abstract/med/3373604>. Accessed February 9, 2017.
13. American Thoracic Society C. Infectious diseases society of america treatment of tuberculosis. *MMWR Recomm Rep.* 2003; 52: 1-77.
14. Erratum ATS, CDC. Infectious Diseases Society of America Erratum, Treatment of tuberculosis. *MMWR Recomm Rep.* 2005; 53: 1203.
15. Park SH, Yang SK, Yang DH, et al. Prospective randomized trial of six-month versus nine-month therapy for intestinal tuberculosis. *Antimicrob Agents Chemother.* 2009; 53(10): 4167-4171. doi: [10.1128/AAC.00874-09](https://doi.org/10.1128/AAC.00874-09)