

Case Report

Prostate Cancer Cutaneous Metastasis: A Case Report

Villalba Bachur Roberto F, MD^{1*}; Cora Florencia, MD²; Longo Emilio, MD¹

¹Urology Department, Complejo Médico Churruca Visca, Buenos Aires, Argentina

²Pathology Department, Complejo Médico Churruca Visca, Buenos Aires, Argentina

*Corresponding author

Villalba Bachur Roberto F, MD

Urologist, Urology Department, Complejo Médico Churruca Visca, Buenos Aires, Argentina; Tel. +5493878645281; E-mail: robbybachur@gmail.com

Article Information

Received: June 26th, 2020; Revised: July 14th, 2020; Accepted: July 18th, 2020; Published: July 28th, 2020

Cite this article

Villalba Bachur Roberto F, Florencia C, Emilio L. Prostate cancer cutaneous metastasis: A case report. *Urol Androl Open J.* 2020; 4(2): 27-29.

doi: [10.17140/UAOJ-4-128](https://doi.org/10.17140/UAOJ-4-128)

ABSTRACT

Prostate cancer is the second most common cancer in men. It can be located, present local extension and finally metastasize. Cutaneous metastasis is an infrequent event that is associated with a poor prognosis. We present a clinical case of advanced undifferentiated prostate cancer with cutaneous metastases diagnosed by a punch biopsy and confirmed by immunohistochemistry.

Keywords

Prostate cancer; Cutaneous metastases; Immunohistochemistry.

INTRODUCTION

Prostate cancer (CaPR) is the most common genitourinary cancer in men and the second leading cause of cancer death after lung cancer.¹ Cutaneous metastases (MTSc) of internal cancers are rare, ranging from 0.6% to 10%.^{2,3} The most frequent sites of metastasis (MTS) are bones and lymphatics, being rare in the liver and lung.⁴ A literature review reveals 35 English case reports of MTSc from CaPR.^{5,6} We present a CaPRMTSc case.

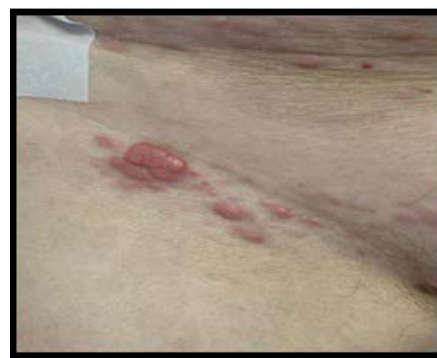CASE REPORT

A 60-year-old man, with medical history of diabetes, ex-smoker was presented and diagnosed with prostate cancer (Gleason Score 5+5) in 2016, with baseline prostate-specific antigen (PSA) 14 ng/ml. Complete androgen blockade was performed with luteinizing-releasing hormone (LHRH) analog and antiandrogen and prostate radiotherapy due to localized oncological pathology through staging studies. At 9-months, he presented a biochemical relapse, the restaging computerized tomography (CT) scan showed multiple intercavo aortic and bilateral iliac lymphadenopathies, and a hypodense image in the sacral bone, which may correspond to secondary disease. The bone scintigraphy showed hyperuptake in the sacral bone. Chemotherapy (CTX) was performed with Docetaxel (18 sessions) with good biochemical and clinical response, with decrease in lymph node images and decrease in the size of the sacral lesion in the first 3-months. Eight-months after the start of CTX, bone progression was evidenced in the ribs,

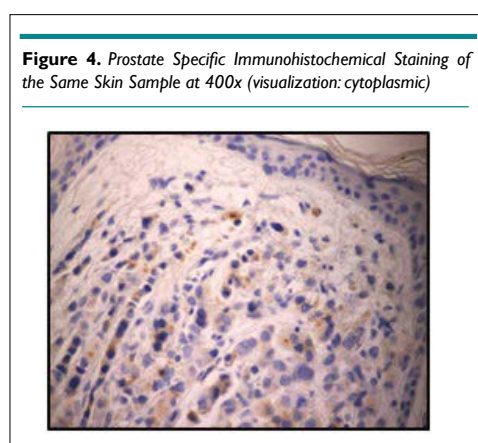
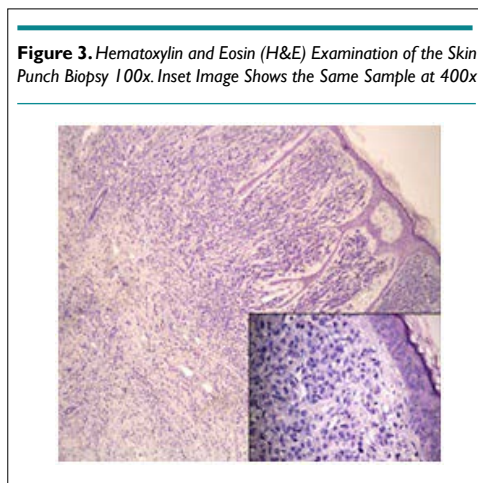
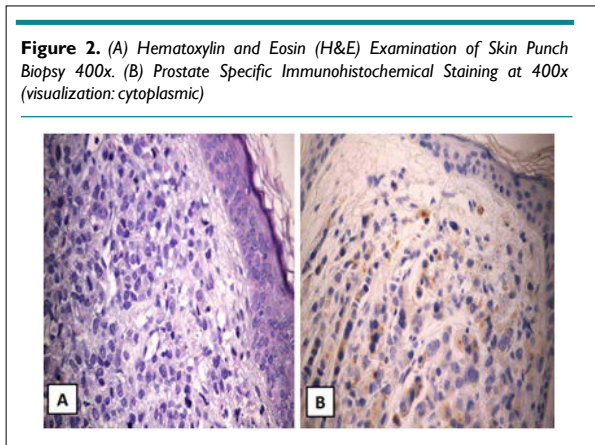
sternum and cranial calotte, as well as liver and lung metastases with a rise in PSA to 20 ng/ml. It was decided to start enzalutamide therapy continuing with androgen blockade.

Four-months later, the patient was consulted for 2-month evolution nodular, violaceous, raised, non-pruritic formations, on an erythematous base in the right inguinal region and suprapubic (Figure 1). Lesions were evaluated by dermatology department and punch biopsy was decided. Histopathological results revealed epidermis with atrophy, dermis with infiltration by medium-sized cells, with a high nucleo-cytoplasmic ratio, anisocariosis and few cytoplasm with imprecise limits. Immunohistochemistry was per-

Figure 1. Nodular Formations on an Erythematous Base in the Right Inguinal Region and Suprapubic



formed and showed positive staining for PSA, concluding in lesions compatible with metastasis of acinar carcinoma of the prostate (Figures 2, 3 and 4).



Chemotherapy was started, receiving 2 cycles of cabazitaxel without evidence of clinical response. The patient died 4-months after detection of the MTS.

DISCUSSION AND CONCLUSION

CaPRMTSc is an infrequent entity and less than 100 cases were

reported in the literature until 2016. An incidence of 0.09% of MTS in CaPR skin is recorded, which can increase taking into account the refractoriness and final stage of pathology⁷⁻¹⁰

In recent years, case reports of skin involvement has increased. This could be due to both the relative increase in the elderly, the world's population and the development of new treatments for CaPR that extend the survival rate.⁸

CaPR can metastasize through four different mechanisms: local spread of the disease, implantation through a surgical scar, lymphatic spread, and hematogenous spread.⁹

Cutaneous involvement has a poor prognosis as in other malignancies. It is considered an advanced disease marker with an average survival of 6-months.^{4,8,11,12} Therefore, a skin extension should be suspected when appearing new skin lesions in a patient with an aggressive oncological diagnosis.

When skin involvement appears, they are usually nodular lesions that involve the supra pubic region, anterior aspect of the thigh, inguinal region, and few reports of facial, neck, chest and umbilical region involvement.^{8,10,13,14}

In the literature review, Pistone et al¹⁵ shows a patient with a history of prostate cancer who develops two tumors in chest and neck, after eight years of the diagnosis of the neoplasm, which were compatible with skin metastases. On the other hand, Rodriguez-Lojo et al¹⁴ presents two cases of cutaneous metastases of the prostate, of which only one of them appeared in the skin of the chest as subcutaneous infiltration after eleven-years. In both cases, the presentation time of the metastasis was different from ours, which was 2-years possibly due to the tumor undifferentiation, however, according to our case, the patients died within a few months of the diagnosis of skin metastasis.

Unlike our report, Champoñan-Relaiza et al¹⁶ presented a case of skin lesions in the chest and neck without a previous diagnosis of prostate cancer. When performing a skin biopsy, positive cell staining was shown for specific prostate antigen.

In our case, it is an aggressive, undifferentiated CaPR, which was evidenced by the Gleason Score (5+5), with early refractoriness to the established treatments.

Prostate specific antigen and prostate specific acid phosphatase (PSAP) are sensitive and specific immunoreactives for CaPR, however in certain cases they can be negative due to the great undifferentiation that the tumor could present.^{9,13,17} Thus, immunohistochemistry become essential for diagnosis in these cases.

To conclude, urologists and dermatologists should bear consider a differential diagnosis when examining nodular lesions or skin rash in oncological patients, knowing that it may represent as the first manifestation of an oncological disease and are largely associated to a bleak forecast.

CONSENT

The authors have received written informed consent from the patient.

CONFLICTS OF INTEREST

The authors declare that they have no conflicts of interest.

REFERENCES

- Centers for Disease Control and Prevention (CDC). United States Cancer Statistics: 1999-2010 Incidence and Mortality Web-based Report. U.S. Cancer Statistics Working Group. Web site. <http://apps.nccd.cdc.gov/uscs/>. Accessed June 23, 2020.
- Lookingbill DP, Spangler N, Sexton FM. Skin involvement as the presenting sign of internal carcinoma. A retrospective study of 7316 cancer patients. *J Am Acad Dermatol*. 1990; 22: 19-26. doi: [10.1016/0190-9622\(90\)70002-y](https://doi.org/10.1016/0190-9622(90)70002-y)
- Lookingbill DP, Spangler N, Helm KF. Cutaneous metastases in patients with metastatic carcinoma: A retrospective study of 4020 patients. *J Am Acad Dermatol*. 1993; 29(2 Pt 1): 228-236. doi: [10.1016/0190-9622\(93\)70173-q](https://doi.org/10.1016/0190-9622(93)70173-q)
- Wang SQ, Mecca PS, Myskowski PL, Slovin SF. Scrotal and penile papules and plaques as the initial manifestation of a cutaneous metastasis of adenocarcinoma of the prostate: Case report and review of the literature. *J Cutan Patol*. 2008; 35: 681-684. doi: [10.1111/j.1600-0560.2007.00873.x](https://doi.org/10.1111/j.1600-0560.2007.00873.x)
- Keen MA, Hassan I. Cutaneous metastasis of an advanced prostate cancer. *Indian J Dermatol Venereol Leprol*. 2013; 79: 828-829. doi: [10.4103/0378-6323.120745](https://doi.org/10.4103/0378-6323.120745)
- Kikuchi Y, Matsuyama A, Nomura K. Zosteriform metastatic skin cancer: Report of three cases and review of the literature. *Dermatology*. 2001; 202: 336-338. doi: [10.1159/000051670](https://doi.org/10.1159/000051670)
- Brown GT, Patel V, Lee CC. Cutaneous metastasis of prostate cancer: a case report and review of the literature with bioinformatics analysis of multiple healthcare delivery networks. *J Cutan Patol*. 2014; 41: 524-528. doi: [10.1111/cup.12296](https://doi.org/10.1111/cup.12296)
- Fukuda H, Saito R. A case of Sister Mary Joseph's nodule from prostatic cancer. *J Dermatol*. 2006; 33: 46-51. doi: [10.1111/j.1346-8138.2006.00009.x](https://doi.org/10.1111/j.1346-8138.2006.00009.x)
- Arita K, Kawashima T, Shimizu H. Cutaneous metastasis of prostate carcinoma. *Clin Exp Dermatol*. 2002; 27: 64-65. doi: [10.1046/j.0307-6938.2001.00966.x](https://doi.org/10.1046/j.0307-6938.2001.00966.x)
- Boswell JS, Davis MD. Violaceous plaque on the forehead clinically resembling angiosarcoma: Cutaneous metastasis in a patient with prostatic adenocarcinoma. *J Am Acad Dermatol*. 2005; 53: 744-745. doi: [10.1016/j.jaad.2005.04.047](https://doi.org/10.1016/j.jaad.2005.04.047)
- Sina B, Deng A. Umbilical metastasis from prostate carcinoma (Sister Mary Joseph's nodule): A case report and review of literature. *J Cutan Patol*. 2007; 34: 581-583. doi: [10.1111/j.1600-0560.2006.00658.x](https://doi.org/10.1111/j.1600-0560.2006.00658.x)
- Rattanasirivilai A, Kurban A, Lenzy YM, Yaar R. Cutaneous metastasis of prostatic adenocarcinoma: A cautionary tale. *J Cutan Patol*. 2011; 38: 521-524. doi: [10.1111/j.1600-0560.2011.01677.x](https://doi.org/10.1111/j.1600-0560.2011.01677.x)
- Telis L, Wolf V, Yaskiv O, Pearson BJ, Katsigeorgis M, Jazayeri SB, et al. Skin metastasis, an uncommon course of prostate carcinoma: A report of two cases. *Malays J Pathol*. 2016; 38(2): 165-168.
- Rodríguez-Lojo R, Castiñeiras I, Rey-Sanjurjo JL, Fernández-Díaz ML. Distant cutaneous metastases of prostate cancer: A report of 2 cases. *Actas Dermosifiliogr*. 2016; 107(7): e52-e56. doi: [10.1016/j.ad.2015.09.021](https://doi.org/10.1016/j.ad.2015.09.021)
- Pistone G, Pistone A, Aricò M, Bongiorno MR. Multiple cutaneous metastases in the chest from prostatic carcinoma. *Case Report Dermatol*. 2013; 5(1): 27-30. doi: [10.1159/000346801](https://doi.org/10.1159/000346801)
- Chapoñan-Relaiza M, Deza HM, García J, Delgado V. Cutaneous metastasis of prostate adenocarcinoma: a case report. *Rev Peru Med Exp Salud Publica*. 2019; 36(3): 525-529. doi: [10.17843/rpmesp.2019.363.3809](https://doi.org/10.17843/rpmesp.2019.363.3809)
- Kataria PS, Kendre PP, Patel AA, Dalsaniya S. Cutaneous metastasis leading to the diagnosis of carcinoma of the prostate: A rare case report and review of literature. *Indian J Dermatol*. 2018; 63(2): 182-185. doi: [10.4103/ij.d.IJD_7_17](https://doi.org/10.4103/ij.d.IJD_7_17)