

Case Report

A Hemodialysis Patient with Multiple Tumoral Calcinosis

Mrabat Samia, MD^{1*}; Ennaciri Soufiane, MD²; Abdelhafid El Maarfi, MD³; Baybay Hanane, PhD¹; Bennani Mounia, MD¹; Zakia Douhi, MD¹; Elloudi Sara, PhD¹; Mernissi Fatima Zahra, PhD¹; Ahsaini Mustapha, PhD²; Mellas Soufiane, PhD²; El Ammari Jaleddine, PhD²; Tazi Med Fadl, PhD²; Farih Moulay Hassan, PhD²; Abdelmajid El Mrini, PhD³

¹Department of Dermatology and Venerology, Hassan II University Hospital, Fes, Morocco

²Department of Urology, Hassan II University Hospital, Fes, Morocco

³Department of Traumatology, Hassan II University Hospital, Fes, Morocco

*Corresponding author

Mrabat Samia, MD

Department of Dermatology and Venerology, Hassan II University Hospital, Fes, Morocco; E-mail: samiarabat91@gmail.com

Article Information

Accepted: January 31st, 2025; Published: February 6th, 2025

Cite this article

Samia M, Soufiane E, Maarfi AE, et al. A hemodialysis patient with multiple tumoral calcinosis. *Urol Androl Open J.* 2025; 9(1): 1-3.

ABSTRACT

Pseudotumoral calcinosis is a rare condition characterized by periarticular calcium deposition. It preferentially affects large joints such as the hip, shoulder and elbow. It is a severe complication of chronic renal failure. We report a case of secondary pseudotumoral calcinosis in a chronic hemodialysis patient.

Keywords

Tumoral calcinosis; Chronic renal failure; Hemodialysis.

INTRODUCTION

Tumoral calcinosis is a rare benign condition characterized by deposition of calcium salt in different peri-articular soft tissue regions, mainly in the juxta-articular areas.¹ It affects mostly African people, especially in the second decade, but it can affect any age.²⁻⁴ The term tumoral calcinosis was first used by Inclan et al in 1943,⁵ however, the condition itself was described before in 1899 by Duret.⁶

CASE REPORT

A 58-year-old patient, on chronic hemodialysis, presented with a six-month history of three slightly painful swellings gradually increasing in size located in the shoulder and both the hips. Clinical examination found a mass on the right shoulder (Figure 1) from which there was a flow of thick yellowish-white liquid. It also revealed the presence of three large lumps. The largest one on the right hip (measuring 20 cm in length) extended to the lower third of the thigh and was of firm consistency (Figure 2).

X-ray of the shoulder showed a periarticular calcified mass of multi-locular appearance capping the humeral head without lysing the bone. Magnetic resonance imaging (MRI) revealed the presence of several soft tissue masses on both shoulders and both hips, giving a bees nest-like appearance (Figure 3). Their matrix

was osteoid and they were seen to infiltrate adjacent muscle whilst sparing bones and joints. The radiological findings were very suggestive of pseudotumoral calcinosis.

Laboratory tests showed a high serum calcium concentration, a normal phosphate concentration and elevated serum parathyroid hormone concentration. After the diagnosis of hypercalcemia with tumoral calcification secondary to chronic renal failure was made, the patient was placed on a low calcium diet and intensive hemodialysis sessions. However, the calcifications did not improve and the patient refused surgery.

Figure 1. Mass of the Right Shoulder Showing Discharge of Thick Yellowish-White Liquid

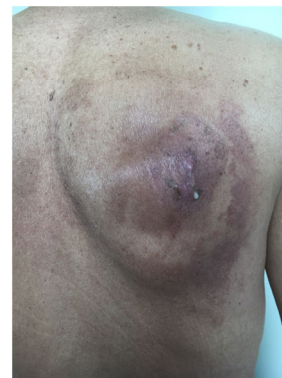


Figure 2. Voluminous Mass, Measuring 20 cm on the Right Tigh and Extending above the Knee, of Firm Consistency

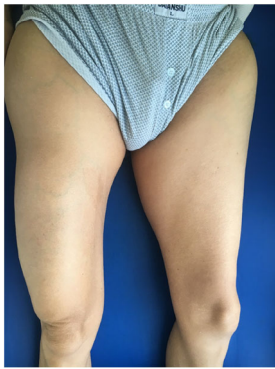
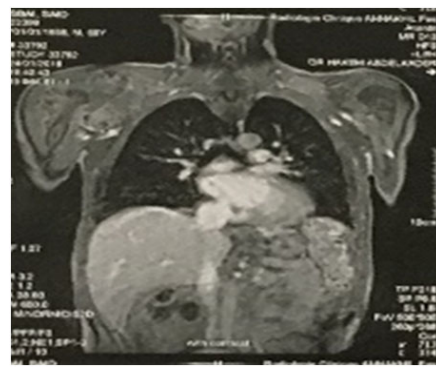
Figure 3. MRI Showing Soft Tissue Masses on both Shoulders, Giving a Beesnest-like Appearance



DISCUSSION

There are three clinical forms of pseudotumoral calcinosis.

1. Tumoral calcinosis secondary to chronic renal failure due to a disorder in calcium and/or phosphate metabolism.
2. A familial form with an autosomal recessive transmission, which may be hyperphosphataemic or normo-phosphataemic.
3. A form with a sporadic pattern which generally has normal calcium and phosphate levels.^{7,8}

Although, lesions usually appear around large joints, cases involving cervical and lumbar spine, the supraclavicular area and toes have also been reported.⁹ Large lesions can cause pain, functional impairment and nerve compression.¹⁰ Local complications include skin ulceration with a chalky milk-like discharge and chronic infection with resulting secondary amyloidosis. Typically, there is no bone involvement, although periosteal reaction or erosion due to pressure may be found. Tumoral calcinosis has a typical appearance on radiographs: amorphous, cystic, and multilobulated calcification located in periarticular soft tissues. On MRI, tumoral calcinosis is seen as a well-circumscribed multicystic mass.¹¹ The differential diagnosis of tumoral calcinosis includes multiple causes of metabolic and dystrophic calcification including:

- Connective tissue diseases (systemic sclerosis, mixed connective tissue disease, dermatomyositis, systemic lupus erythematosus)
- Neoplastic diseases (synovial sarcoma, osteosarcoma, chondrosarcoma)
- Degenerative diseases (calcific tendonitis, calcific bursitis).¹²

Surgery is the gold standard treatment. Indications for surgery are pain, recurrent infection, ulceration and functional impairment.¹³

CONCLUSION

The diagnosis of tumoral calcinosis is based on clinical context, biology and radiology. Management of tumoral calcinosis is difficult. Surgical excision is the best treatment option, but the deposits can recur after surgery. Other options include increasing dialysis dosage phosphate deprivation and vitamin-D analogs but

the response may be limited. Renal transplantational ways leads to resolution. However, more studies are necessary in order to clarify the most effective treatment modality for each type of tumoral calcinosis.¹⁴

CONSENT

The authors have received written informed consent from the patient.

CONFLICTS OF INTEREST

The authors declare that they have no conflicts of interest.

REFERENCES

1. Shaukat Y.M, Malik EF, Al Rashid M, Cannon SR. Large tumoral calcinosis in the gluteal region. *Ortop Traumatol Rehabil.* 2013; 15(5): 495-499. doi: [10.5604/15093492.1084363](https://doi.org/10.5604/15093492.1084363)
2. Viegas SF, Evans EB, Calhoun J, Goodwiller SE. Tumoral calcinosis : A case report and review of the literature. *J Hand Surg Am.* 1985; 10(5): 744-748. doi: [10.1016/s0363-5023\(85\)80225-2](https://doi.org/10.1016/s0363-5023(85)80225-2)
3. Harkess JW, Peters HJ. Tumoral calcinosis: A report of six cases. *J Bone Joint Surg Am.* 1967; 49: 721-731.
4. Palmer PE. Tumoral calcinosis. *Br J Radiol.* 1966; 39: 518-525. doi: [10.1259/0007-1285-39-463-518](https://doi.org/10.1259/0007-1285-39-463-518)
5. Inclan A, Leon P, Camejo MG. Tumoral calcinosis. *JAMA.* 1943; 121: 490-495. doi: [10.1001/jama.1943.02840070018005](https://doi.org/10.1001/jama.1943.02840070018005)
6. Duret MH. Tumeurs multiples et singulaires des bourses séreuses. *Bull Mem Soc Anat Paris.* 1899; 74: 725-731.
7. McGregor DH, Mowry M, Cherian R, McAnaw M, Poole E. Non familial tumoral calcinosis associated with chronic renal failure and secondary hyperparathyroidism: Report of two cases with clinicopathological, immunohistochemical, and electron microscopic findings. *Hum Pathol.* 1995; 26: 607-613. doi: [10.1016/0046-8177\(95\)90164-7](https://doi.org/10.1016/0046-8177(95)90164-7)

8. Polykandriotis EP, BeutelFK, Horch RE, Grunert J. A case of familial tumoral calcinosis in a neonate and review of the literature. *Arch Orthop Trauma Surg.* 2004; 124: 563-567. doi: [10.1007/s00402-004-0715-0](https://doi.org/10.1007/s00402-004-0715-0)
9. Hammoud S, McCarthy EF, Weber K. Tumoral calcinosis in infants: a report of three cases and review of the literature. *Clin Orthop Realt Res.* 2005; 436: 261-264.
10. Riemenschneider PA, Ecker A. Sciatica caused by tumoral calcinosis: A case report. *J Neurosurg.* 1952; 9: 304-307. doi: [10.3171/jns.1952.9.3.0304](https://doi.org/10.3171/jns.1952.9.3.0304)
11. Martinez S, Vogler J, Harrelson J, Lyles K. Imaging of tumoral calcinosis: New observations. *Radiology.* 1990; 174: 215-222. doi: [10.1148/radiology.174.1.2294551](https://doi.org/10.1148/radiology.174.1.2294551)
12. Olsen KM, Chew FS. Tumoral calcinosis: Pearls, polemics, and alternative possibilities. *Radiographics.* 2006; 26: 871-885. doi: [10.1148/rg.263055099](https://doi.org/10.1148/rg.263055099)
13. Majeed SA. Chronic recurrent multifocal osteomyelitis associated with tumoral calcinosis. *J Bone Joint Surg Br.* 1994; 76: 325-327.
14. Del Bravo V, Liuzza F, Perisano C, et al. Gluteal tumoral calcinosis. *Hip Int.* 2012; 22: 585-591. doi: [10.5301/HIP.2012.10347](https://doi.org/10.5301/HIP.2012.10347)