

## Case Report

# Report on a Case of Bilateral Pubo-Penile Ectopic Testis

Saint C. N. Kouka, MD<sup>1\*</sup>; Yoro Diallo, MD<sup>1</sup>; Mahamat A. M. Amine, MD<sup>2</sup>; Mohamed Jalloh, MD<sup>3</sup>; Daniel Yonga, MD<sup>4</sup>; Cheikh Diop, MD<sup>1</sup>; Ramatoulaye Ly, MD<sup>1</sup>; Sylla Cheikhna, MD<sup>1</sup>

<sup>1</sup>Departement of Urology, Université de Thiès, Thiès, Senegal

<sup>2</sup>Departement of Urology, University of N'Djamena, N'Djamena, Chad

<sup>3</sup>Departement of Urology, Université Cheikh Anta Diop (UCAD), Dakar, Senegal

<sup>4</sup>Service of Surgery, Hospital Grand Mbour, Mbour, Senegal

\*Corresponding author

Saint C. N. Kouka, MD

Assistant Professor, Departement of Urology, Université de Thiès, Thiès, Senegal; Tel. 221776526437; E-mail: [saintkouka@yahoo.fr](mailto:saintkouka@yahoo.fr)

### Article Information

Accepted: June 10<sup>th</sup>, 2025; Published: July 1<sup>st</sup>, 2025

### Cite this article

Kouka SC, Diallo Y, Mahamat MA, et al. Report on a case of bilateral pubo-penile ectopic testis. *Urol Androl Open J.* 2025; 9(1): 8-9.

### ABSTRACT

Pubo-penile ectopic testis is a rare congenital anomaly whose etiopathogenesis is still poorly understood. We report one case of bilateral pubo-penile ectopic testis in a two-year-old child. The diagnosis was made on physical examination alone. Orchidopexy in the dartos muscle was easy to perform.

#### Keywords

Pubo-Penile ectopic testis; Orchidopexy.

### INTRODUCTION

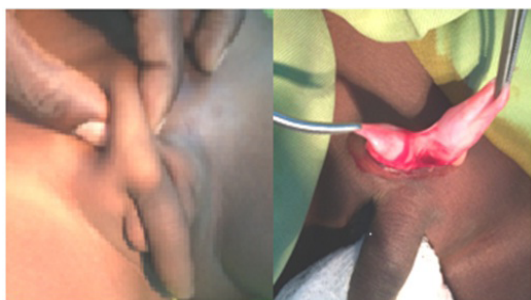
Testicular ectopia (ectopic testis) is an aberrant migration of testis and so the testis is not found in the normal route of testicular descent into the scrotum. The testis therefore deviates from its usual path of descent.<sup>1</sup> The diagnosis is essentially clinical and the treatment is orchidopexy in Dartos.

### CASE REPORT

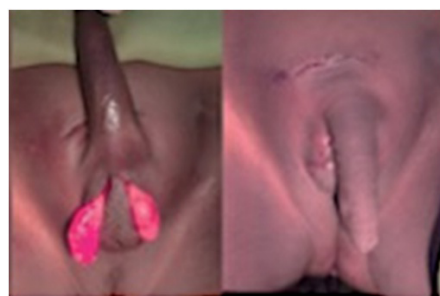
A two-year-old boy was referred by his parents to the clinic for the management of bilateral absence of testis in the scrotum. Physical examination revealed a bilateral emptiness of the scrotum

and a palpable mass corresponding to the ectopic testes in the pubo-penile region bilaterally (Figure 1). His general examination was normal. No additional diagnostic investigations were performed to confirm the diagnosis. At operation, the testes were approached by a supra-pubic skin-crease incision. During the surgical exploration, testes were found to be attached to the spermatic cord and otherwise normal (Figure 2). Bilateral orchidopexy with the testes transposed to bilateral pouches in the dartos muscle of the scrotum was performed without difficulty (Figure 2). Post-operative recovery was uneventful. The child was doing well on subsequent follow-up.

**Figure 1.** Physical Examination and Surgical Exploration Revealed Emptiness of Scrotal Content and a Palpable Two Ovoid Swellings Localized to the Pubic Region



**Figure 2.** Orchidopexy in Dartos



### DISCUSSION

An ectopic testis (testicular ectopia) is a rare congenital anomaly with an incidence of 1.5%.<sup>2-6</sup> Several clinical forms have been

reported based on anatomical position<sup>2,7,8</sup>:

- Position of the ectopic testis is at the superficial inguinal pouch
- Pubic type (position of the ectopic testis may be found at the root of the penis)
- Penile type (at penis)
- Perineal type (position of the ectopic testis may be found at the perineum)
- Femoral type (position of the ectopic testis is at the upper and at the medial part of the femoral triangle).

The etiopathogenesis of testicular ectopia is controversial.<sup>1,8</sup> The gubernaculum testis and testosterone are reported to be involved in the normal positioning of the testis.<sup>3,4</sup> According to Hutson et al,<sup>5</sup> gubernaculum testis weakness and an anomaly of the genito-femoral nerve could be the cause of aberrant migration and the occurrence of certain testicular ectopic positions. The genito-femoral nerve has a significant role as a tractor and guide of the gubernaculum.<sup>9</sup> For some authors. Kaufma<sup>1,6</sup> The Pubo-penile ectopic testis may be due to a mechanical obstruction at the level of the scrotum leading deviation of the testis towards a zone of less resistance. The case we report could possibly be due to this.

The diagnosis of pubic testicular ectopia is essentially based on physical examination and should be done at birth. For some authors, an ultrasound scan can be performed to confirm the diagnosis and aid localization. Doppler-associated ultrasound can demonstrate testicular vascularization.<sup>4</sup> In some cases, as recommended by Pugach et al,<sup>10</sup> pre-operative laparoscopies may be useful for diagnosis. Treatment is surgical<sup>10</sup> taking great care to avoid the risk of microtrauma and torsion so as to reduce the risk of ischemia and later fertility disorders. Some authors recommend performing orchidopexy as soon as possible before the age of one year.<sup>10-12</sup> However, delayed management is often reported.<sup>1,6,7,10</sup>

The long-term prognosis for pubo-penile ectopic testis is excellent because of the discretion of histological lesions. Hutcheson, on the other hand, in a comparative study, did not find a significant difference between the histological lesions observed in ectopic testis and cryptorchid testes.<sup>9</sup>

## CONCLUSION

Pubo-penile ectopic testis is rare. The diagnosis is based on physical examination. Orchidopexy should be performed at the earliest possible opportunity.

## CONSENT

The authors have received written informed consent from the patient.

## CONFLICTS OF INTEREST

The authors declare that they have no conflicts of interest.

## REFERENCES

1. Kaufman DR. Ectopic testis pubopenile type. *Am J Surg.* 1943; 62(2): 272-276. doi: [10.1016/S0002-9610\(43\)90261-2](https://doi.org/10.1016/S0002-9610(43)90261-2)
2. Gaurav G, Prateek S, Sangeeta G, Sonam A, Prabhjyot BS, Sameer S. Pubo-penile ectopic testis: A rare entity. *Anatomy Physiol Biochem Int J.* 2017; 2(2): 31-33. doi: [10.19080/APBIJ.2017.02.555582](https://doi.org/10.19080/APBIJ.2017.02.555582)
3. Mathers MJ, Sperling H, Rübber H, Roth S. The undescended testis: Diagnosis, treatment and long-term consequences. *Dtsch Arztebl Int.* 2009; 106: 527-532. doi: [10.3238/arztebl.2009.0527](https://doi.org/10.3238/arztebl.2009.0527)
4. Redman JF, Golladay ES. Penopubic and penile testicular ectopia. *South Med J.* 1991; 84: 535-536. doi: [10.1097/00007611-199104000-00037](https://doi.org/10.1097/00007611-199104000-00037)
5. Hutson JM, Terada M, Zhou B, Williams MPL. Normal testicular descent and the aetiology of cryptorchidism. *Adv Anat Embryol Cell Biol.* 1995; 132: 1-56. doi: [10.1007/978-3-642-61026-4](https://doi.org/10.1007/978-3-642-61026-4)
6. Middleton GW, Beamon CR, Gillenwater JY. Two rare cases of ectopic testis. *J Urol.* 1976; 115: 455-458. doi: [10.1016/s0022-5347\(17\)59241-1](https://doi.org/10.1016/s0022-5347(17)59241-1)
7. Diabaté I, Bray K, Sow I. *L'ectopie testiculaire pénienne: à propos d'un cas* [In: French]. *Andrologie.* 2011; 21: 199-201. doi: [10.1007/s12610-011-0136-1](https://doi.org/10.1007/s12610-011-0136-1)
8. Sylla C, Ndoye A, Gueye SM, Mensah A. Penile ectopic testis. *Br J Urol.* 1996; 77: 762.
9. Hutcheson JC, Snyder HM, Zuniga ZV, et al. Ectopic and undescended testis: 2 variants of a single congenital anomaly? *J Urol.* 2000; 163: 961-963. doi: [10.1016/s0022-5347\(05\)67864-0](https://doi.org/10.1016/s0022-5347(05)67864-0)
10. Pugach JL, Steinhardt GF. Evaluation and management of ectopic penile testis. *Urology.* 2002; 59: 137. doi: [10.1016/s0090-4295\(01\)01473-x](https://doi.org/10.1016/s0090-4295(01)01473-x)
11. Merrot T. Prise en charge des testicules non descendus. *Prog Urol.* 2009; 19: 265-268. doi: [10.1016/j.purol.2008.10.028](https://doi.org/10.1016/j.purol.2008.10.028)
12. Zemmouri AA, Elbaghouli M, Zemmouri MM, Rabii Q, Aboutaieb R, Meziane F. *Seminome spermatocytaire sur testicule ectopique (à propos d'une nouvelle observation et revue de la littérature)* [In: French]. *J Maroc Urol.* 2009; 14: 28-31.